

Pulmonary *Aspergillus* and *Mucor* Co-Infection

A report of two cases

Ravindra Chari M., *Manju Rajaram, Madhusmita M., Pampa ChToi, Sneha L.

ABSTRACT: Co-infections or consecutive infections of mucormycosis and aspergillosis are very rare. Additionally, distinguishing between these two infections is also difficult as both these conditions have similar clinical features. We report two similar cases from Tamilnadu, who presented to a tertiary care centre in Puducherry, India in 2017 (first case) and 2019 (second case). The first case was a 70-year-old, non-diabetic male patient who presented with haemoptysis with a prior history of pulmonary tuberculosis. Computed tomography bronchial angiography revealed an air-crescent sign and the histopathological examination showed a fungal ball (aspergillus and mucor) in the right upper lobe and foci of fungal infection in the middle lobe. The second case was a 65-year-old diabetic male patient who presented with blackish expectoration and haemoptysis. A high-resolution computed tomography scan showed a reverse-halo sign in the right upper lobe. The results of the bronchoscopy-guided biopsy were consistent with a diagnosis of mixed mucormycosis and aspergillosis with angioinvasion. Both patients responded to amphotericin B with surgical excision of the affected lobe in the first case. A high degree of clinical suspicion, early surgical intervention and antifungal therapy are essential in the treatment of this rare co-infection.

Keywords: Aspergillosis; Mucormycosis; Bronchoscopy; Coinfection; Amphotericin B; Case Report; India.

CO-INFECTIONS OR CONSECUTIVE INFECTIONS of Mucormycosis and Aspergillosis are very rare and usually observed in immunocompromised patients.¹ Distinguishing between these infections poses a challenge as both have similar risk factors and clinical features. The following cases demonstrate the importance of tissue diagnosis, variations in treatment response and the need for an aggressive multimodal approach in fungal co-infections to treat a patient.

Case One

A 70-year-old non-diabetic male patient from Tamilnadu, presented to a tertiary care centre in Puducherry, India in 2017, with a history of haemoptysis (approximately 50 mL/day) associated with intermittent fever; the condition had lasted for a month prior to presentation. The patient also had a history of shortness of breath [mMRC (Modified Medical Research Council) grade III] with no orthopnoea. The patient had received anti-tuberculosis treatment 10 years prior to presentation for five months. The patient was not on any immunosuppressive drugs and did not show signs of diabetes; his random blood sugar (RBS) was 96 mg/dL at the time of presentation and <140 mg/dL during the entire hospital stay. There was no history suggestive of any other systemic or immunological co-morbidity.

The autoimmune serology work up (antinuclear antibody [ANA]) was negative and no mycobacterium tuberculosis was detected in the sputum using a cartridge based nucleic acid amplification test (CBNAAT). Subsequent work-up with a high resolution computed tomography of the thorax (HRCT) and computed tomography bronchial angiography showed an intra-cavitary mass surrounded by a crescent of air (air crescent sign) in the thick-walled cavity of the right upper lobe [Figure 1A].

There were prominent tortuous vessels noted in the cavity wall supplied by branches from the right subclavian, intercostals, pulmonary and bronchial arteries along with right middle lobe fibrosis and traction bronchiectasis. Due to a suspicion of an invasive fungal disease, a computed tomography (CT) scan of the brain and paranasal sinuses was taken. However, the scan did not show any lesions suggestive of fungal dissemination. The patient underwent emergency upper and middle lobectomy with no surgery-related complications. Histopathology of the resected specimen was suggestive of a fungal ball (*Aspergillus* and *Mucor*) colonising the lung cavity without definite tissue or angio-invasion. In addition, there were a few foci of infection in the middle lobe which showed colonies of *Aspergillus* and *Mucor*. The patient was administered liposomal amphotericin B (AmB) intravenously at 5 mg/kg/day for a period of 21 days and his post-operative follow-up period of three months, six months and one year after surgery were uneventful.

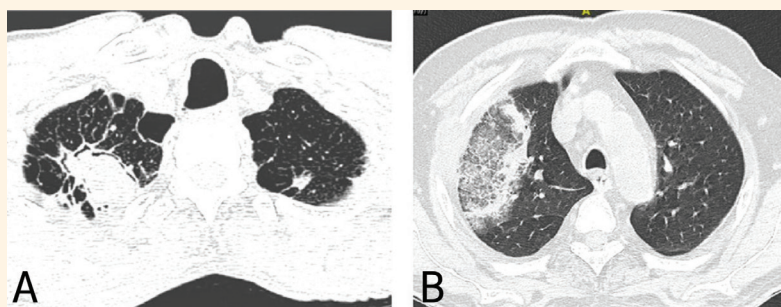


Figure 1: Computed tomography of (A) a 70-year-old male patient showing a thick-walled cavity in the right upper lobe with an intracavitary mass surrounded by a crescent of air known as the 'air crescent sign' (case one) and (B) a 65-year-old male patient showing central ground-glass opacity surrounded by a complete ring of consolidation known as the 'reverse halo sign' (case two).

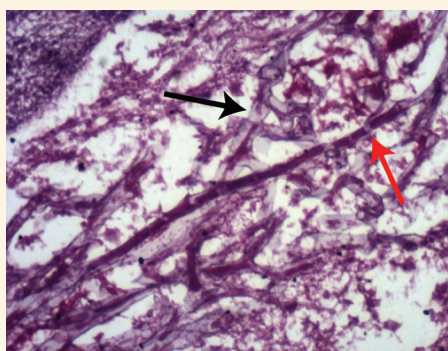


Figure 2: Histopathology of lung biopsy showing *Aspergillus* and *Mucor* in a 65-year-old male patient. This is a periodic acid-Schiff staining at x40 magnification showing multiple branching septated hyphae (black arrow) consistent with *Aspergillus* along with broad-based, ribbon-like, non-septate hyphae (red arrow) suggestive of *Mucor*.

Case Two

The second case is of a 65-year-old alcoholic male patient, also from Tamilnadu, presenting to a tertiary care centre in Puducherry, India, in 2019 with cough associated with blackish mucoid expectoration and haemoptysis; the condition had lasted for two months prior to presentation. A chronic smoker, the patient was experiencing breathlessness (mMRC grade III)

and intermittent fever. He was treated at home with broad-spectrum antibiotics for one week. At the time of presentation, the patient had type-1 respiratory failure, an elevated blood cell count of 12,470/mm³ (Normal range: 4,000–7,000 mm³) and altered renal parameters (blood urea of 64 mg/dL [normal range: 15–40 mg/dL], serum creatinine of 1.58 mg/dL [normal range: 0.7–1.2 mg/dL] and RBS of 286 mg/dL [normal range: 70–140 mg/dL]). The autoimmune serology work up ANA was negative. HRCT showed right upper lobe central ground-glass opacity surrounded by a ring of consolidation (reverse halo sign) along with a cavitating consolidation involving the right upper and middle lobes suggestive of fungal pneumonia [Figure 1B].

To rule out the possibility of a disseminated fungal infection, a CT scan of the brain with the paranasal sinuses was taken; this scan appeared normal. Fibre optic bronchoscopy (FOB)-guided trans bronchial lung biopsy (TBLB) showed dense acute inflammatory cells and fungal colonies morphologically consistent with a diagnosis of mixed mucormycosis and aspergillosis with angio-invasion [Figure 2]. As the patient had deranged renal parameters, he was treated with intravenous liposomal AmB at 5 mg/kg/day. Blood sugars were adequately controlled (maintained at RBS <140 mg/dL) with parenteral insulin. The

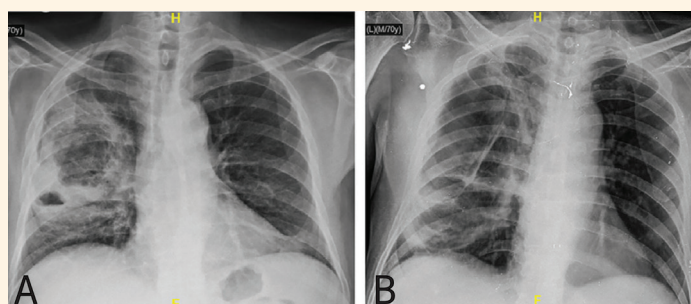


Figure 3: Chest X-ray of a mixed infection of *Aspergillus* and *Mucor* showing significant radiological resolution after three weeks of amphotericin B therapy in a 65-year-old male patient.

patient responded well to the treatment and improved both clinically and radiologically [Figure 3].

Written informed consent was obtained from both patients for the publication of these case reports and images.

Discussion

The human respiratory tract is continuously exposed to the environment where various pathogenic organisms either alone or in combination can cause disease, particularly in immune-compromised patients. The risk factors for fungal co-infection include diabetes mellitus, immune-suppression, haematological malignancies and cancer chemotherapy.² Diabetes mellitus is the most common predisposing factor for mucormycosis and other fungal pneumonia.²⁻⁵ *Aspergillus* spp. and *Mucorales* are the most common ubiquitous saprophytic opportunistic fungal infections which need specific environmental exposures.⁶ This combination of disease occurring simultaneously or sequentially in the lungs is rare and is less common than rhino cerebral disease.⁷

Mucormycosis or zygomycosis is a rare opportunistic fungal infection caused by the *Mucorales* order of fungi including the genera *Rhizopus* spp., *Absidia* spp., *Cunninghamella* spp., *Rhizomucor* spp., *Mucor* spp., *Apophysomyces* spp.⁸ Belonging to the *Mucoraceae* family, mucormycosis usually manifests as an invasive infection involving para nasal sinuses, lungs or skin. It may also manifest as disseminated disease.⁸

Aspergillus species are ubiquitous and saprophytic fungi that can cause pulmonary infection commonly after inhalation of its conidia or mycelial fragments from the environment.⁶ Pulmonary aspergillosis has been classified into (1) fungus balls within the cavities (2) invasive aspergillosis (3) allergic bronchial aspergillosis and (4) rhinosinusitis.⁹ *Aspergillus* colonizes the cavitory lesions especially in the healed tubercular cavities of the lungs.¹⁰

Inside the cavity, the fungus forms a freely moving fungal ball consisting of fungal hyphae (commonly of *Aspergillus* spp., occasionally of *Mucor* spp. or of both in combination), inflammatory cells and fibrin material.¹¹ Fungal toxins erode the walls of the cavity and spread by local destruction, causing massive haemoptysis which can be predominant and sometimes the sole symptom of the disease.¹²

Distinguishing between mucormycosis and aspergillosis by clinical or radiographic signs is difficult as both conditions afflict immune suppressed individuals. Such patients also present with similar

features of pneumonia. The identification of a causative factor plays a crucial role in the outcome as these two entities respond differently to various antifungal agents. Chamiloet al. systematically compared mucormycosis and aspergillosis and concluded that no clear differences were noted clinically and very few differences were observed in the CT findings.¹³ Hence, wherever feasible, confirmation by microscopy is necessary for diagnostic certainty.

Direct histological examination of the tissue biopsy remains the gold standard in the diagnosis of invasive fungal infections.¹⁴ Based on the clinical findings, radiological imaging, histopathology and by utilizing the revised definitions from the European Organization for Research and Treatment of Cancer/ Invasive Fungal Infections Cooperative Group and the National Institute of Allergy and Infectious Diseases Mycoses Study Group, a diagnosis of proven invasive fungal infection was established in both the reported cases.¹⁴

The choice of antifungal agent must be based on the clinical characteristics and local epidemiology of the fungal infections.¹⁵ The Infectious Diseases Society of America (IDSA) recommends monotherapy with voriconazole or isavuconazole in aspergillosis. AmBdeoxycholate and its lipid derivatives cover *Aspergillus* spp., *Candida* and *Mucormycetes*. These drugs are appropriate options for the initial treatment and in salvage therapy of *Aspergillus* infections in resource-limited settings and conditions where voriconazole cannot be administered.¹⁵ Itraconazole is one of the preferred agents used to treat aspergillosis.¹⁶ Surgical excision of the cavity and the involved segment or lobe in the aspergilloma can be done with relatively low morbidity and mortality to achieve complete remission and a symptom-free state.¹⁷ Intravenous AmB (a lipid formulation) is the drug of choice for initial therapy in the case of mucormycosis. Adjuvant extensive surgical debridement should also be taken into consideration in selected cases.¹⁸

The first case in this report presented with a fungal ball in the post-tubercular cavity of the lung evidenced by HRCT, initially thought to be caused by *Aspergillus* spp. Later on, as histopathological features were suggestive of the fungal ball (*Aspergillus* and *Mucor*) colonizing the lung cavity, liposomal AmB was administered intravenously. The second case was a diabetic patient who presented with pneumonia and a suspicion of fungal aetiology. He was initially started on liposomal AmB as part of the treatment procedure. Later on, FOB guided TBLB suggested an *Aspergillus* and *Mucor* co-infection. Co-infection with *Aspergillus* and *Mucor* in the post tubercular cavity is rare. There

are cases reported in the literature where post-tubercular cavity in the lung with a *Mucor* fungal ball was treated using liposomal AmB.¹⁹ Though *Aspergillus* is the most common fungus causing the formation of a fungal ball, only 5 case reports (delineating 8 patients) of paranasal fungal balls caused by *Mucor* have been published in the literature.²⁰

It should be noted that there are some reports where invasive pulmonary *Aspergillus* and *Mucor* were countered adequately using high doses of liposomal AmB alone.²¹ However, in a report of pulmonary *Aspergillus* and *Mucor* co-infection in a diabetic patient, outcomes were not satisfactory even with extensive antifungal treatment with intravenous amphotericin and voriconazole.¹ Delay in diagnosis, non-affordability of new and effective antifungal agents, lack of consensus concerning the dosage and duration of antifungals in mixed infections play a major role in the treatment outcome.

Conclusion

Mucormycosis and aspergillosis are rare co-infections that could potentially lead to death. A high degree of suspicion, early detection by a multidisciplinary approach, appropriate antifungal therapy and, if necessary, surgical resection are essential in the treatment of this co-infection. Antimicrobial therapy must be rationalized, especially in co-infections with underlying immunosuppressive conditions as there is no clear consensus on the treatment of mixed co-infections that respond differently to standard treatment protocols.

References

1. Mahadevaiah AH, Rajagopalan N, Patil M, Shivaprasad C. Co-infection of pulmonary mucormycosis and aspergillosis presenting as bilateral vocal cord palsy. *BMJ Case Rep* 2013; 2013:bcr2013009615. <https://doi.org/10.1136/bcr-2013-009615>.
2. Petrikkos G, Skiada A, Lortholary O, Roilides E, Walsh TJ, Kontoyiannis DP. Epidemiology and clinical manifestations of mucormycosis. *Clin Infect Dis* 2012; 54:S23–34. <https://doi.org/10.1093/cid/cir866>.
3. Trof RJ, Beishuizen A, Debets-Ossenkopp YJ, Girbes AR, Groeneveld AB. Management of invasive pulmonary aspergillosis in nonneutropenic critically ill patients. *Intensive Care Med* 2007; 33:1694–703. <https://doi.org/10.1007/s00134-007-0791-z>.
4. Li Y, Fang W, Jiang W, Hagen F, Liu J, Zhang L et al. Cryptococcosis in patients with diabetes mellitus II in mainland China: 1993–2015. *Mycoses* 2017; 60:706–13. <https://doi.org/10.1111/myc.12645>.
5. Nunes JO, Pillon KR, Bizerra PL, Paniago AM, Mendes RP, Chang MR. The simultaneous occurrence of histoplasmosis and cryptococcal fungemia: a case report and review of the literature. *Mycopathologia* 2016; 181:891–97. <https://doi.org/10.1007/s11046-016-0036-1>.
6. Dagenais TR, Keller NP. Pathogenesis of *Aspergillus fumigatus* in invasive aspergillosis. *Clin Microbiol Rev* 2009; 22:447–65. <https://doi.org/10.1128/CMR.00055-08>.
7. Spellberg B, Edwards J, Ibrahim A. Novel perspectives on mucormycosis: Pathophysiology, presentation, and management. *Clin Microbiol Rev* 2005; 18:556–69. <https://doi.org/10.1128/CMR.18.3.556-569.2005>.
8. Hamilos G, Samonis G, Kontoyiannis DP. Pulmonary mucormycosis. *Semin Respir Crit Care Med* 2011; 32:693–702. <https://doi.org/10.1055/s-0031-1295717>.
9. Kousha M, Tadi R, Soubani AO. Pulmonary aspergillosis: a clinical review. *Eur Respir Rev* 2011; 20:156–74. <https://doi.org/10.1183/09059180.00001011>.
10. Kawamura S, Maesaki S, Tomono K, Tashiro T, Kohno S. Clinical evaluation of 61 patients with pulmonary aspergilloma. *Intern Med* 2000; 39:209–12. <https://doi.org/10.2169/internalmedicine.39.209>.
11. Lahiri TK, Agarwal D, Reddy GE, Bajoria A. Pulmonary mucoraceous fungal ball. *Indian J Chest Dis Allied Sci* 2001; 43:107–10.
12. Muqetadnan M, Rahman A, Amer S, Nusrat S, Hassan S, Hashmi S. Pulmonary mucormycosis: An emerging infection. *Case Rep Pulmonol* 2012; 2012:120809. <https://doi.org/10.1155/2012/120809>.
13. Chamilos G, Marom EM, Lewis RE, Lionakis MS, Kontoyiannis DP. Predictors of pulmonary zygomycosis versus invasive pulmonary aspergillosis in patients with cancer. *Clin Infect Dis* 2005; 41:60–6. <https://doi.org/10.1086/430710>.
14. De Pauw B, Walsh TJ, Donnelly JP, Stevens DA, Edwards JE, Calandra T, et al. Revised definitions of invasive fungal disease from the European Organization for Research and Treatment of Cancer/Invasive Fungal Infections Cooperative Group and the National Institute of Allergy and Infectious Diseases Mycoses Study Group (EORTC/MSG) Consensus Group. *Clin Infect Dis* 2008; 46:1813–21. <https://doi.org/10.1086/588660>.
15. Patterson TF, Thompson GR 3rd, Denning DW, Fishman JA, Hadley S, Herbrecht R, et al. Practice guidelines for the diagnosis and management of aspergillosis: 2016 update by the Infectious Diseases Society of America. *Clin Infect Dis* 2016; 63:e1–e60. <https://doi.org/10.1093/cid/ciw326>.
16. Patterson TF, Thompson GR 3rd, Denning DW, Fishman JA, Hadley S, Herbrecht R, et al. Practice Guidelines for the Diagnosis and Management of Aspergillosis: 2016 Update by the Infectious Diseases Society of America. *Clin Infect Dis* 2016; 63:e1–60. <https://doi.org/10.1093/cid/ciw326>.
17. Mohapatra B, Sivakumar P, Bhattacharya S, Dutta S. Surgical treatment of pulmonary aspergillosis: A single center experience. *Lung India* 2016; 33:9–13. <https://doi.org/10.4103/0970-2113.173077>.
18. Petrikkos G, Drogari-Apiranthitou M. Zygomycosis in immunocompromised non-haematological patients. *Mediterr J Hematol Infect Dis* 2011; 3:e2011012. <https://doi.org/10.4084/MJHID.2011.012>.
19. Mekki SO, Hassan AA, Falemban A, Alkotani N, Alsharif SM, Haron A, et al. Pulmonary mucormycosis: A case report of a rare infection with potential diagnostic problems. *Case Rep Pathol* 2020; 2020. <https://doi.org/10.1155/2020/5845394>.
20. Cho HS, Yang HS, Kim KS. Mucormycosis (mucor fungus ball) of the maxillary sinus. *Ear Nose Throat J* 2014; 93:E18–22. <https://doi.org/10.1177/014556131409300904>.
21. Bergantim R, Rios E, Trigo F, Guimaraes JE. Invasive coinfection with *Aspergillus* and *Mucor* in a patient with acute myeloid leukemia. *Clin Drug Investig* 2013; 33:S51–5. <https://doi.org/10.1007/s40261-012-0022-4>.