

MORPHOMETRIC FEATURES OF THE OVIDUCT AND UTERUS IN ADULT NORMAL AND OVARIECTOMIZED IRAQI BLACK DOES (*Caprus hircus*)

Khalid Ibrahim Al-Khazraji^{1,3}

Shaker Muhmood Merhesh²

Mohammad Jawad Eesa²

Hanaa Kareem Al-Shammary¹

^{1,2} Dept. of Anatomy and Histology, College of Vet. Med., Univ. of Diyala and Baghdad, respectively, Iraq.

³Corresponding author: Alkhazraji.khalid11@gmail.com

ABSTRACT

In order to determine the effect of the removal of ovary on the anatomical properties of the oviduct and uterus in adult Iraqi black does (*Caprus hircus*), a total of fifteen young female Iraqi goats (age 2-3 months) were used in this study. The goats were allotted into three equal groups; group A includes young goats that left normal, while the group B comprised young goats underwent to right laparoscopic unilateral ovariectomy and the group C includes young goats subjected to bilateral ovariectomy. All animals in these groups were left to reach the adult stage (age 7 months), in which they underwent to removal the oviduct and uterus laparoscopically by using of harmonic scalpel. A total findings of the study revealed significant increase in mean of the length and width of oviduct in adult normal and unilateral ovariectomized does than those recorded in the does underwent to bilateral ovariectomy. In addition, the length and width of the uterine horns and uterine body showed significant decrease in the does subjected to bilateral ovariectomy from those detected in both normal and unilateral ovariectomized does. It concluded that the development of female genital organs depend on the level of the ovarian steroid hormones in does.

Key words: Oviduct, uterus, Doe.

INTRODUCTION

The goat is an important animal reared to produce milk, meat, hair and leather in a large part of the world especially in Asia and Africa (Smith and Sharman, 2009). Also, the goat is used as a better model for studies and biomedical researches (Fulton *et al.*, 1994). They characterized by its small size which does not require the employment of much money to set up projects to bred and easily handled and the reproductive efficiency of reaching the puberty, low duration of pregnancy and numerous births (Mahgoub *et al.*, 2012 ; Liu *et al.*, 2013). The management and reproduction play an important role in increasing the production of the goat. Thus, the reproductive efficiency is one of

the most essential economic traits because its impact on the annual production of goat kids (Duricic *et al.*, 2012). A clear idea on the genital organs of female goats is requisite to maintain the proper reproductive performance as well as the information about the genital organ measurements is essential to conduct the recent reproductive technologies (Gupta *et al.*, 2011). Moreover, this information could be assist in the diagnosis of some cases of infertility and thus help in obtaining optimal treatment of these diseases (Kumar *et al.*, 2004). Female genital organs consist of vagina, uterus, oviducts and ovaries. Ovaries produces ovum and performs a critical role as an endocrine organ, serving as the principle source of sex steroid hormones in the female, so the function and maintenance the female udder, genital organs and behavior depends on the normal function of the ovary (Rodgers *et al.*, 2003). Oviducts are a pair of tubes conducting the egg from the ovary to the uterus, regarded as the site of fertilization, contribute in oocyte maturation, sperm capacitation and the development of the early embryo (Marettova and Marett, 2014). The uterus in mammals is essential organ for reproduction and fertility of female and the health of their young (Kumar *et al.*, 2013 ; Filant and Spencer, 2014). In last decades, the laparoscopic devices were used in the procedure of ovariectomy and ovariohysterectomy because this technique provided several benefits more than the open surgery such as less surgical trauma, shorter time, safe, less complications and minimize the pain and stress to animals (Mascarenhas and Simoes, 2009 ; Caron, 2013). Because of no accessible studies regarding the effect of unilateral and bilateral laparoscopic ovariectomy in young Iraqi black goats, therefore the aim of this study was to evaluate the effect of unilateral and bilateral ovariectomy in young Iraqi black goats on the morphometric properties of the oviduct and uterus at adult stage.

MATERIALS AND METHODS

A total of fifteen healthy young female Iraqi black goats aged from two to three months (average 2.5 ± 0.18 months), and weighed between 5 and 7.2 kg (mean 6.3 ± 0.37 kg) were used. All goats were housed under similar conditions of managements and feeding. The animals were divided randomly into three equal groups (5 animals for each group). The young goats in group A left normal, and the animals in group B were subjected to right unilateral laparoscopic ovariectomy, while the animals in group C underwent to bilateral laparoscopic ovariectomy. All animals in three groups left to reach the adult stage at 7 months age in which the animals underwent to removal their oviduct and uterus laparoscopically in order to determination of the morphometric

measurements. The procedure of ovariectomy for animals in both groups B and C at young stage, and the removal of oviduct and uterus from animals of all groups at adult stage was performed by using a three portal technique laparoscope (Karl Storz Company, Germany) and harmonic scalpel device (Ultracision Harmonic Scalpel, Ethicon Endo-Surgery, Inc. Cincinnati, OH, USA). The animals were fasted 24 hours for feed and 12 hours for water prior to surgery. Under aseptic technique, the ventral abdominal wall from the xyphoid cartilage to the inguinal subregion was prepared surgically. A combination of xylazine hydrochloride 2% at dose of 0.05 mg kg⁻¹ B.W., and ketamine hydrochloride 10% at dose of 3 mg kg⁻¹ B.W. was administered intramuscularly to provide general anesthesia (Ivany and Muir, 2004), and the goat placed in dorsal recumbency. The three operating portals, one for telescope and two for instruments were introduced in the abdominal area and the pneumoperitoneum with CO₂ was performed. The right ovary in animal of group B was manipulated by the two grasper forceps until the ovarian pedicle (mesovarian) was easily accessible. The harmonic scalpel blade was then placed across the cranial aspect of the mesovarian for hemostasis and transected (Fig. 1) and then repeated the cycle of hemostasis and transection until complete resection of mesovarian and the proper ligament of the ovary using the harmonic scalpel blade. When the entire mesovarian and proper ligament were completely transected, the right ovary was free and removed from the abdominal cavity together with their holding grasper and cannula. The ovarian pedicle was observed to identify adequate hemostasis before the laparoscopic completion. In bilateral laparoscopic ovariectomy for animal in group C, after removal the right ovary, the cannula re-inserted in their place and advanced the laparoscopic grasper forceps into. The left ovary was then removed in similar technique that used for removing of the right ovary. At adult stage, all animals in three groups underwent to procedure of ovariohysterectomy by using laparoscope and harmonic scalpel device to extract the oviduct and uterus from them. The open holes in the abdominal wall for all animals were closed routinely.

For anatomical examination, The uterine tube and uterus after removed out of the body, dissected free of their ligamentous attachments, observed and recorded the following anatomical indices: the external diameter of right and left oviduct, the both oviduct length were measured on their extended length from the top of the infundibulum to the tubal uterine junction, measuring of each uterine horn diameter and length as well as the diameter and length of uterine body. All measuring performed by using of digital caliber and thread and

recorded in millimeter (Fig. 2). Results underwent to statistical analysis using SPSS program (version 16.0, Chicago, SPSS Inc. 2007). Analysis of variance (ANOVA) and the least significant difference (LSD) were used to compare the means of groups for each parameter. Differences were considered significant at level ($P < 0.05$).

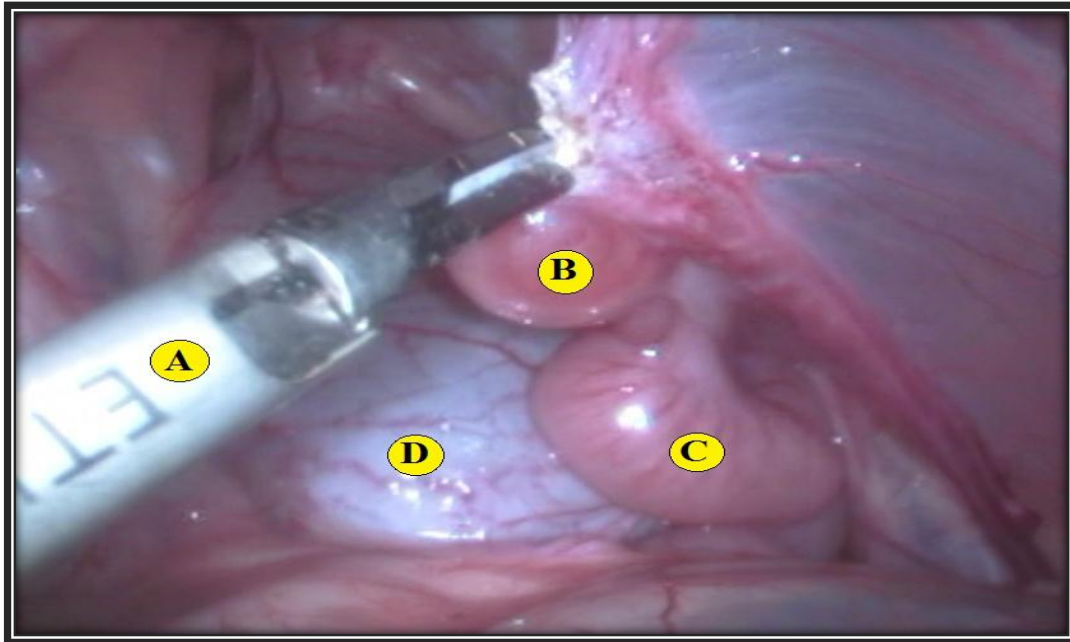


Figure 1. Laparoscopic image shows hemostasis and transection of the cranial aspect of mesovarian by the harmonic scalpel for ovariectomy. The harmonic scalpel (A), right ovary (B), uterine horn (C), urinary bladder (D)



Figure 2. The method of measuring the width of oviduct (external diameter) in goat using digital caliper

RESULTS AND DISCUSSION

The ovaries, oviduct and uterus in all groups of does in the present study were removed successfully through a three ports laparoscopic technique with harmonic scalpel device. Access and visualization for genital tract was excellent in laparoscopy. This results was consistent with Teixeira *et al.*, (2011) who referred to the pneumoperitoneum and the magnification of the field to facilitate the laparoscopic operations. The harmonic scalpel device was relatively easy to use and achieved complete hemostasis and transection of the ovaries, oviduct and uterus. This result confirmed the recommendations of previous studies on other animals, which reported that the use of the harmonic scalpel was safe and an alternative to other instruments that have been used with laparoscopic surgery such as laparoscopic ovariectomy in mares (Alldredge and Hendrickson, 2004) and the laparoscopic ovariohysterectomy in bitch (Minami *et al.*, 1997).

The anatomical observation of present study revealed that the oviducts in doe consisting of two convoluted tubes running from the ends of the uterine horns to near the ovaries. Each oviduct consists of three portions; the infundibulum, ampulla and the isthmus. These findings were in agreement with other researcher (Konig and Liebich, 2009). The measurements of the length and width (external diameter) of the oviducts in the goats of this study are shown in the table 1.

Table 1. Mean \pm S.E of biometric values for the length and width of oviduct in does in the three groups

Groups	Oviduct measurements		
	side	Length (mm)	Width (mm)
(A)	Left	113.43 \pm 0.0451 A	2.22 \pm 0.0237 A
	Right	112.27 \pm 0.0696 B	2.19 \pm 0.0278 A
(B)	Left	113.37 \pm 0.0320 A	2.17 \pm 0.0220 A
	Right	112.24 \pm 0.0516 B	2.16 \pm 0.0242 A
(C)	Left	79.83 \pm 0.0211 C	1.23 \pm 0.0188 B
	Right	79.70 \pm 0.0469 C	1.22 \pm 0.0124 B

In same column, different capital letters represent significant differences at ($p < 0.05$).

It was detected significant difference in mean values of the length and width of oviduct in dose of group A and B compared with those in group C, but no significant differences were observed between the group A and B in those measurements table 1. The mean length of the left and right oviducts in normal does of group A were longer than values that reported by Gupta *et al.*, (2011) in goats, but they were shorter than those mentioned by Akhtar *et al.*, (2012) and Suri *et al.*, (2013) in goats. The difference in the measurements of oviducts in

does that recorded in this study may be due to differences in the levels of ovarian steroid hormones, whereas the variations between the results of this study and the findings of other studies in goats could be due to the breed differences.

The macroscopic examination of the present work showed that the uterus in doe was bicornuate, composed of two long coiled horns and short body (Fig. 3). The shape of uterus is in agreement with a pervious classification of uterus in ruminant (Kumar, 2009). It was observed that each horn consists of two portions; cranial free portion connects with oviduct and caudal attached portion connects with the body of uterus. Moreover, the width of the two horns were tapered gradually from the bifurcation to tip of horn, and they were coiled ventrally on herself. At the bifurcation of horns, it was detected one intercornual ligament. These anatomical observations for the uterus in the present study were consisted with description of uterus in small ruminant by other researcher (Nickel *et al.*, 1979).

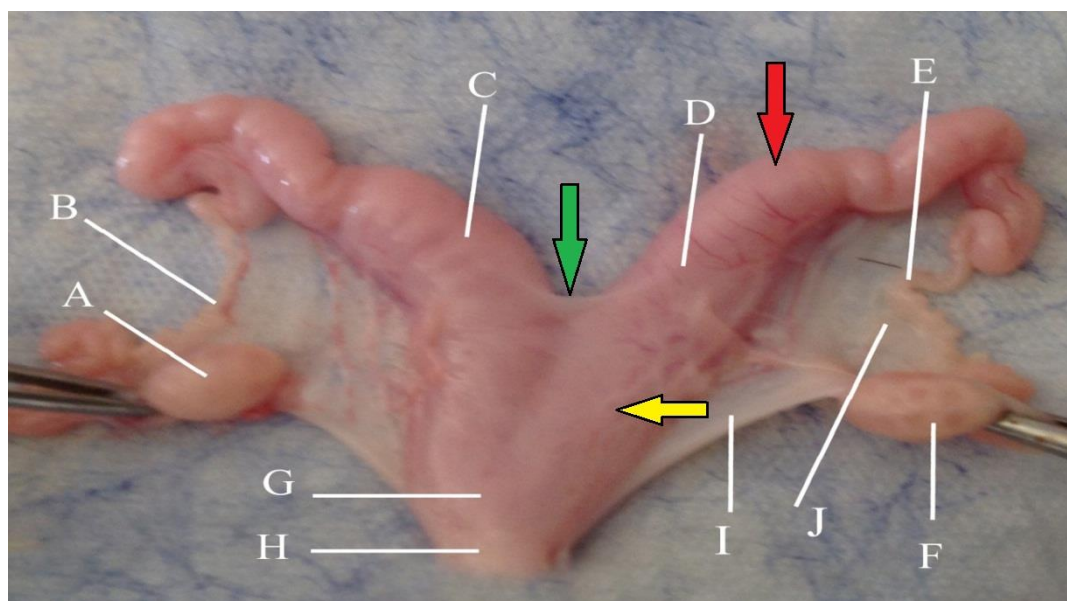


Figure 3. The female genital system of doe in group A shows its parts: left ovary (A), left oviduct (B), left horn (C), right horn (D), right oviduct (E), right ovary (F), uterine body (G), part of cervix (H), mesometrium (I), mesosalpinx (J), free portion of uterine horn (red arrow), attached portion of uterine horn (yellow arrow), intercornual ligament (green arrow)

The mean values of the length and width (external diameter) of uterine horns in does in all groups are presented in table 2.

Table 2. Mean \pm S.E of biometric values of the length and width of uterine horns in does in three groups (Millimeter)

Groups	Uterine horn measurements		
	Side	Length (mm)	Width (mm) External diameter
(A)	Left	109.21 \pm 0.0615 A	14.27 \pm 0.0347 A
	Right	108.91 \pm 0.0868 B	14.26 \pm 0.0238 A
(B)	Left	109.15 \pm 0.0776 A	14.27 \pm 0.0527 A
	Right	108.87 \pm 0.0823 B	14.21 \pm 0.0411 A
(C)	Left	54.95 \pm 0.0261 C	6.42 \pm 0.0283 C
	Right	54.90 \pm 0.0330 C	6.42 \pm 0.0231 C

In same column, different capital letters represent significant differences at ($p < 0.05$).

According to table 2, there was no significant differences in the length and width of uterine horns between group A and B. Besides, the mean values for the length of left uterine horn in group A and B which recorded significant increased than those values in the right uterine horns. The left and right horns in group C revealed significant decrease in length and width than those reported in groups A and B. However, it was detected that no significant differences in the width between the two horns within same group.

The results of measuring the length of left and right uterine horns in group A and B were in comparable range to that reported by other researchers (Jaji *et al.*, 2012 ; Kawu *et al.*, 2013) in goats, whereas higher values for the length of uterine horns were recorded by Barwary (2011) in goats. In addition, the mean width of uterine horn in group A and B were in similar range that mentioned by Akhtar *et al.*, (2012) in goats, while lower value of uterine horn width was reported by Adigwe and Fayemi (2005) in goats, and higher mean width of horns observed by Jaji *et al.*, (2012) in goats.

The mean length and width (external diameter) of the uterine body in the doe groups of present study are summarized in table 3.

Table 3. Mean \pm S.E of biometric values of the length and width of uterine bodies in does in four groups, millimeter

Groups	Uterine body	
	Length (mm)	Width (mm) External diameter
(A)	21.30 \pm 0.0383 A	19.17 \pm 0.0436 A
(B)	21.09 \pm 0.0418 A	18.24 \pm 0.0923 B
(C)	11.53 \pm 0.0247 B	10.60 \pm 0.0287 C

In same column, different capital letters represent significant differences at ($p < 0.05$).

The measurements of uterine body revealed no significant differences in the length of uterine body between group A and B (Table 3). Significant decrease in the length and width of uterine body in group C in compared with those observed in both groups A and B (Table 3). The width of uterine body recorded significant differences among the three groups. The length of uterine body that showed in group A and B were in comparable range that reported by Sisson, (1975). However, Akhtar *et al.*, (2012) recorded lower mean length of uterine body, and Adigwe and Fayemi (2005) reported higher mean length of uterine body when compared with finding in group A and B. The mean width of uterine body that observed in group A and B were lower than that reported by Jaji *et al.*, (2012) and higher than that recorded by Akhtar *et al.*, (2012). The variation in the measurements of uterine horns and bodies that appeared between doe groups in this study could related to the condition of animals whether normal or ovariectomized. The differences between the findings of present study and other studies in goats could be due to breed differences.

CONCLUSION

The length and width (external diameter) of both oviduct as well as the uterine measurements were increased in adult normal and unilateral ovariectomized goats than those detected in bilateral ovariectomized does. We conclude that the evolution of female genital organs depend on the level of the ovarian steroid hormones, therefore, the development of the oviduct and uterus in unilateral ovariectomized goats were affected slightly and showed great similarity with those in normal goats, while this development was strongly influenced and retarded after bilateral ovariectomy.

REFERENCES

- Adigwe, P. I. and O. Fayemi. 2005. A biometric study of the reproductive tract of the red sokoto (Maradi) goats of Nigeria. *Pakistan Vet. J.* 25(3): 149-150.
- Akhtar, M. S., A. Farooq, M. M. Ayaz, M. Hussain, M. H. Lashari and S. A. Muhammad. 2012. Age related changes in biometry of genital organs of Teddy goat. *Int. J. Engineering Sci. Metallurgy.* 2(1): 382-384.
- Allredge, J. G. and D. A. Hendrickson. 2004. Use of high-power ultrasonic shears for laparoscopic ovariectomy in mares. *J. Am. Vet. Med. Assoc.* 255(10): 1578-1580.
- Barwary, M. S. Q. 2011. Seasonal physiological activity of genital system in local sheep and goat in Kurdistan region. Strategies and challenges for sustainable animal agriculture-corp system. Proceedings of the 3rd

- international conference on sustainable animal agriculture for developing countries, Thailand. pp: 49-52.
- Caron, J. P. 2013. Equine laparoscopy: gonadectomy. *Compend. Contin. Educ. Vet.* 35(2): 4.
- Duricic, D., J. Grizelj, T. Dobranic, I. Horapin, S. Vince, P. Kocilla, I. Folnozic, M. Lipar, G. G. Gracner and M. Samardzija. 2012. Reproductive performance of boer goats in a moderate climate zone. *Vet. Arhiv.* 82(4): 351-358.
- Filant, J. and T. E. Spencer. 2014. Uterine glands: Biological roles in conceptus implantation, uterine receptivity and decidualization. *Int. J. Dev. Biol.* 58: 107-116.
- Fulton, L. K., M. S. Clarke and H. E. Farris. 1994. The goat as a model for biomedical research and teaching. *Oxford J.* 36(2): 21-29.
- Gupta, M. D., M. M. Akter, A. D. Gupta and A. Das. 2011. Biometry of female genital organs of black Bengal goat. *Inter. J. Nat. Sci.* 1(1): 12-16.
- Ivany, J. M. and W. W. Muir. 2004. Farm animal anesthesia. In Fubini, S. L. and N. G. Dusharme, (eds.). *Farm Animal Surgery. Saunders Company.* pp: 97-112.
- Jaji, A. Z., R. A. Buduwara, A. I. Kanmu, M. Zachariah, J. Luka and B. Gambo. 2012. Pregnancy related biometric changes in the ovaries and uterus of the sahelian goat. *Sokoto J. Vet. Sci.* 10(1): 18-21.
- Kawu, K., L. Eduvie, C. Lakpini and I. Ayo. 2013. Morphometric dimentions of the genitalia of savanna brown goats between day 24 and 30 postpartum. *J. Agri. Vet. Sci.* 5(4): 46-50.
- Konig, H. E. and H. G. Liebich. 2009. Female genital organs. In: Konig, H. E. and Liebich, H. G., eds. *Veterinary Anatomy of Domestic Mammals.* 4th revised ed. Schattauer, Stuttgart, Germany. PP: 423-440.
- Kumar, P. 2009. Comparative anatomy of reproductive tracts. In: *Applied veterinary gynaecology and obstetrics.* 1st. ed. International Book Distributing Co. India. pp: 5-34.
- Kumar, R., P. W. Ramteke, A. Nath and S. P. Singh. 2013. Role of candidate genes in regulation of embryonic survival and maternal recognition of pregnancy in farm animals. *Vet. World.* 6(5): 280-284.
- Kumar, S., F. A. Ahmed and M. S. Bhadwal. 2004. Biometrical of female genitalia of Murrah buffalo (*Bubalus Bubalis*). *Indian J. Anim. Reprod.* 25(2): 143-145.

- Liu, J., F. Wang, X. Lang, X. Zha, X. Sun, Y. Yue, R. Feng, Y. Hui and J. Guo. 2013. Analysis of geographic and pairwise distances among Chinese Cashmere goat populations. *Asian-Australas J. Anim. Sci.* 26(3): 323-333.
- Mahgoub, O., I. T. Kadim and E. C. Webb. 2012. Goat meat production and quality. CAB. International, London, UK. PP: 1-5.
- Marettova, E. and M. Marett. 2014. An Immunohistochemical observations on the oviduct of the goat. *Reprod. Dom. Anim.* 49: 679-683.
- Mascarenhas, R. and J. Simoes. 2009. Laparoscopically aided ovariectomy in goats. *Veterinaria Com. Pt.* 1(1): 3.
- Minami, S., Y. Okamoto, H. Eguchi and K. Kato. 1997. Successful laparoscopy assisted ovariohysterectomy in two dogs with pyometra. *J. Vet. Med. Sci.* 59(9): 845-847.
- Nickel, R., A. Schummer and E. Seiferle. 1979. The Viscera of Domestic Mammals. 2nd revised ed. Verlag Paul Parey, Berlin, Hamburg. PP: 351-385.
- Rodgers, R. J., H. F. Irving-Rodgers and D. L. Russel. 2003. Extracellular matrix of the developing ovarian follicle. *Reprod.* 126: 415-424.
- Sisson, S. 1975. Ruminant urogenital system. *In: Getty, R., ed. The Anatomy of The Domestic Animals.* 5th ed. W. B. Saunders Company, Philadelphia. PP: 953-954.
- Smith, M. C. and D. M. Sharman. 2009. Goat Medicine. 2nd ed. Wiley-Blackwell. Singapore. pp: 3-4.
- Suri, S., K. Sarma and R. K. Tagger. 2013. Biometry of the internal female genital organ of different age groups of Bakerwali goat (Kaghani goat). *Indian J. Vet. Anat.* 25(1): 41-42.
- Teixeira, P. P. M., L. C. Padilha, T. F. Motheo, M. A. M. Silva, M. E. F. Oliveira, A. S. L. da Silva, F. F. P. C. Barros, L. N. Coutinho, M. C. S. Lopes, L. F. S. Rodrigues and W. R. R. Vicente. 2011. Ovariectomy by laparoscopy, a video-assisted approach or a complete laparoscopic technique in Santa Ines sheep. *Small Rum. Res.* 99: 199-202.

الصفات الشكلية القياسية لقناة البيض والرحم في الماعز العراقي الاسود البالغ الطبيعي والمستأصل المبايض

خالد ابراهيم عبد الخزرجي^{1,3} شاكر محمود مرهش² محمد جواد عيسى² هناء كريم الشمري¹

^{1,2} فرع التشريح والانسجة- كلية الطب البيطري - جامعتي ديالى وبغداد على التوالي، العراق.

³المسؤول عن النشر: Alkhazraji.khalid11@gmail.com

المستخلص

من أجل تحديد تأثير إزالة المبيض في الصفات التشريحية لقناة البيض والرحم في الماعز الأسود العراقي البالغ (*Caprus hircus*)، تم استخدام ما مجموعه خمسة عشر من اناث الماعز العراقي الاسود اليافعة (بعمر 2-3 أشهر) في هذه الدراسة. قسمت الماعز إلى ثلاث مجموعات متساوية. وشملت المجموعة (A) الماعز اليافعة التي تركت بحالتها الطبيعية، في حين أن المجموعة (B) تضمنت الماعز اليافعة التي خضت لعملية استئصال المبيض الايمن من جانب واحد منظاريا، وبينما الماعز اليافعة في المجموعة (C) خضت لعملية استئصال المبيضين منظاريا. تركت جميع الحيوانات في هذه المجموعات للوصول إلى مرحلة البلوغ (عمر 7 أشهر)، والتي خضعت فيها لإزالة قناة البيض والرحم منظاريا وباستخدام المشروط التوافقي. اظهرت نتائج الدراسة حدوث زيادة معنوية في متوسط طول وعرض قناة البيض في الماعز البالغ الطبيعي والمستأصل المبيض من جانب واحد عن تلك المسجلة في الماعز التي خضعت إلى استئصال المبيضين، فضلا عن ذلك سجلت معدلات طول وعرض قرون الرحم وجسم الرحم انخفاضا معنويا في الماعز المعرضة لعملية استئصال المبيضين عن تلك التي تم ملاحظتها في كل من الماعز الطبيعي والمستأصل المبيض من جانب واحد. وخلصت الدراسة إلى أن تطور الأعضاء التناسلية لاناث الماعز يعتمد على تواجد المبيض ومستوى الهرمونات الستيرويدية المبيضية.

الكلمات المفتاحية: قناة البيض، الرحم، الماعز.