

Early Clinical Experience with a New Tubular Equine Pericardial Stentless Aortic Valve

Friedrich S. Eckstein, Hendrik Tevaearai, Dorothee Keller, Jürg Schmidli, Franz F. Immer, Christian Seiler, Hugo Saner, Thierry P. Carrel

Departments of Cardiovascular Surgery and Cardiology, University Hospital Berne, Berne, Switzerland

ABSTRACT

Background: This study details a single-center experience with the 3F Therapeutics stentless aortic bioprosthesis (investigational device) and is part of a prospective, nonrandomized worldwide multicenter study. We assessed the implantation procedure and the valve's efficacy in terms of early mortality and morbidity and early echocardiographic valve performance.

Methods: Between June 2001 and March 2004, 24 patients (14 men/10 women) underwent aortic valve replacement (AVR) with a 3F valve. Mean age was 72 ± 13 years (range, 31-88 years). Combined revascularization was performed in 12 patients; 1 patient received biatrial ablation therapy, 1 patient a myectomy, and 3 patients combined carotid endarterectomy. Echocardiographic systolic gradient and valve performance were investigated intra- and postoperatively by Doppler echocardiography.

Results: There were 2 perioperative deaths, 1 non-valve related, due to aortic rupture in an 83-year-old woman, and 1 fatal cerebral embolism in a 77-year-old woman 5 days postoperatively. Cardiopulmonary bypass time was 102 ± 32 minutes, aortic cross-clamp time was 79 ± 24 minutes. Sizes for implanted 3F valves were 5×23 mm, 6×25 mm, 7×27 mm, and 6×29 mm. Follow-up systolic gradient results were 11.5 ± 4.7 mm Hg at 30 days ($n = 21$), 11.4 ± 4.5 mm Hg at 6 months ($n = 18$), and 13.3 ± 4.4 mm Hg at 12 months ($n = 13$). During the follow-up period trivial central aortic valve regurgitation was found in 6 patients.

Conclusion: The 3F aortic valve shows favorable preliminary hemodynamic results. Owing to the new valve design, implantation technique is simplified compared with other stentless valves. Anticoagulation treatment is mandatory for the first 3 months postoperatively. Long-term observation is necessary to assess life span and durability.

Presented at the 10th Annual CTT Meeting 2004, Miami Beach, Florida, USA, March 10-13, 2004.

Address correspondence and reprint requests to: Friedrich Stefan Eckstein, MD, Dept of Cardiovascular Surgery, University Hospital Berne, Freiburgstrasse, CH-3010 Berne, Switzerland; 41-31-6322310; fax: 41-31-6322919 (e-mail: friedrich.eckstein@insel.ch).

INTRODUCTION

Stentless aortic bioprostheses seem to offer significant advantages compared to stented valves with regard to flow characteristics, with improved hemodynamics provided by larger orifice areas leading to reduced transvalvular gradients and more rapid postoperative left ventricular mass regression. Implantation rates of stentless valves rise only slowly. This characteristic may be due partially to the fact that the implantation is a more demanding procedure with consecutively prolonged myocardial ischemic time. The majority of these superior valve concepts consist either of full aortic or mini-root configurations or subcoronary-designed porcine valves. To enhance structural long-time durability, newer valve concepts and designs should improve tensile stress capacity. The increasing use of pericardial tissue might offer several advantages over porcine native valves, including increased equality of the valves, reduced wall thickness of the noncusp valve tissue, reduced rate of calcification, and reduced rate of early failure due to leaflet rupture.

The 3F Therapeutics aortic bioprosthesis is a newly designed stentless pericardial valve (investigational device). Implantation technique is simplified compared to other stentless aortic valves. This study presents our initial experience with the 3F stentless aortic bioprosthesis and assesses technical details of the implantation procedure and the valve's efficacy in terms of perioperative hemodynamics and early echocardiographic valve performance.

MATERIAL AND METHODS

Valve Design and Characteristics

The 3F Aortic Bioprosthesis (3F Therapeutics, Lake Forest, CA, USA) is a new stentless valve that is currently under multicenter investigation. It has a totally new tubular design and is fabricated from 3 equal leaflets of equine pericardium processed with buffered glutaraldehyde. Before implantation the valve must be rinsed 3 times for 3 minutes in separate bowls of saline. The valve consists of only 3 leaflets. A very thin sewing cuff of polyester reinforces the proximal rim of the tubular valve. The valve can be implanted in the annulus using standard technique with either running or interrupted sutures. The distal 3 free

edges of the tubular form are specially folded and also reinforced by polyester tabs. These tabs are sutured to the aortic wall at an appropriate distance to the aortic annulus and should be fixed at the level of the natural commissures so as not to obstruct the coronary ostia but to give a valve structure close to the tubular form.

Implant Technique

The valve implantation was performed through a median sternotomy. Cardiopulmonary bypass (CPB) was conducted with the patient in moderate hypothermia (34°C), and myocardial protection was performed with antegrade intermittent blood cardioplegia. A transverse aortotomy was made approximately 2 cm above the sinotubular junction to insure ample space for attachment of commissural tabs below the suture line of the aortotomy. After excision of the native valve and decalcification, the annulus as well as the sinotubular junction were measured to reveal the appropriate size for the valve. In 3 patients the base cuff was implanted using interrupted mattress braided sutures because of severe calcification of the annulus. In the other patients the valves were implanted with three 4/0 prolene running sutures. These sutures were placed at the nadir of the cusps, then run in opposing directions until the subintercommissural area was reached and the sutures knotted at the outside of the aorta. Then the 3 commissural tabs were secured to the wall of the aorta with 3 transmural pledgeted sutures, 2 lateral vertical sutures, and 1 horizontal superior suture. Positioning of the 3 tabs has to be on 3 equidistant (120°) points straight above the commissural line (Figure).

Patients

The main inclusion criteria for the study were isolated aortic valve replacement with or without concomitant procedures, such as coronary artery bypass or another valve reconstruction, and willingness to return for regular follow-up to the implant center. Main study exclusion criteria were age younger than 20 years, major noncardiac or progressive disease with life expectancy below 12 months, pregnancy, intravenous drug abuse, implanted valve in other than an aortic position, active endocarditis, congenital bicuspid aortic anatomy, presence of a condition requiring mitral, tricuspid or pulmonic valve replacement, and participation in concomitant research studies. The protocol of this study was reviewed and approved at the University Hospital by the local ethical committee (approval No. 43/2002) in Berne. Informed consent for the implantation of the 3F aortic valve was obtained for all patients.

Between June 2001 and February 2004, 24 patients (14 men/10 women) underwent aortic valve replacement (AVR) with a 3F valve. The median (\pm SD) patient age was 72 \pm 13 years (range, 31 to 88 years). Left ventricular ejection fraction was 59.4% \pm 14.8% and EuroSCORE [Nashef 1999] was 6.8 \pm 2.5. Preoperative demographic data indicated a mean body mass index of 29 \pm 5.

The most common associated surgical pathologies were coronary artery disease in 12 patients (50%) and internal carotid stenoses in 3 patients (12.5%).

Follow-up

Follow-up study was conducted until March 2004. In addition to physical examination and standard blood tests patients were studied by standard transthoracic echocardiography at 30 days and 6 and 12 months postoperatively to determine valve function. The data are expressed as mean \pm SD.

Results

Prior to CPB carotid endarterectomy was performed in 3 patients. In 12 patients combined coronary revascularization was performed with 2.2 \pm 1.2 (n = 1-4) distal anastomoses; 1 patient received biatrial ablation therapy and 1 patient septal myectomy. When associated bypass grafting was required, distal coronary anastomoses were performed during rinsing time of the valve. All valves were implanted in a subcoronary intraannular position with continuous 4/0 polypropylene sutures, except 3 valves that were implanted supraannularly with interrupted 2/0 mattress braided sutures.

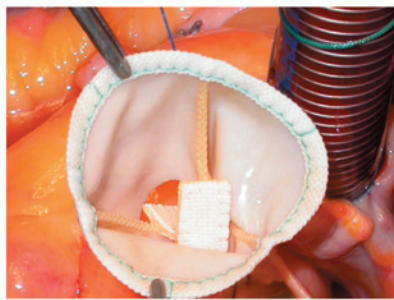
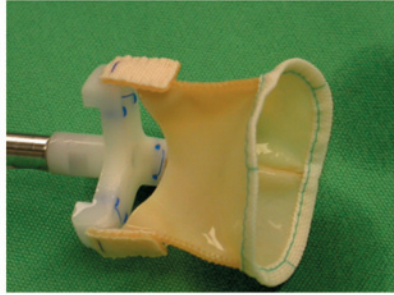
Cardiopulmonary bypass time was 102 \pm 32 minutes; aortic cross-clamp time was 79 \pm 24 minutes. Two patients died within 30 days. There was 1 non-valve-related death intraoperatively due to aortic rupture in an 83-year-old woman. After extensive decalcification of the aortic annulus down to the aortic valve, aortoventricular disconnection occurred, and low cardiac output after it was repaired made it impossible to wean the patient from CPB. One 77-year-old woman receiving low molecular weight heparin treatment suffered from cerebral embolism 5 days postoperatively. Although immediate catheter-based intervention occurred and aspiration and lysis of the thrombus in the anterior cerebral artery were performed, cerebral infarction led to fatal outcome in this patient. Postmortem examination suggested that the thrombus originated at one of the commissural tabs. During the midterm follow-up period a non-valve-related death due to pneumonia occurred 7 months postoperatively in another 77-year-old woman. Other postoperative complications were pacemaker implantation due to complete atrioventricular block in 1 patient, resolved intraoperative transient cerebral ischemia in 1 patient, and resolved transient cerebral ischemia due to hypertensive crises during follow-up in 1 patient.

Systolic gradients determined by echocardiography were 11.5 \pm 4.7 mm Hg at 30 days (n = 21), 11.4 \pm 4.5 mm Hg at 6 months (n=18), and 13.3 \pm 4.4 mm Hg at 12 months (n = 13). During follow-up all valves appeared normal, but trivial central aortic valve regurgitation was found in 6 patients. There was no structural valve failure, no endocarditis, and no need for reoperation.

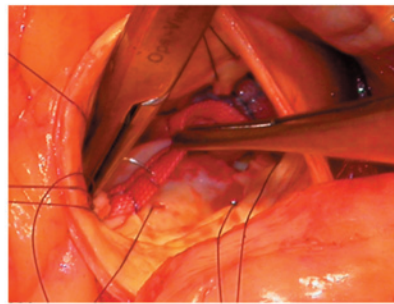
DISCUSSION

A stentless xenogeneic valve for the aortic position was first implanted in a patient in 1985 [Sievers 1985]. Although surgical risk might not have been increased using a stentless bioprosthesis [Westaby 2001], and studies have demonstrated superior hemodynamic features in terms of transvalvular pressure gradients and effective orifice area as well as more

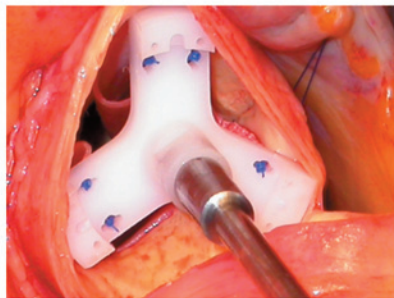
a)



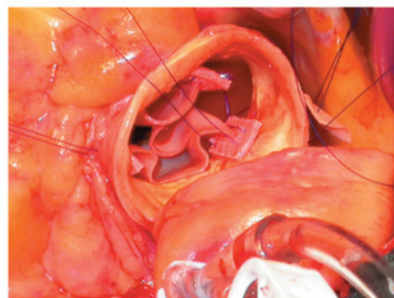
b)



c)



d)



e)

3F aortic valve implant technique. 3F aortic valve premounted on the holder (a). Valve invaginated prior to implantation (b) and inserted in the left cavum. The base cuff of the valve is sutured (c), and the 3 tabs are oriented at 120° degrees (d). The tabs are fixed with 3 sutures each and reinforced with a piece of pericardium at the outside of the aorta (e).

rapid and complete regression of left ventricular hypertrophy, stentless valves have yet to be adopted widely [Jin 2002].

Introducing a new biological heart valve into clinical use is challenging, especially when the valve has a completely new concept and design and is made of a new material. In vitro studies of the 3F valve have proven excellent hydrodynamics, durability, and biocompatibility testing, and chronic animal implants (n = 7150 days) have shown excellent results with extremely low rates of calcification in preclinical studies (unpublished data). Implantation of this valve in calves showed favorable in vivo results compared with standard stentless prostheses in the immediate postimplant period [Mueller

2003]. Excellent hydrodynamics with low stress on the valvular leaflets might have a positive impact on long-term survival of the valve, with low calcification rates. Equine pericardium was used in this version because it is very thin walled and more pliable than bovine pericardium. Equine pericardium has been used for connection of handmade extracardiac trileaflet conduits for pulmonary reconstruction in congenital heart disease [Imai 1995, Ando 1997]. Luciani et al [2000] reported satisfactory long-term survival and freedom from valve-related adverse events after stentless AVR in an elderly population (mean age, 70 ± 7 years). Echocardiographic gradients from the implanted valves are acceptably low and compa-

rable to other studies with pericardial stentless xenografts [Bonacchi 2002]. Although the 3F valve is available in sizes ranging from 19 to 29 mm in 2-mm steps, we have implanted only valves with a diameter from 23 to 29 mm and have therefore no data available from the 2 small-sized valves.

Despite the large coaptation line of the 3F valve, trivial aortic regurgitation (AR) was found in 6 patients. AR is a general problem after implantation of freehand stentless aortic valves [Jin 2001, Bonacchi 2002, Dellgren 2002, Kon 2002]. According to long-term follow-up data (eg, Toronto SPV valve study group), AR tends to occur with longer follow-up, larger valve sizes, and dilation of the sinotubular junction [Bach 2004] and might be accentuated in native porcine valves compared to constructed pericardial valves.

When implanting the 3F valve, the most comfortable technique was with running sutures. After a short training period, surgeons can perform implantation of the valve in less than 40 minutes of aortic cross-clamp time. Commissural tabs were fixed at the aorta at the beginning of the study with 2, and later with 3, monofilament sutures. The tabs should be placed at an appropriate distance to the aortic annulus and should correspond to the remnants of the natural commissures, to give valve structure to the tubular form.

The importance of geometric considerations such as commissural length in stentless valves has also been reported for porcine aortic valves [Sim 2003].

The design concept of the 3F stentless valve facilitates suturing and handling compared to other stentless valves and minimizes the risk of compromising the inflow to the coronary ostia. Before knotting all sutures, we placed a piece of bovine pericardium underneath to avoid cutting of the sutures in the aortic wall. All sutures were knotted at the outside of the aorta, avoiding possible damage resulting in a hole in the thin leaflets. During implantation, symmetry of the valve is important, whereas disregarding the 120° angle and the correct height of the attached commissural tabs might lead to high transvalvular gradients or may decrease significantly the length of the coaptation line between the 3 leaflets. Following one observed fatal event with cerebral embolism in a patient who received low molecular weight heparin subcutaneously in combination with acetylic acid only, we switched to very early and strict anticoagulation treatment for 3 months, the time it should take for healing at the Dacron of the sewing ring and the commissural tabs.

The 3 F aortic valve shows favorable preliminary hemodynamic results. Because of the new valve design, implantation technique is simplified compared with other stentless valves. Long-term evaluation and follow-up are mandatory to assess life span and durability.

REFERENCES

- Ando M, Imai Y, Takanashi Y, Hoshino S, Seo K, Terada M. 1997. Fate of trileaflet equine pericardial extracardiac conduit used for the correction of anomalies having pulmonic ventricle-pulmonary arterial discontinuity. *Ann Thorac Surg* 64(1):154-8.
- Bach DS, Goldman B, Verrier E, et al. 2004. Durability and prevalence of aortic regurgitation nine years after aortic valve replacement with the Toronto SPV stentless bioprosthesis. *J Heart Valve Dis* 13(1):64-72.
- Bonacchi M, Giunti G, Prifti E, et al. 2002. Early postoperative outcome and hemodynamic performance of the sorin pericarbon stentless aortic valve. *J Heart Valve Dis* 11(5):703-9.
- Dellgren G, Eriksson MJ, Brodin LA, Radegran K. 2002. Eleven years' experience with the Biocor stentless aortic bioprosthesis: clinical and hemodynamic follow-up with long-term relative survival rate. *Eur J Cardiothorac Surg* 22(6):912-21.
- Imai Y, Takanashi Y, Hoshino S, Nakata S. 1995. The equine pericardial valved conduit and current strategies for pulmonary reconstruction. *Semin Thorac Cardiovasc Surg* 7(3):157-61.
- Jin XY, Pepper JR. 2002. Do stentless valves make a difference? *Eur J Cardiothorac Surg* 22(1):95-100.
- Jin XY, Ratnatunga C, Pillai R. 2001. Performance of Edwards prima stentless aortic valve over eight years. *Semin Thorac Cardiovasc Surg* 13(4 suppl 1):163-7.
- Kon ND, Riley RD, Adair SM, Kitzman DW, Cordell AR. 2002. Eight-year results of aortic root replacement with the freestyle stentless porcine aortic root bioprosthesis. *Ann Thorac Surg* 73(6):1817-21.
- Luciani GB, Auriemma S, Casali G, Barozzi L, Lamascese N, Mazzucco A. 2000. Experience with stentless aortic xenografts. *J Heart Valve Dis* 9(6):794-800.
- Mueller XM, von Segesser LK. 2003. A new equine pericardial stentless valve. *J Thorac Cardiovasc Surg* 125(6):1405-11.
- Nashef SA, Roques F, Michel P, Gauducheau E, Lemeshow S, Salamon R. 1999. European System for cardiac operative risk evaluation (Euroscore). *Eur J Cardiothorac Surg* 16(1):9-13.
- Sievers HH, Lange PE, Bernhard A. 1985. Implantation of a xenogeneic stentless aortic bioprosthesis. First experience. *Thorac Cardiovasc Surg* 33(4):225-6.
- Sim EK, Muskawad S, Lim CS, et al. 2003. Comparison of human and porcine aortic valves. *Clin Anat* 16(3):193-6.
- Westaby S, Jonson A, Payne N, et al. 2001. Does the use of a stentless bioprosthesis increase surgical risk? *Semin Thorac Cardiovasc Surg* 13(4 suppl 1):143-7.

REVIEW AND COMMENTARY

CTT Reviewer Writes:

This paper reports the early clinical use of a new valve design created as a first stage to an endovascular valve replacement product. In these initial human cases, the results are somewhat disappointing in that 1 of the 24 patients suffered a device-related fatal stroke proven by autopsy (thrombus on one of the suture tabs). In addition, there remains a concern about the long-term fate of the "trivial central regurgitation" found in nearly 25% of implants. Although the authors state the 3F valve has a large coaptation line, their initial data suggest that the closure mechanism is not yet refined and reliable. The implications are that mild root dilation in the future may pull the commissures apart enough that clinically significant regurgitation can result, even without structural deterioration of the valve leaflets themselves. The long-term interaction of equine pericardium with human subjects is still not widely known. The outcome of pulmonary artery conduits in humans can-

not be directly equated to the performance of the same tissue in the aortic valve position where the stress forces are much higher.

Authors' Response by Dr. Friedrich S. Eckstein:

Our group was involved from the very beginning in the multicenter study. The initial results present also a learning curve in handling and implantation technique of this new

valve type that explains somewhat the reported rate of trivial central regurgitation. But, as stated in the manuscript, aortic regurgitation is a general problem after implantation of free-hand stentless aortic valves and should even be reduced in constructed pericardial valves with high profile and large coaptation area. Long-term follow-up has to prove this as well as the behavior and performance of equine pericardium in the aortic valve position.