

## Factors Influencing the Results of Double-Valve Surgery in Patients with Fulminant Endocarditis: The Importance of Valve Selection

Henryk Siniawski, MD, Onnen Grauhan, MD, PhD, Michael Hofmann, Miralem Pasic, MD, PhD, Yuguang Weng, MD, Charles Yankah, PhD, Hans Lehmkuhl, MD, Roland Hetzer, MD, PhD

Department of Cardiothoracic and Vascular Surgery, Deutsches Herzzentrum Berlin, Berlin, Germany

### ABSTRACT

**Background:** Extension of infection below the aortic valve is a serious complication, especially with mitral valve involvement. Mortality is substantial and reinfection can strongly influence outcome.

**Patients:** Of 327 surgical patients with active infective aortic valve endocarditis admitted to the Deutsches Herzzentrum Berlin for surgical treatment between December 1996 and December 2003, 108 had root abscess, and 53 (25.5%) had diagnoses of secondary infective mitral valve disease (SMVD). The mean age ( $\pm$ SD) was  $53 \pm 14.2$  years; there were 37 men and 16 women.

**Methods:** The secondary lesion on the mitral valve was classified as SMVD requiring double-valve surgery (DVS). This prospective clinical and echocardiographic study revealed 2 paths of infection extension into the mitral valve. In the DVS group, 38 patients (71.7%) had tissue metastatic lesions, and 15 patients (28.3%) had a jet lesion on the mitral valve. Most patients (42) with SMVD had an aortic ring abscess as the primary lesion.

**Results:** All patients with destructive endocarditic double-valve disease received aortic and mitral valve surgery. In 19 cases (35.8%), mitral valve reconstruction was undertaken; in 4 cases, mitral valve replacement had to be carried out after attempted mitral valve reconstruction. Concomitant mitral valve replacement because of severe damage to the valvular and subvalvular apparatus was performed in 30 patients (56.6%). Other types of surgery performed in 11 cases (20.8%) were 8 closures of a septic ventricular septal defect and 3 closures of a fistula to the right ventricle or right atrium. Twenty-seven patients were treated with a Shelhigh prosthesis, 18 were treated with double-valve replacement (both Shelhigh), and 9 were treated with an aortic Shelhigh

prosthesis and concomitant mitral valve reconstruction. Homografts were used in 17 patients, with mitral valve reconstruction carried out in 10 patients and a stented mitral prosthesis in 7. In 9 cases, 2 stented valve prostheses were used. There were 14 early (60 days) deaths (26.4%). Septic shock, severe annular and subannular destruction, and poor left ventricular function (end-diastolic dimension  $>65$  mm, ejection fraction  $<40\%$ ) were the significant risk factors determined in the multivariate analysis.

**Function of Implants: Continuous and Color Doppler Investigation:** Comparative studies of 2 different implants in the aortic position were performed late postoperatively (325  $\pm$  251 days) for homografts and the Shelhigh stentless prosthesis. The calculated instantaneous (maximal Doppler) gradient and the mean pressure gradient through the aortic implants were  $19 \pm 10.4$  mm Hg and  $12 \pm 5.7$  mm Hg, respectively, for the homografts and  $24 \pm 8.4$  mm Hg and  $15 \pm 4.6$  mm Hg, respectively, for the Shelhigh stentless prosthesis (not significantly different for the 2 groups). There was no mitral or aortic valve dysfunction. A trivial paravalvular leakage in the mitral position in 1 patient and a pseudoaneurysm of the left ventricular outflow tract without leakage or valvular dysfunction in another were diagnosed by postoperative Doppler investigation.

**Conclusions:** The mortality in patients with destructive endocarditis requiring DVS depends mostly on the patients' preoperative hemodynamic situation. The risk of reinfection can be minimized if valve substitutes are properly selected (homografts, Shelhigh No-React SuperStentless and No-React BioConduit in the aortic position, or Shelhigh BioMitral in the mitral position). Concomitant mitral valve reconstruction procedures do not increase the risk of mitral reinfection.

### INTRODUCTION

Native and prosthetic aortic valve endocarditis is very often complicated by infection extending to the aortic annulus and the periannular area [Sheldon 1951, Arnett 1976, Ergin 1989], forming aortic abscesses and carrying a higher mortality rate [Maisch 1989, Delay 2000, Netzer 2000]. This complication is very serious and is especially grave for patients when infection not only forms a localized abscess but also extends further and deeper into the surrounding tissue [Baumgarner 2000] involving the mitral valve. Hetzer et al

Presented at the 10th Annual CTT Meeting 2004, Miami Beach, Florida, USA, March 10-13, 2004.

Address correspondence and reprint requests to: Dr. Henryk Siniawski, MD, Department of Cardiothoracic and Vascular Surgery, Deutsches Herzzentrum Berlin, Augustenburger Platz 1, 13353 Berlin, Germany; 00-49-30-4593-2012; fax: 00-49-30-4593-1003 (e-mail: siniawski@dbzb.de).

stated that early detection, immediate surgery, and the proper selection of valves are imperative [Hetzer 1984].

Reinfection is the dominant postoperative complication [David 1996, Danchin 1999] leading to a high mortality rate. An adequate valve substitute [Kirklin 1988, Dearani 1997, Knosalla 2000, Carrel 2003] seems to be the key to breaking this vicious cycle, as we have documented in studies of patients with surgically treated aortic root abscess [Blumberg 1995]. In our practice, the valve substitute of choice in active infective aortic valve endocarditis with annulus abscess is the homograft in the aortic position [Knosalla 2000], followed by semistentless valves that do not contain prosthetic material and are specially treated with heparin. With the rule not to implant any prosthetic material in mind, the Shelhigh SuperStentless and Bio-Conduit (Shelhigh, Inc, Union, NJ, USA) were used as an alternative when no suitable homograft was available. For mitral valve surgery, mitral valve reconstruction is the optimal option, and the Shelhigh BioMitral prosthesis is the second possibility.

We studied a cohort of patients who had infective aortic valve endocarditis complicated by infection extension into the mitral valve requiring double-valve surgery (DVS) and who were treated with DVS according to our criteria.

The aim of this study was to assess the risk factors influencing mortality and to examine the early and late postoperative results of DVS for infection with the new Shelhigh implants in the aortic position or the aortic and mitral positions.

## METHODS

### Patients

Between December 1996 and December 2003, 327 surgical patients with active infective aortic valve endocarditis were admitted to the Deutsches Herzzentrum Berlin for surgical treatment. The patients came from all over Germany. Of 208 patients (63.6%) with aortic endocarditis, 108 had diagnoses of aortic root abscess. Of the patients with primary active infective aortic valve endocarditis, a secondary lesion on the mitral valve was found in 53 patients (25.5%). Such cases were classified as secondary infective mitral valve disease (SMVD) requiring DVS. The mean age ( $\pm$ SD) was 53  $\pm$  14.2 years; there were 37 men and 16 women.

### Echocardiography

Preoperative and postoperative echocardiographic examination (including the transesophageal mode of insertion) was performed with the commercially available Aloka 5.5 echocardiography machine (Aloka, Tokyo, Japan). The times of examination were as follows: preoperatively (on the day of operation, which in urgent cases was the day of admission), intraoperatively if the reconstruction procedure was undertaken, and on the day of discharge or if hemodynamic instability developed. Follow-up investigation was carried out routinely 6 months after the operation and was repeated 1 year later.

### Definitions

**Abscess.** An abscess was defined when an echo-dense or echo-lucent area visible by transesophageal echocar-

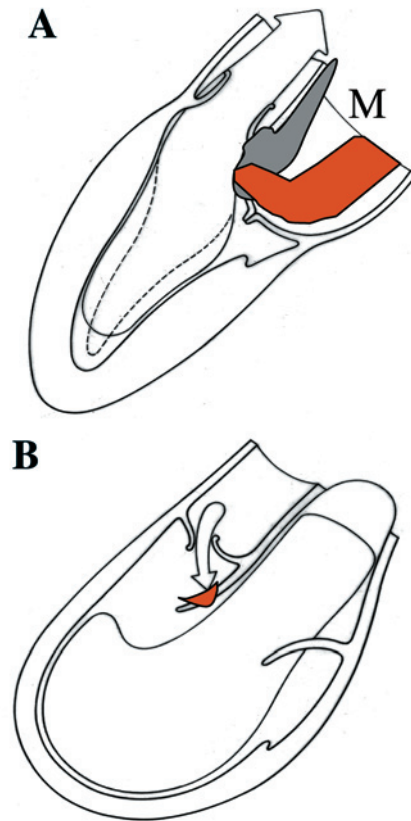


Figure 1. A, Local tissue metastasis to the mitral valve (M). Aortic annulus abscess (dark area) extends into the anterior and posterior area of the mitral annulus (red color), with annulus destruction producing mitral incompetence. B, Blood metastasis (jet lesion). Early phase of anterior mitral leaflet damage by jet lesion. Later on, severe mitral valve damage will progress. Mitral regurgitation due to enlargement of the left ventricle and mitral annulus dilatation that could be visualized with color flow Doppler were not included in this category. Typical complications of extended endocarditis, such as ventricular septal defect and fistulas, were diagnosed according to classic criteria.

diography was seen as a structure anatomically localized in the annulus.

**Aortoventricular Debiscence.** Aortoventricular dehiscence was defined as a separation (discontinuity) between the aorta and the left ventricle that was greater than half the circumference of the aortic annulus.

**Aortic Valve Endocarditis with SMVD.** Extension of the endocarditic lesion within the aortic root with mitral leaflet involvement was categorized as infective mitral valve disease secondary to aortic endocarditis. There were 2 distinguishable processes of infection extension in patients with SMVD. One is extension “per continuitatem” (the local metastatic form), which leads to severe destructive endocarditis extending below the aortic valve and enlargement of the infected area to include the mitral valve (Figure 1A). The second kind of extension is through infected blood stream jets of aortic regurgitation, which can produce injury of structures at the point where the jet reaches the

Table 1. Characteristics of Patient Group with Endocarditic Double-Valve Disease (n = 53)

Characteristics	Patients, n (%)
Abscess	42 (79.9)
Prosthetic endocarditis	18 (33.9)
Localized abscess	24 (57.1)
Aortic valve dehiscence and circular abscess	18 (42.8)
Septic ventricular septal defect	8 (15.1)
Severe heart failure	31 (58.5)
Vasopressors (septic shock)	14 (26.4)
<i>Staphylococcus aureus</i> infection*	24 (52.2)

\*In 46 patients (86.8%), microorganisms were identified perioperatively (46 as 100%).

ventricular side of the anterior mitral leaflets. Such a lesion is called a “jet lesion” (Figure 1B).

**Active Endocarditis.** Active endocarditis was diagnosed if the patient had positive results from blood cultures (prospective diagnosis) or valve cultures (postoperative diagnosis), signs of ongoing sepsis (epinephrine use with echocardiographic signs of endocarditis), or echocardiographically detected development of abscess, or if the patient experienced recurrent embolic events with echocardiographically demonstrated presence of vegetation.

The patients' characteristics are summarized in Table 1. Of the patients in the DVS group, 38 patients (71.7%) had metastatic tissue lesions (Figure 1A), and 15 patients (28.3%) had jet lesions on the mitral valve. Most (42) of the patients with SMVD had an aortic ring abscess as the primary lesion.

### Surgery and Indications for Surgery

The principal indications for DVS were aortic valve disease and SMVD, as described above. Cardioplegic arrest was achieved with antegrade cold crystalloid cardioplegic solution.

### Valve Substitutes

Aortic valve surgery was performed, and homografts, Shelhigh No-React SuperStentless valves (Figure 2), and the No-React BioConduit were the valve substitutes used. Shel-

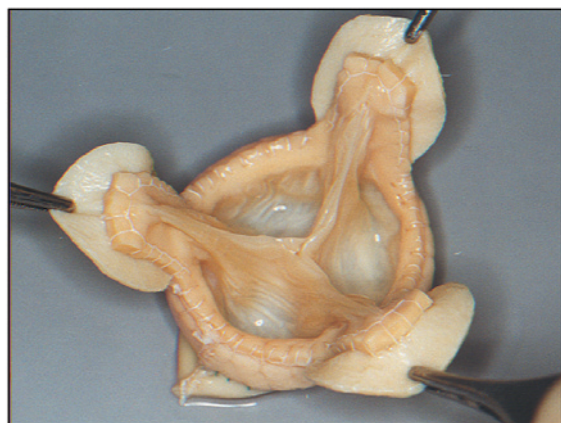

Figure 2. Shelhigh No-React-treated SuperStentless valve (outflow view).

high valves are devoid of any fabric material and are treated with glutaraldehyde and the No-React heparin-bonding process, which makes the glutaraldehyde-treated tissue become totally permanent and biocompatible [Abolhoda 1996]. Preliminary evaluations by the manufacturer show these valves to become covered with the patient's own endothelium in approximately 4 to 6 weeks. Studies in many centers are ongoing to confirm these results. If these findings of endothelium covering are confirmed, they will be a good explanation for why the reinfection rate is low.

Concomitant mitral valve surgery was performed, with preference given to mitral valve reconstruction. When reconstruction was not possible, the Shelhigh mitral valve prosthesis (BioMitral, Figure 3) was inserted. In only a minority of these cases were other mechanical or biological valve substitutes used in accordance with our policy of protection from reinfection (Table 2).

The data are expressed as the mean  $\pm$  SD. The function of homografts and the Shelhigh prostheses as implants in the aortic position was investigated. The differences between groups were analyzed by means of the Student *t* test. Multivariate analysis for the whole group with abscess was performed to identify any independent factors influencing mortality.

### Statistical Analysis

Values are reported as the percentage or the mean  $\pm$  SD as appropriate. For the identification of prognostic factors influencing mortality, univariate logistic regression analysis was performed with the odds ratio and a 95% confidence interval (CI). Included variables thought to have clinical importance were age, preoperative and postoperative ejection fraction, left ventricular end-diastolic dimension, vasopressor use, sex, causative bacteria, and severe destruction of the valvular and subvalvular apparatus.

## RESULTS

### Characteristics

Two different paths of infection extension into the mitral valve were distinguished by echocardiography. Infection extension was by local metastasis in 38 patients (71.7%) and by blood stream metastasis (usually jet lesion at the anterior mitral leaflet or chordae) in 15 patients (28.3%). Severe heart failure (pulmonary congestion in radiographs and clinical evidence of left ventricular failure, auscultative pulmonary rales, presence of gallop rhythm, and tachycardia) was present in 31 patients (58.5%). Vasopressors were used in 14 patients to maintain blood pressure at an adequate level. These patients had septic shock symptoms preoperatively. Of the patients who had diagnoses of annular abscess (n = 42), 24 patients (57.1%) were classified as having localized abscess, and 18 patients (42.8%) had severe destruction of heart structures diagnosed as circular abscess or aortoventricular dehiscence (Table 1).

### Microorganisms

Microorganisms were selected and characterized in 46 patients (86.8%). The number of patients with detected staphy-

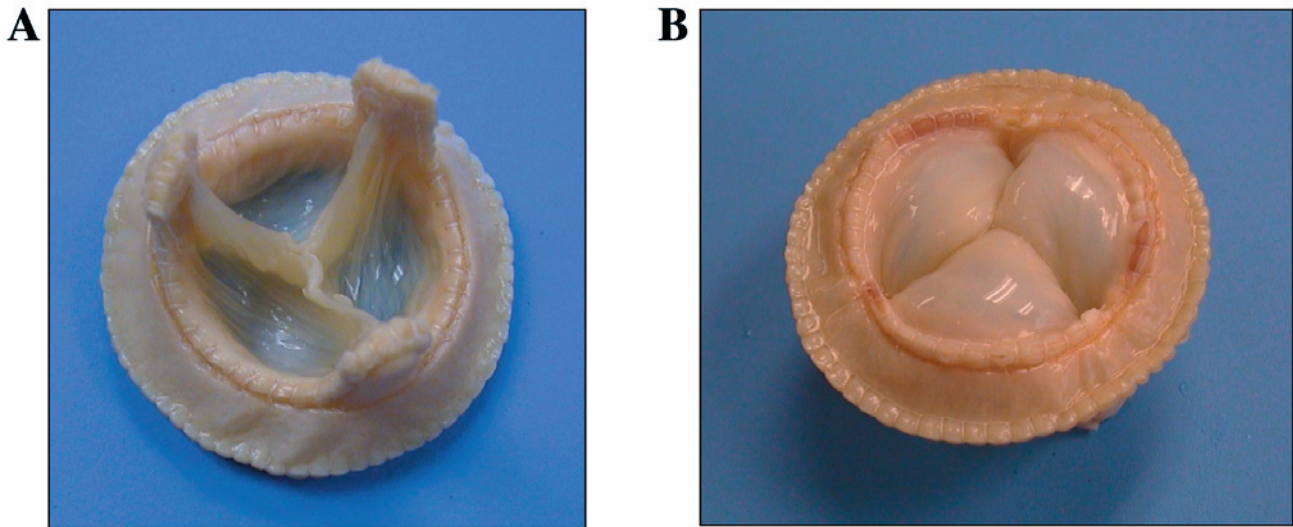


Figure 3. Shelhigh No-React-treated BioMitral valve. Outflow (A) and inflow (B) views.

lococcal infections was relatively high (24, 52.2%) for the study group (Table 1). Antibiotic medication was directed specifically at the cultured organism, if it was known. If the organism was not known, a broad-spectrum antibiotic was used.

**Surgery**

All of the patients with destructive endocarditic double-valve disease received aortic and mitral valve surgery (Table 2). In 19 cases (35.8%), mitral valve reconstruction was undertaken, and in 4 cases mitral valve replacement had to be carried out following attempted mitral valve reconstruction because intraoperative echocardiography had demonstrated inadequate results. Altogether, mitral valve replacement because of severe damage to the valvular and subvalvular apparatus was necessary in 30 patients (56.6%).

Table 2. In-Hospital Mortality and Reinfection in Patient Study Group\*

Type of Surgery	Patients, n (%)	Reinfection, n (%)	Mortality, n (%)
All (AV and MV surgery)	53 (100)	5 (9.4)	14 (26.4)
Shelhigh (all)	27 (50.1)	1 (3.7)	7 (25.9)
AVP + MVP	18 (34)	1 (5.0)	5
AVP + MVRec	9 (17.0)	0	2
Homograft (all)	17	1 (5.8)	5 (29.4)
MVP (only 3 stented)†	7	1 (14.3)	2
MVRec	10	0	3
Mechanical and biological stented valves (AV and MV)	9 (23.7)	3 (33.3)	2 (22.2)

\*AV indicates aortic valve; MV, mitral valve; Shelhigh, Shelhigh No-React SuperStentless and No-React BioConduit in the aortic position or Shelhigh BioMitral in the mitral position; AVP, aortic valve replacement (prosthesis); MVP, mitral valve replacement (prosthesis); MVRec, mitral valve reconstruction.

†Infected stented valve in the mitral position.

Other types of surgery had to be performed in 11 patients (20.8%). Septic ventricular septal defect closure was carried out in 8 patients, and closure of a fistula to the right ventricle and right atrium was carried out in 3 patients. Twenty-seven patients were treated with a Shelhigh prosthesis. A double-valve prosthesis was used in 18 patients, and mitral valve reconstruction was performed in 9 patients. Homografts were used in 17 patients, with mitral valve reconstruction in 10 patients and a stented mitral prosthesis in 7 patients. In 9 cases, double-stented valve prostheses were used.

**Hospital Mortality and Morbidity**

There were 14 cases (26.4%) of early deaths (60 days). In the Shelhigh group with No-React SuperStentless or No-React BioConduit in the aortic position and with Shelhigh BioMitral or mitral valve reconstruction, 7 patients (25.9%) died early after double-valve replacement (Table 2); none died later. The causes of death were myocardial failure in 12 cases and septic shock resistant to treatment in 2 cases.

Five patients (9.4%) had reinfections requiring reoperation. One patient (3.7%) was in the Shelhigh group (double-valve replacement), 1 patient (5.8%) had an aortic valve homograft and mitral replacement with a stented valve, and 3 patients (33%) had a double-valve replacement with stented valves. No reinfection was noted after homograft and Shelhigh aortic valve replacement with concomitant mitral valve reconstruction.

**Function of Implants: Continuous and Color Doppler Investigation**

In the late postoperative period (325 ± 251 days), comparative studies were performed of 2 different implants in the aortic position: homografts and the Shelhigh stentless prosthesis. The calculated instantaneous (maximal Doppler) gradient and the mean pressure gradient through the aortic implants were 19 ± 10.4 mm Hg and 12 ± 5.7 mm Hg, respectively, for homografts and 24 ± 8.4 mm Hg and 15 ± 4.6 mm Hg,

Table 3. Doppler Gradient Chart\*

	Shelhigh Aortic Bioprostheses	Homografts	Shelhigh BioMitral	Mitral Valve Replacement
Mean Doppler pressure, mmHg	15 ± 4.6	12 ± 5.7	2.4 ± 1.4	2.2 ± 1.1
P	NS	NS	NS	NS

\*Data are presented as the mean ± SD. NS indicates not statistically significant.

respectively, for the Shelhigh stentless prosthesis (differences for the 2 groups not statistically significant; Table 3). There was no mitral or aortic valve dysfunction. Trivial paravalvular leakage in the mitral position was diagnosed postoperatively in 1 patient, and a pseudoaneurysm of the left ventricular outflow tract without leakage or valvular dysfunction apparent in Doppler studies was diagnosed postoperatively in another.

Left ventricular function was assessed postoperatively, and these results were compared with preoperative values (Table 4). The left ventricular end-diastolic dimension was not significantly smaller postoperatively (59 ± 14 mm versus 55 ± 11 mm). The left ventricular ejection fraction also was not significantly better postoperatively (54% ± 14% versus 56% ± 12%).

Risk factors were calculated for all surgical patients with abscess (n = 108) (Table 5). Vasopressor use (septic shock), severe annular and subannular destruction, and poor left ventricle function (end-diastolic dimension >65 mm, ejection fraction <40%) were significant risk factors. Interestingly, female sex was an important risk factor, and aggressive bacterial infection was not (Table 5).

## DISCUSSION

The present study has examined the problem of the surgical treatment of infective double-valve disease (Table 1). There is little information about the surgical results in groups of such severely ill patients. This study focused on very high-risk patients with infection extension not only below the aortic valve but also extending to the mitral valve. Our cohort of patients was seriously ill because one fourth experienced shock, a large number (31, 58.5%) had signs of left heart failure, and more than two thirds had aortic root abscess. The overall mortality rate was 26.4% (14 of 53 patients) (Tables 2 and 5). Factors showed that the patients were admitted to hospital for surgery at a late stage and in poor hemodynamic condition (Table 1). Independent risk factors for death were defined (Table 5). Shock was defined as

Table 4. Preoperative and Postoperative Echocardiographic Data of 14 Patients: Late Postoperative Investigation of the Shelhigh Group (n = 14)\*

	End-Diastolic Dimension, mm	P	Ejection Fraction, %	P
Preoperative	59 ± 14	NS	54 ± 14	NS
Postoperative	55 ± 11		56 ± 12	

\*Data are presented as the mean ± SD. NS indicates not significantly different.

vasopressor use, and with an odds ratio of 3.44 (CI, 0.85-13.9;  $P = .007$ ), this factor had the strongest positive influence on the mortality rate. Other important factors influencing the risk of death were a poor ejection fraction (<40%) preoperatively and postoperatively and a dilated left chamber (>65 mm). These findings mean that patients with preoperative use of vasopressors, with left heart failure and severe regurgitation, and with a low ejection fraction were at greater risk of death than patients who did not demonstrate such unfavorable hemodynamic signs (Table 5).

### Timing of Surgery

Our results indicate that surgery in patients with endocarditic double-valve disease is a matter of urgency. If the patients had reached the operating room earlier, they would possibly have had a better chance of survival after single aortic valve replacement. This conclusion means that mitral valve replacement could have been avoided for many of these patients if they had been admitted for surgery earlier.

We also tested the hypothesis that reinfection depends mostly on the type of valve substitute used. Prostheses that do not contain artificial fabric material (polyester) and that have glutaraldehyde-fixed tissue bonded with heparin (No-React treated) seem to offer special resistance to bacterial infection. Our previous and positive experience with Shelhigh

Table 5. Factors Influencing Mortality: Multivariate Analysis of 108 Patients with Ring Abscess

Predictors	Odds Ratio	95% CI	P
Vasopressor use, preoperative*	3.44	0.85-13.9	.07
Vasopressor use, postoperative*	4.74	1.55-14.8	.004
Female sex	5.14	1.45-18.2	.007
Destruction of annulus and subvalvular apparatus†	4.65	1.22-17.1	.0159
Ejection fraction, preoperative‡	2.5	1.04-1.20	.0027
Ejection fraction, postoperative‡	2.7	1.02-1.14	.074
End-diastolic dimension, postoperative§	2.0	1.14-1.22	.0007
<i>Staphylococcus aureus</i> infection	1.00	0.71-1.53	.3
<i>Streptococcus</i> infection	1.00	0.31-2.49	.4

\*Vasopressor use indicates presence of septic shock.

†Destruction of annulus and subvalvular apparatus is defined as double surgery in presence of aortic valve dehiscence and destruction of mitral annulus and subvalvular apparatus.

‡Low ejection fraction, less than 40%.

§Echocardiographically assessed left ventricular cavity larger than 65 mm in diastole.

implants reported earlier [Siniawski 2003], is documented in this series. Only 1 patient (3.7%) had reinfection requiring reoperation (successful). These results are very promising despite the small cohort of patients (27 cases with Shelhigh implants) (Table 2).

### Types of Aortic and Mitral Valve Surgery

Most patients were treated with a homograft or the Shelhigh No-React SuperStentless and the Stentless Aortic Valved BioConduit as an alternative. Our experience, as well as that of others, shows the reinfection rate to be lower for the homograft or the Shelhigh prosthesis than after aortic valve replacement using standard prostheses [Kirklin 1988, Knosalla 2000, Siniawski 2003].

Mitral valve reconstruction was performed when possible, but when destruction of the mitral annulus and subvalvular apparatus was present, such reconstruction was often not possible. The severity of the destruction of the tissue and of the subvalvular mitral apparatus had great influence on the manner of surgery and possibly influenced the outcome in the DVS groups. In the multivariate analysis, DVS was an independent risk factor for death when metastatic annulus destruction was defined (odds ratio, 4.65; CI 1.22-17.1;  $P = .02$ ). Blood metastatic destruction (jet lesion) was not found to be a risk factor in the multivariate analysis.

Other factors influenced mortality in the multivariate analysis of the 108 patients with root abscess (Table 5). Female sex (odds ratio, 5.14; CI, 1.45-18.2;  $P = .007$ ) was an independent factor that positively influenced mortality. The explanation was not found in this series. It is interesting that virulent microorganisms were not defined as an independent risk factor for death in the group of patients studied.

### CONCLUSIONS

Mortality in infective DVS depends on the hemodynamic condition of the patients. Severe destruction of the annular and subvalvular tissue causes higher early mortality rates. Patients with signs of root abscess or jet lesion should receive early surgical treatment to avoid excessive surgery (including DVS). If recognized early, extension of infection into the mitral valve can be treated by mitral valve reconstruction surgery with good results and with no reinfection.

DVS with polyethylene terephthalate (Dacron)-free Shelhigh No-React-treated aortic and mitral valve prostheses is associated with a favorable outcome, a low rate of reinfection, and very good hemodynamic function.

### ACKNOWLEDGMENT

We would like to thank Anne Gale of the Deutsches Herzzentrum Berlin for her editorial assistance.

### REFERENCES

- Abolhoda A, Yu S, Oyarzun JR, et al. 1996. No-React detoxification process: a superior anticalcification method for bioprostheses. *Ann Thorac Surg* 62:1724-30.
- Arnett EN, Roberts WC. 1976. Valve ring abscess in active infective endocarditis. *Circulation* 54:140-5.
- Baumgartner FJ, Omari BO, Robertson JM, Nelson JR, Pandya A, Miliken JC. 2000. Annular abscess in surgical endocarditis: anatomic, clinical and operative features. *Ann Thorac Surg* 70:442-7.
- Blumberg EA, Karalis DA, Chandrasekaran K, et al. 1995. Endocarditis associated paravalvular abscess: do clinical parameters predict presence of abscess? *Chest* 107:898-903.
- Carrel TP, Berdat P, Engleberger L, et al. 2003. Aortic root replacement with a new stentless aortic valve xenograft conduit: preliminary hemodynamic and clinical results. *J Heart Valve Dis* 12:752-7.
- Danchin N, Cherrier F. 1999. Comparison of long-term outcome in patients with or without aortic ring abscess treated surgically for aortic valve infective endocarditis. *Heart* 81:177-81.
- David TE, Feindel CM, Armstrong S, Sun Z. 1996. Long-term results of operation for paravalvular abscess. *Ann Thorac Surg* 62:48-53.
- Dearani JA, Orszulak TA, Schaff HV, Daly RC, Anderson BJ, Danielson GK. 1997. Results of allograft aortic valve replacement for complex endocarditis. *J Thorac Cardiovasc Surg* 113:287-91.
- Delay D, Pellerin M, Carrier M, et al. 2000. Immediate and long-term results of valve replacement for native and prosthetic valve endocarditis. *Ann Thorac Surg* 70:1219-23.
- Ergin MA, Raissi S, Follis F, Lansman SL, Griep RB. 1989. Annular destruction in acute bacterial endocarditis. *J Thorac Cardiovasc Surg* 97:755-63.
- Hetzer R, Deyerling W, Borst HG. 1984. Herzklappenchirurgie bei aktiver infektiöser Endokarditis. In: *Infektiöser Endokarditis. Klinik, Diagnostik und Therapie*. Darmstadt, Germany: Steinkopff-Verlag. p 148-76.
- Kirklin JK, Kirklin JW, Pacifico AD. 1988. Aortic valve endocarditis with aortic root abscess cavity: surgical treatment with aortic valve homograft. *Ann Thorac Surg* 45:674-7.
- Knosalla C, Weng Y, Yankah AC, et al. 2000. Surgical treatment of active infective aortic valve endocarditis with associated periannular abscess: 13 year results. *Eur Heart J* 21:490-7.
- Maisch B. 1989. Klinik der infektiösen Endokarditis. *Internist (Berl)* 30:483-91.
- Netzer RO, Zollinger E, Seiler C, Cerny A. 2000. Infective endocarditis: clinical spectrum, presentation and outcome. An analysis of 212 cases 1980-1995. *Heart* 84:25-30.
- Sheldon WH, Golden A. 1951. Abscesses of the valve rings of the heart: a frequent but not well recognized complication of acute bacterial endocarditis. *Circulation* 4:1-12.
- Siniawski H, Lehmkühl H, Weng Y, et al. 2003. Stentless aortic valves as an alternative to homografts for valve replacement in active infective endocarditis complicated by ring abscess. *Ann Thorac Surg* 75:803-8.