

Infective Endocarditis during Pregnancy: Case Report

Nyawo B,¹ Shoaib RF,¹ Evemy K,² Clark SC¹

Departments of ¹Cardiothoracic Surgery and ²Cardiology, Freeman Hospital, Newcastle upon Tyne, U.K.

ABSTRACT

A 29-year-old woman was transferred at 31 weeks gestation for management of infective endocarditis (IE). Echocardiography demonstrated vegetations on aortic valve and severe mitral regurgitation. Blood cultures were positive for *Streptococcus sanguis*. Due to impending hemodynamic collapse, a cesarean section was performed followed by aortic valve replacement and mitral valve repair with a patch of bovine pericardium. At 10-month review, both mother and baby are doing well.

INTRODUCTION

The incidence of infective endocarditis (IE) during pregnancy has been reported to be 0.006% [Cox 1998], or 1 in 8000 deliveries (0.0125%) [Nazarian 1976]. According to a recent collective study, the calculated maternal and fetal mortality rates were 22.1% and 14.7%, respectively [Campuzano 2003]. Heart disease is the most important nonobstetric cause of maternal death during pregnancy, accounting for 10% of maternal deaths [Montoya 2003]. Although there have been several reports of IE during pregnancy [Sexton 1985; Kangazari 2000], there is little in the literature on the management of pregnancy complicated by IE. In this paper, we report a case of acute aortic and mitral regurgitation resulting from IE occurring in a pregnant woman and discuss the clinical management.

CASE REPORT

A 29-year-old woman, 31 weeks pregnant, was admitted for management of IE affecting both aortic and mitral valves. The pregnancy had been uncomplicated up to 31 weeks. She complained of intermittent fever, general malaise, dyspnea, and ankle swelling. Her past history was not significant for congenital and valvular abnormalities. She was initially treated with cephalexin for a presumed urinary tract infection until a diagnosis of IE was made. Ten days later, ejection systolic and diastolic murmurs were first noticed, and her condition had

become much worse with incipient circulatory collapse. Ultrasound examination revealed a fetus in vertex presentation (Figure 1).

Echocardiography showed massive atrial regurgitation (AR) and mitral regurgitation (MR) (Figure 2) due to perforation of the anterior valve leaflet with vegetations on both leaflets. Blood cultures were positive for *Streptococcus sanguis*. Because her condition was critical, surgical intervention was the only option. After induction of anesthesia, a cesarean section was performed, and a female baby was delivered uneventfully. The baby was resuscitated but did not require mechanical ventilation and was in good condition. The uterus and abdominal wall were left open until full heparinization and cardiopulmonary bypass had been established. The aortic valve was replaced with a size 21 mm Carbomedics supra-annular "Top Hat" mechanical prosthesis (Carbomedics, Austin, TX, USA). The anterior mitral valve leaflet was debrided of vegetation, and the perforation was repaired with a patch of bovine pericardium. Cardiopulmonary bypass was discontinued with minimal inotropic support.

The mother's postoperative recovery was uncomplicated, and both she and baby were discharged at 8 days. 10 months later, the patient is well and has a healthy baby.

DISCUSSION

IE is a rare but life-threatening complication of pregnancy. Over the past 3 decades, however, improved medical and surgical management of pregnant patients with heart disease has greatly reduced the maternal and fetal mortality rates, and the most recent collective study has indicated overall

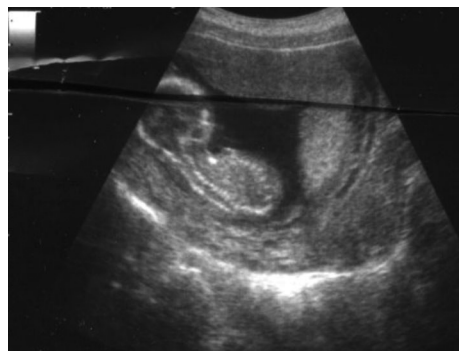


Figure 1. Ultrasound of baby.

Received May 26, 2007; received in revised form August 2, 2007; accepted August 12, 2007.

Correspondence: Dr. RF Shoaib, Department of General Surgery, Lister Hospital, Stevenage, UK, SG1 4AB (e-mail: shoaibrf@hotmail.com).




Figure 2. Intraoperative transoesophageal echocardiogram showing atrial (A) and mitral (B) regurgitation.

maternal and fetal mortality rates of 22.1% and 14.7%, respectively [Campuzano 2003]. To minimize the maternal and fetal risks, the first choice of treatment should be medical; however, in cases that are refractory to medical treatment, corrective cardiac operations are unavoidable. In patients with incipient circulatory collapse, as in this case, surgical intervention is the only option. Although some cases of successful open-heart operations with cardiopulmonary bypass (CPB) have been reported [Becker 1983], congenital malformations possibly resulting from drug administration and CPB have been common when CPB is performed during the first trimester [Zitnik 1969; Lapedra 1986]. Considering these facts, cardiac operations are not recommended except in extreme emergencies during the first 2 trimesters [Parry 1996]. On the other hand, since a report by Zitnik and colleagues [1969], many reports of fetal survival to term after operations with CPB performed in the second and third trimesters, particularly between 24 and 28 weeks of gestation, have been described [Mahli 2000]. Furthermore, recent improvements in neonatal care have improved the survival of premature infants of greater than 28 weeks gestation. Some authors recommend elective delivery by cesarean section just before CPB (after heparinization and cannulation of the mother but before commencing CPB) in the third trimester to minimize maternal and fetal risks [Parry 1996]. In our case, cesarean section was performed prior to heparinization. Full heparinization was achieved before closure of the cesarean section. The uterus was then closed after CPB had been established. In this way, we made sure that there were no bleeding points even after full heparinization. No excessive uterine hemorrhage occurred at any stage after surgery. Mitral valve repair in infective endocarditis has been well reported [Dreyfus 1990; Sternik 2002]. Sternik and colleagues [2002] have shown that mitral valve repair in IE has a significantly lower risk of in-hospital mortality. Dreyfus and colleagues [1990] find no recurrence of IE following MV repair.

In summary, we experienced active aortic and mitral valve IE occurring in a pregnant woman and performed a successful cesarean section, aortic valve replacement, and mitral valve repair.

REFERENCES

- Becker RM. 1983. Intracardiac surgery in pregnant women. *Ann Thorac Surg* 36:453-8.
- Campuzano K, Roqué H, Bolnick A, Leo MV, Campbell WA. 2003. Bacterial endocarditis complicating pregnancy: case report and systematic review of the literature. *Arch Gynecol Obstet* 268:251-5.
- Cox SM, Hankins GD, Leveno KJ, Cunningham FG. 1988. Bacterial endocarditis: a serious pregnancy complication. *J Reprod Med*; 33:671-4.
- Dreyfus G, Serraf A, Jebara VA, et al. 1990. Valve repair in acute endocarditis. *Ann Thorac Surg* 49:706-13.
- Kangavari S, Collins J, Cercek B, Atar S, Siegel R. 2000. Tricuspid valve group B streptococcal endocarditis after an elective termination of pregnancy. *Clin Cardiol* 23:301-3.
- Lapedra OJ, Bernal JM, Ninot S, Gonzalez I, Pastor E, Miralles PJ. 1986. Open heart surgery for thrombosis of a prosthetic mitral valve during pregnancy: fetal hydrocephalus. *J Cardiovasc Surg (Torino)* 27:217-20.
- Mahli A, Izdes S, Coskun D. 2000. Cardiac operations during pregnancy: review of factors influencing fetal outcome. *Ann Thorac Surg* 69:1622-6.
- Montoya ME, Karnath BM, Ahmad M. 2003. Endocarditis during pregnancy. *South Med J* 96:1156-7.
- Nazarian M, McCullough GH, Fielder DL. 1976. Bacterial endocarditis in pregnancy: successful surgical correction. *J Thorac Cardiovasc Surg* 71:880-3.
- Parry AJ, Westaby S. 1996. Cardiopulmonary bypass during pregnancy. *Ann Thorac Surg* 61:1865-9.
- Podesser BK, Rödler S, Hahn R, et al. 2000. Mid-term follow up of mitral valve reconstruction due to active infective endocarditis. *J Heart Valve Dis* 9:335-40.
- Sexton DJ, Rockson SG, Hempling RE, Cathey CW. 1985. Pregnancy-associated group B streptococcal endocarditis: a report of two fatal cases. *Obstet Gynecol* 66(3 Suppl):44S-7S.
- Sternik L, Zehr KJ, Orszulak TA, Mullany CJ, Daly RC, Schaff HV. 2002. The advantage of repair of mitral valve in acute endocarditis. *J Heart Valve Dis* 11:91-7.
- Zitnik RS, Brandenburg RO, Sheldon R, Wallace RB. 1969. Pregnancy and open-heart surgery. *Circulation* 39(5 Suppl 1):157-62.