

Active Perfusion of Coronary Grafts Facilitates Complex Off-Pump Coronary Artery Bypass Surgery

(#2000-3759 ... July 21, 2000)

John D. Puskas, MD, MSc, Vinod H. Thourani, MD,
Jakob Vinten-Johansen, PhD and Robert A. Guyton, MD

Division of Cardiothoracic Surgery, Department of Surgery, The Carlyle Fraser Heart Center, Crawford Long Hospital of Emory University, Atlanta, GA 30365



Dr. Puskas

ABSTRACT

Background: Hemodynamic stability during cardiac manipulation for complex, multivessel off-pump coronary artery bypass grafting (OPCAB) remains problematic.

Methods: A servo-controlled pump has been utilized to deliver warm whole blood to coronary grafts prior to construction of proximal anastomoses.

Results: This technique may avoid detrimental hemodynamic decompensation, which may accompany regional coronary ischemia during cardiac displacement. It may also allow precise infusion of supplemental additives leading to coronary vasodilatation, myocardial resuscitation, and enhancement of myocardial contractility.

Conclusion: In this report, three complex OPCAB cases are described which were successfully performed with active graft perfusion and which might not otherwise have been technically feasible by conventional OPCAB techniques.

INTRODUCTION

Multivessel coronary artery bypass grafting without the use of extracorporeal circulation has enjoyed a recent renaissance in interest. Improvements in exposure techniques, including pericardial traction sutures and slings, and a better understanding of the hemodynamic impact of cardiac manipulation have allowed broader application of multivessel off-pump coronary artery bypass (OPCAB) [Puskas 1999]. Nonetheless, hemodynamic deterioration may still occur in some cases during cardiac retraction and

stabilization. Cumulative regional impairment caused by sequential occlusion of multiple coronary target vessels may lead to cardiac failure. Strategies to decrease ischemic impairment and promote early recovery of each grafted myocardial region have included the use of intraluminal stents, arterial shunts, and "proximal first" grafting strategies. While grafting the left anterior descending (LAD) coronary artery first with an in situ internal mammary artery may provide immediate inflow to the ischemic heart, this is not always technically feasible or facile. Subsequent retraction for exposure of obtuse marginal targets may produce unacceptable tension on the internal mammary artery pedicle and jeopardize the LAD anastomosis.

We have recently reported an adjunctive technology in multivessel OPCAB that promotes early reperfusion and rapid recovery of each grafted myocardial region [Guyton 2000]. After completion of the saphenous vein and/or radial artery distal anastomoses, arterial blood is removed from the aorta and infused into the target distal myocardial bed. A servo-controlled pump allows pressure control at systemic or suprasystemic levels, while computer-controlled additive circuits allow the simultaneous infusion of pharmacologic agents for myocardial resuscitation, vascular dilatation, and/or enhancement of myocardial performance (Figure 1, ⊙). This is the second clinical report of the use of this system for OPCAB. Three such cases performed by a single surgeon (Puskas) are herein described.

MATERIALS AND METHODS

Perfusion-assisted direct coronary artery bypass (PAD-CAB) utilizes a simple circuit and a computer controlled delivery system [Sydzyk 1997]. Standard median sternotomy and vein harvesting techniques were utilized. Prior to division of the internal mammary artery, 2 mg/kg of heparin sodium were administered. Additional heparin was given during the procedure to maintain an activated clot-

Submitted July 18, 2000; accepted July 21, 2000.

Address correspondence and reprint request to: John D. Puskas, MD, MSc, 550 Peachtree Street, NE, Suite 7700, Crawford Long Hospital, Emory University of School of Medicine, Atlanta, GA 30365, Phone: (404) 686-2513, Fax: (404) 686-4959, Email: jpuskas@emory.edu

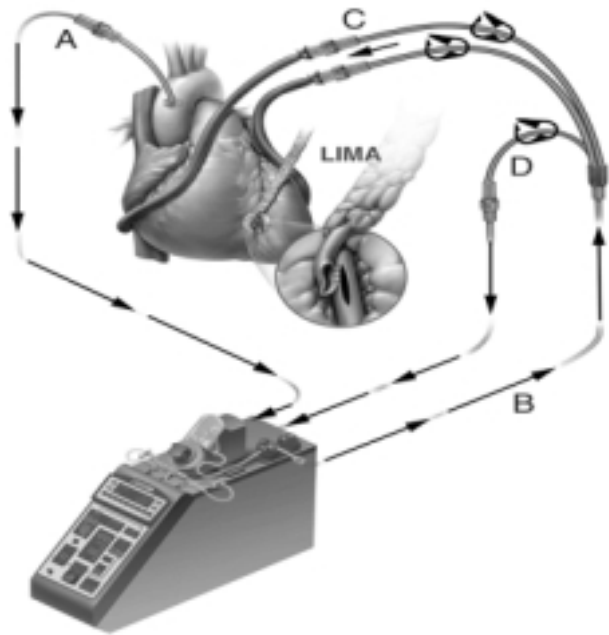


Figure 1. Perfusion-assisted direct coronary bypass system. Aortic blood is directed from the aortic cannula (A) through the Quest MPS to the multiple perfusion set (B), and finally the proximal vein or arterial grafts (C). The vein infusion pressure is monitored by the MPS system from a feedback line (D) located at the proximal portion of the multiple perfusion set.

ting time (ACT) greater than 350 seconds. Arterial inflow to the myocardial protection system (MPS, Quest Medical, Inc., Allen, TX) was provided via a DLP aortic root catheter (9 gauge, 11 French, Medtronic DLP, Grand Rapids, MI) inserted into a non-diseased site on the ascending aorta or via a percutaneous catheter inserted into the right femoral artery. The MPS delivery system allows monitoring of delivery line pressure (mmHg), vein graft infusion pressure (mmHg) and flow (milliliters per minute).

The choice of graft sequence may be critical to success in multivessel OPCAB. The first graft performed is ideally a saphenous vein graft to a coronary artery of reasonable size with either tight or complete proximal stenosis, that does not require extreme retraction for access. A mechanical stabilizer (Medtronic Octopus II, Medtronic, Minneapolis, MN) was used for stabilization of each coronary target. A humidified, sterile, carbon dioxide blower was used to clear the surgical field of blood from the arteriotomy (Medtronic DLP, Grand Rapids, MI). Coronary targets were occluded proximally with a silastic vessel loop (Quest Medical, Inc., Allen, TX) as necessary. After completion of the distal anastomosis, the proximal end of the saphenous vein graft was connected to the outflow of the MPS system, and warm blood was administered using a multiple perfusion set (Medtronic DLP, Grand Rapids, MI). Each subsequent graft was connected to the multiple perfusion set after completion of the distal anastomosis. The left internal mammary artery (LIMA) was anastomosed to the left anterior descending coronary

artery after completion of all saphenous vein distal anastomoses. This allowed optimal evaluation of LIMA pedicle and SVG lengths and optimal choice of grafting site on the left anterior descending coronary artery. Proximal anastomoses of saphenous vein grafts were then performed to the ascending aorta utilizing a partial occlusion clamp. Protamine sulfate was administered in a half-reversal dose (0.75-1.0 mg/kg) prior to chest closure and the ACT was reduced to approximately 150 seconds. The DLP cannula was removed from the aorta or a percutaneous catheter removed from the right femoral artery in standard fashion.

Case 1

A 65-year-old gentleman on chronic home oxygen therapy for chronic obstructive pulmonary disease (COPD), who was status post coronary artery bypass grafting in 1984 and 1987, presented with an acute inferior myocardial infarction in September 1999 and was initially treated with tissue plasminogen activator. Cardiac catheterization revealed complete occlusion of all native coronary arteries. Of the various grafts, the LIMA pedicle to the first diagonal was open, filling a small coronary artery with very limited runoff. The RIMA to the LAD was closed. The saphenous vein graft to the second diagonal and LAD was closed. The second saphenous vein graft to the distal LAD was heavily diseased with multiple 80% to 90% stenoses. The saphenous vein graft to the right coronary artery was widely patent, but a new 95% lesion had developed just distal to the anastomotic site (the culprit lesion for the patient's recent acute inferior myocardial infarction). The ejection fraction was 35%. The coronary anatomy was such that the patient's entire heart, both right and left ventricles, was dependent upon a very diseased vein graft to the LAD and a vein graft to the right coronary artery, beyond which a subtotal stenosis had developed. Due to the patient's history of peripheral vascular disease, moderate carotid stenosis, previous transient ischemic attacks, severe COPD, and general frailty, it was elected to perform his operation using an off-pump approach.

A redo, redo median sternotomy was performed. Epi-aortic ultrasound documented an area of the ascending aorta relatively free of disease where the DLP cannula was placed to provide inflow to the MPS system. The distal right coronary artery was occluded with a silastic vessel loop for 13 minutes during which time a distal anastomosis was constructed. The graft was immediately connected to the MPS system and the right coronary artery was reperfused expeditiously. The flow down this graft was 60 cc per minute at 100 torr pressure. This increased to 80 cc per minute at 120 torr pressure and was maintained at this pressure and flow while the distal anastomosis to the LAD was constructed. During a six-minute period of occlusion the distal LAD was grafted with a saphenous vein graft. Flow down this graft was 70 cc per minute at 100 torr pressure. The combined flow down both grafts was 130-140 cc per minute at 110 torr pressure. Thus both coronary targets were actively perfused immediately following distal anastomosis and the cumulative ischemic interval was

minimized. Both proximal anastomoses were constructed on a “biologically privileged” hood of a previous SVG without aortic clamping. The SVG to the right coronary artery had been cannulated via a side-branch, allowing continuous perfusion delivery from the MPS system during construction of the proximal anastomoses. Postoperative cardiac catheterization documented both new grafts to be widely patent with excellent flow. The patient was discharged home on the fourth postoperative day. At his one-month follow-up visit, he denied any recurrent angina or shortness of breath and reported walking one mile daily without supplemental oxygen.

Case 2

A 66-year-old gentleman with unstable angina had a cardiac catheterization in October 1999, documenting a 70% left main coronary stenosis, an 80% mid LAD stenosis, and complete occlusions of the proximal circumflex and proximal right coronary arteries. Bypass targets included the LAD, the first diagonal, the middle obtuse marginal coronary artery, and the posterior descending coronary. PADCAB times four was performed on October 6, 1999. After completion of the saphenous vein graft to the posterior descending coronary artery distal graft, MPS flow was directed to this target at a rate of 125 cc per minute (100 torr). After cardiac displacement, the circumflex territory was approached and the obtuse marginal distal coronary artery anastomosis was performed. This graft was also connected to the MPS multiple-perfusion set and perfused at 100 torr. The first diagonal was then grafted and perfused. In combination, the three grafts accommodated a flow of over 200 cc per minute. The LAD could then be occluded with confidence to construct the distal LIMA-LAD anastomosis. Proximal anastomoses were constructed to the ascending aorta under a partial occlusion clamp. Heparin was partially reversed and routine closure ensued. Postoperative cardiac catheterization documented all grafts to be widely patent and the patient was discharged home on postoperative day five, having been somewhat delayed by postoperative atrial fibrillation and preoperative tracheobronchitis. At his one-month follow-up visit, the patient stated that he was walking two miles a day and had no recurrent angina or shortness of breath.

Case 3

A 57-year-old, morbidly obese gentleman, with sleep apnea and a six-week history of unstable angina, came in with myocardial infarction and underwent cardiac catheterization. This documented a 70% left main coronary stenosis, an 80% lesion in the proximal LAD at the origin of a large diagonal and a 95% lesion on the right coronary artery. This third case parallels the second case in coronary anatomy: tight left main and LAD stenoses in the setting of a 95% right coronary stenosis. The patient underwent PADCAB times four on October 11, 1999. As in case two, the posterior descending coronary artery was grafted first and perfused immediately. The middle obtuse marginal vessel was grafted next and also perfused. The

combined flow down these two grafts was 150 cc per minute at 100 torr. After completion of the first diagonal coronary graft, the combined flow through the MPS system exceeded 200 cc per minute at 100 torr. The LAD was grafted with an in situ internal mammary artery pedicle at a deeply intramyocardial proximal location. This was the optimal site for anastomosis and mandated trimming of the LIMA pedicle appropriately. Grafting the LAD at this proximal location with an appropriately short LIMA pedicle would have rendered later grafting of the PDA and obtuse marginal targets impossible without severe tension on the internal mammary artery pedicle. Thus the MPS system provided flexibility of graft sequence, which was important in this case. Having completed the internal mammary artery pedicle graft, the LAD was reperfused and the proximal grafts were sutured under a partial occlusion clamp to the ascending aorta in sequence, continuing to perfuse each graft as long as possible. Postoperative cardiac catheterization documented all grafts to be widely patent and the patient was discharged home on postoperative day number three in good condition. At his follow-up visit, the patient stated he had no recurrent angina or shortness of breath.

DISCUSSION

With adequate surgeon experience and training, application of new retraction techniques and use of modern mechanical stabilization devices, most multivessel coronary bypass operations can be safely and precisely performed without the use of extracorporeal circulation [Puskas 1999]. However, the potential for hemodynamic deterioration in a downward spiral persists, especially in more complex cases where coronary anatomy is critical. Early experience with PADCAB suggests that this new technique may facilitate the application of off-pump coronary bypass to an increasingly large portion of patients with complex multivessel coronary artery disease [Guyton 2000]. The principle benefits of this technique are: 1) immediate perfusion of grafted myocardial regions to resuscitate ischemic myocardium and prevent cumulative ischemia; 2) enhanced hemodynamic stability during multivessel grafting due to improved myocardial perfusion and function; 3) the potential for administration of cardioprotective or vasoactive additives to the perfusate which may further facilitate myocardial recovery and function; and 4) an important logistic advantage to the surgeon in providing flexibility in graft sequence.

The PADCAB technique allows early reperfusion pressures to exceed systemic pressure. This may be a significant advantage in aborting a downward hemodynamic spiral. Passive flow systems such as aortocoronary shunts necessarily deliver blood at pressures below systemic levels and do not allow adjustment of flow rate to maintain balance between oxygen supply and demand. If the heart begins to fail, these passive flow rates will participate in a vicious spiral of progressive perfusion failure and progressive pump failure. This

is especially important in complex redo multivessel OPCAB cases in which collateral blood flow may provide an absolutely critical role in myocardial perfusion and function.

An advantage of the MPS delivery system is the potential for the infusion of a variety of vasodilator or cardioprotective pharmacologic agents directly into the distal coronary bed. Nitroglycerin, adenosine, nitric oxide generators, platelet and leukocyte adhesion inhibitors and membrane stabilizing drugs may all offer potential clinical advantage and deserve experimental evaluation [Guyton 2000].

Flexibility in the sequence of graft construction is a significant advantage of PAD CAB to avoid the potentially significant risk of tension or traction placed on a completed internal mammary artery graft during cardiac displacement to approach lateral wall targets. With the PAD CAB system, all graft lengths can be measured without regard to the need for subsequent extreme retraction of the heart, thereby promoting a more perfect geometry and avoidance of kinks and tension on completed grafts.

In conclusion, active perfusion of coronary artery bypass grafts during OPCAB facilitates application of off-pump techniques in complex multivessel cases. It may also encourage broader adoption of off-pump techniques in more routine cases. In our practice, the PAD CAB technique has helped expand application of off-pump techniques to the most complex coronary cases, some of which might not have otherwise been technically feasible without cardiopulmonary bypass.

REFERENCES

1. Guyton RA, Thourani VH, Puskas JD, et al. Perfusion assisted direct coronary artery bypass: enhanced myocardial perfusion during off pump coronary artery bypass. *Ann Thorac Surg* 69(1):171-5, 2000.
2. Puskas JP, Wright CE, Russell SR, Brown WM, Gott JP, Guyton RA, et al. *Heart Surgery Forum* #1999-95310 2(3):216-21, 1999.
3. Sydzzyk RT, Stammers AH, Zavadil DP, Deptula JJ, Christensen KA: Evaluation of a new generation cardioplegia administration system. *J Extra-Corporeal Tech* 29:145, 1997.

REVIEW AND COMMENTARY

1. Editorial Board Member PB44 writes:

This is an interesting idea. Although they indicate that drugs can be given, they did not in these cases. However, similar effects can be achieved by doing the proximals first.

Is PAD CAB of true value? Perfusion doesn't occur only in diastole, so might this cause some damage with an inability for the coronary circulation to self regulate?

Authors' Response by John D. Puskas, MD:

No drugs were added to the PAD CAB perfusate in these initial cases, however, we have found in subsequent cases that addition of even very small amounts of NTG may

increase collateral flow significantly, augmenting coronary perfusion.

PAD CAB offers an important advantage over the "proximals first" approach to OPCAB, namely, in PAD CAB the coronary perfusion pressure is independent of aortic pressure. With the "proximals first" approach, if cardiac manipulation during multivessel OPCAB produces a decline in systemic blood pressure, coronary perfusion pressure also declines, precisely at the time when it may be least well tolerated. This can lead to a vicious circle of low BP, low coronary perfusion pressure, poor myocardial contractility, leading to lower BP, etc. PAD CAB is the only technique available to actively interrupt this potentially dangerous downward spiral of hemodynamic instability.

PAD CAB provides coronary perfusion pressure during all phases of the cardiac cycle. We have found no evidence of injury to myocardial macro or micro vascular function or reactivity in several animal models.

2. Editorial Board Member JZ39 writes:

This is a well-written article. I wonder what the advantages of the technique are and I hope the authors will someday be able to show the benefits of this technique. I'm not sure why this is an "advance".

Authors' Response by John D. Puskas, MD:

It is my feeling that PAD CAB is an advance because it allows the surgeon to control coronary perfusion pressure independent of aortic pressure. This may be of fundamental importance when performing multivessel OPCAB in high-risk patients, where the potential for a downward hemodynamic spiral exists during sequential coronary occlusions and multiple or prolonged cardiac manipulations. This "security blanket" may allow the surgeon new to OPCAB to more rapidly broaden his patient selection, and may allow the experienced OPCAB surgeon to tackle the most complex, high-risk cases more safely.

3. Editorial Board Member SG14 writes:

For CABG I never use the pump, and always performing the aortic anastomoses first saves me the trouble of the proposed method. This method also includes the disadvantage that performing of the proximal anastomosis coronary perfusion through the vein graft should be interrupted. In addition, if aortic anastomosis has been performed first, antegrade deairing of the graft is feasible.

Authors' Response by John D. Puskas, MD:

PAD CAB facilitates antegrade deairing of grafts. Coronary perfusion via the PAD CAB system is interrupted as each graft is sutured to the aorta in turn, unless a small cannula is inserted into a side-branch of the vein graft(s), allowing continuous perfusion during the construction of the proximal anastomoses. We have found that sequential termination of PAD CAB flow in the grafts as proximal anastomoses are constructed is well tolerated, perhaps in part because this occurs after flow down the in situ LIMA has been initiated.