

Endoscopic Computer-Enhanced Mediastinal Mass Resection Using Robotic Technology

(#2003-50803 . . . July 7, 2003)

Jeffrey A. Morgan, MD, Takushi Kohmoto, MD, Craig R. Smith, MD, Mehmet C. Oz, MD, Michael Argenziano, MD

Division of Cardiothoracic Surgery, College of Physicians and Surgeons, Columbia University, New York, New York, USA



Dr. Morgan



ABSTRACT

Background: Robotic technology can be used to facilitate the performance of a variety of cardiac surgical procedures, including internal mammary artery mobilization, atrial septal defect repair, mitral valve repair, and coronary artery bypass grafting. This report describes the use of robotic technology for resection of mediastinal masses.

Methods: Two patients underwent mediastinal mass resection performed using the Da Vinci robotic surgical system (Intuitive Surgical, Mountain View, CA, USA). The first patient had a 3×4 -cm mass located in the left superior-posterior mediastinum, abutting the left subclavian artery. The second patient had a 2.7×1.9 -cm mass located in the left chest wall.

Results: Both mediastinal masses were successfully excised using a totally endoscopic robotic approach with three 1-cm incisions. Neither case was converted to a thoracotomy or sternotomy. There were no postoperative complications. Both patients were discharged on postoperative day 2.

Conclusions: Resection of a mediastinal mass can be performed safely and effectively using robotic technology. By minimizing surgical trauma, this approach is likely to yield a hastened postoperative recovery and improved quality of life.

INTRODUCTION

The advent of endoscopic techniques has impacted significantly on cardiac surgery. Robotic technology is gaining popularity and is currently used to perform numerous cardiothoracic procedures. These include internal mammary artery mobilization [Nataf 2000], atrial-septal defect (ASD) repair [Argenziano 2002], mitral valve replacement (MVR) [Cosgrove 1996, Cohn 1997, Cosgrove 1998, Chitwood 2000, Lapietra 2000], and coronary artery bypass grafting (CABG) [Stephenson 1998, Damiano 2000, Falk 2000a, Mohr 2001,

Received June 19, 2003; accepted July 7, 2003.

Address correspondence and reprint requests to: Jeffrey A. Morgan, MD, Columbia University, College of Physicians and Surgeons, 177 Fort Washington Avenue, Milstein Hospital 7GN-435, New York, NY 10032, USA; 1-212-305-5108; fax: 1-212-305-2439 (e-mail: jfm2240@columbia.edu).

Prasad 2001]. More recently, robotic techniques have been applied to the performance of advanced thoracoscopic procedures. This report describes the use of robotic technology for resection of mediastinal masses.

MATERIALS AND METHODS

Informed consent was obtained from all patients and the study was conducted with institutional approval.

The first patient was a 50-year-old woman with a significant smoking history who presented with an asymptomatic, suspicious mass found on chest x-ray (CXR). Confirmatory computed tomographic (CT) scan showed that the posterior mediastinal mass measured 3×4 cm, and there were no signs of metastases. The patient underwent a successful robotically assisted left posterior mediastinal mass resection.

The second patient was a 62-year-old man also with a significant smoking history, who presented with a 2.7×1.9 -cm left chest wall mass, located in the left upper lobe, discovered on CXR during work-up for tuberculosis. The patient underwent CT-guided biopsy of the mass, which was nondiagnostic. He subsequently underwent a successful robotically assisted left posterior chest wall mass resection.

DA VINCI ROBOTIC SYSTEM

The Da Vinci robotic system (Intuitive Surgical, Mountain View, CA, USA) (Figure 1) is a telemanipulator system that consists of a master console with viewing capability and surgical arms that control detachable EndoWrist instruments. The surgeon sits at the master console, which is located several feet away from the operating table (Figure 2). From the console, the surgeon has a high-definition, full-color, magnified, 3-dimensional image of the surgical site provided by the endoscope. There are two "master" handles, which are positioned beneath the console. The surgeon's movements are transmitted without noticeable delay to the arms of the robot.

To position the Da Vinci system, three 1-cm incisions are made followed by introduction of 3 ports. The first 1-cm incision is made in the fifth intercostal space, 2 cm anterior to the anterior axillary line. The first port allows access for an endoscope, a small camera that is attached to a fiber-optic cable. Two additional 1-cm incisions are made in the 3rd and 6th intercostal spaces, slightly anterior to the camera port

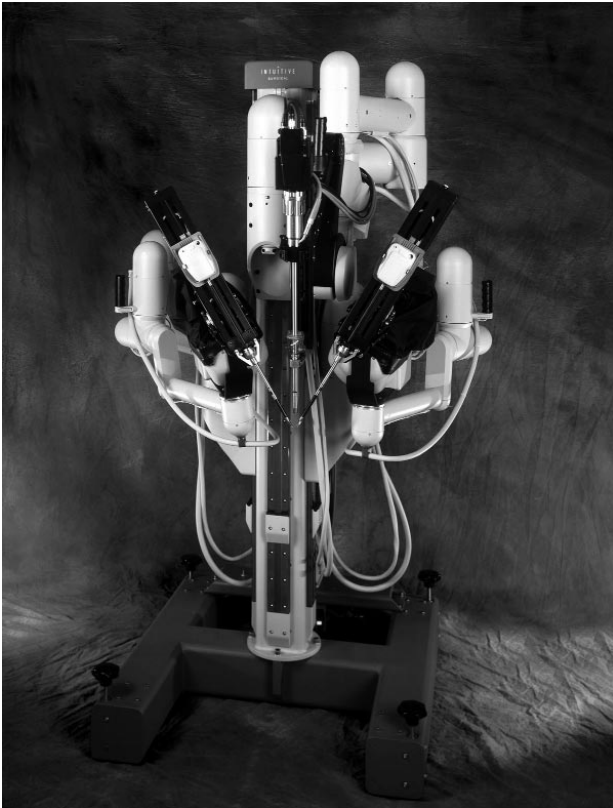

Figure 1. The Da Vinci robotic system.

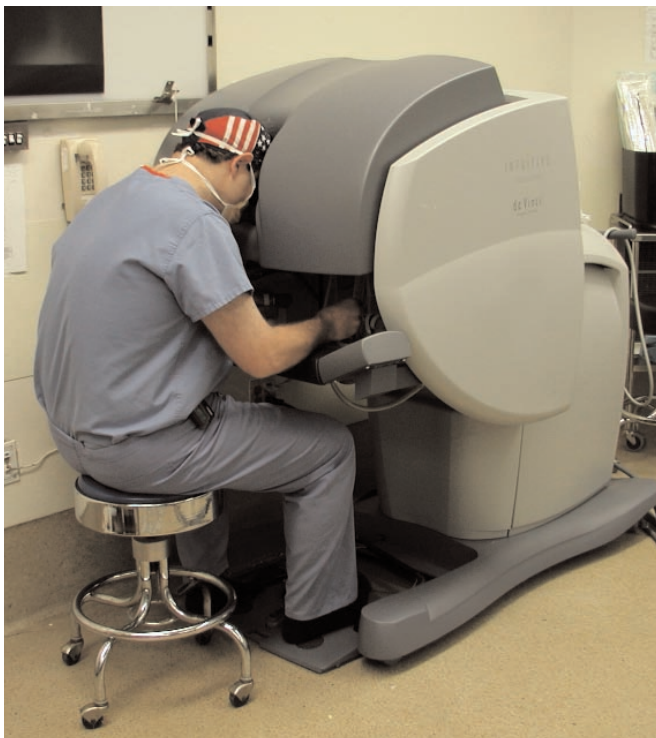

Figure 2. Surgeon seated at console.

site, through which the right and left arms of the robotic system are inserted sequentially under direct videoscopic guidance. These two ports provide access for surgical instruments. Pencil-sized instruments (with tiny, computer-enhanced mechanical wrists) are attached to the robotic arms and provide the dexterity of the surgeon's forearm and wrist at the operative site. The surgeon's movement translates into action by the robot. The robot's arms hold the instruments, bending back and forth, side to side, and rotating in a full circle, resulting in motion with seven degrees of freedom. [Falk 2000b, Kappert 2000].

With this system, the surgeon can enter the chest through keyhole incisions and perform closed-chest heart and lung surgery. An important feature of this technology is that the built-in computer eliminates tremor, enhancing the surgeon's hand movement and rendering it more precise. This element serves to refine the operative technique.

RESULTS

Excellent visualization was achieved. The patient's posterior superior mediastinal mass abutted but did not invade the left subclavian artery [Figure 3]. Mediastinal masses in both patients were successfully excised with their tumor capsules intact [Figure 4]. There were no conversions to thoracotomy or sternotomy. Intraoperative blood loss was minimal. There were no postoperative complications. The first patient's pathology was consistent with a benign, hyalinized neurofibroma. The pathology in the second patient indicated that the mass was a benign Schwannoma. Chest tubes were removed on postoperative day 1. Both patients were discharged home on postoperative day 2 and have done well.

DISCUSSION

Technological advancements over the last decade have enabled surgeons to perform minimally invasive surgery

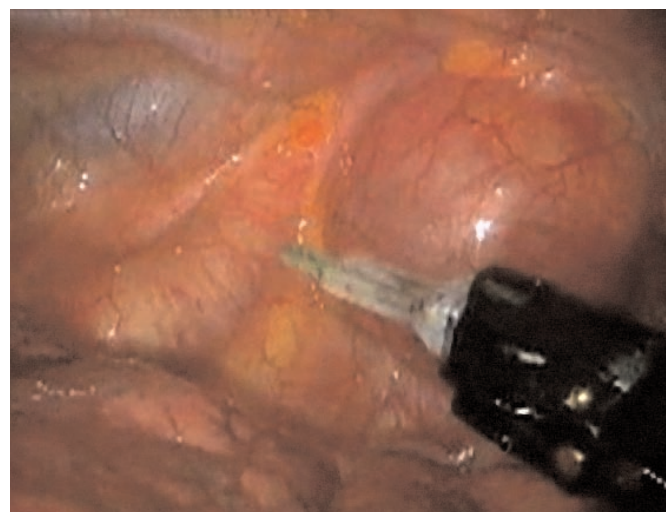

Figure 3. Mediastinal mass and adjacent anatomy.

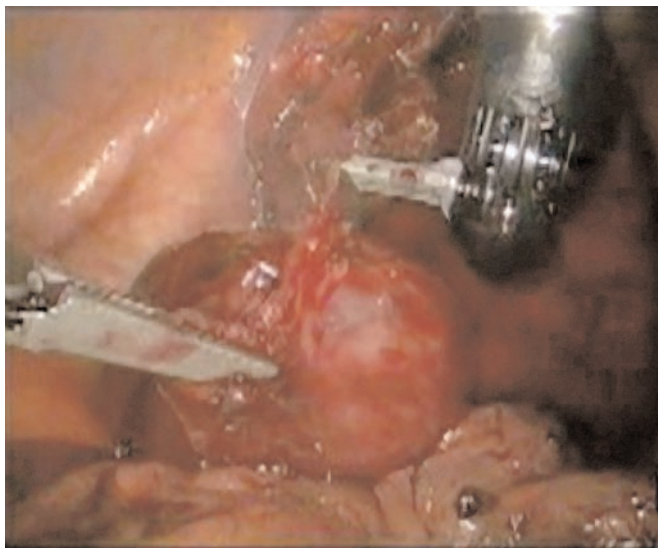


Figure 4. Excision of mediastinal mass.

without compromising the quality of the operation. The primary goal of minimally invasive surgery is to limit surgical trauma to patients, decrease associated intraoperative and postoperative stress, and hasten recovery. An endoscopic approach avoids a sternotomy or thoracotomy and minimizes incision sizes to 1 cm. The surgeon can perform closed-chest cardiothoracic surgery.

Encouraging results have been reported on the use of robotic technology in cardiac surgery, such as ASD closure, MVr, and CABG. Robotic techniques can also be applied to thoracoscopic intrathoracic surgery, such as resection of mediastinal masses. A totally endoscopic approach may serve to improve patient postoperative quality of life. Studies are currently underway at our institution comparing endoscopic, sternotomy, and thoracotomy approaches with regard to variables such as intensive care unit stay and hospital stay, as well as subjective outcome measures, such as pain and quality of life.

REFERENCES

- Argenziano M, Oz MC, DeRose JJ, et al. 2002. Totally endoscopic atrial septal defect repair utilizing robotic assistance. *Heart Surg Forum* 5:294-7.
- Chitwood WR Jr, Nifong LW, Elbeery JE, et al. 2000. Robotic mitral valve repair: trapezoidal resection and prosthetic annuloplasty with the Da Vinci surgical system. *J Thorac Cardiovasc Surg* 120:1171-2.
- Cohn LH, Adams DH, Couper GS, et al. 1997. Minimally invasive aortic valve replacement. *Semin Thorac Cardiovasc Surg* 9:331-6.
- Cosgrove DM, Sabik JF. 1996. Minimally invasive approach to aortic valve operations. *Ann Thorac Surg* 62:596-7.
- Cosgrove DM, Sabik JF, Navia JL. 1998. Minimally invasive valve surgery. *Ann Thorac Surg* 65:1535-8.
- Damiano RJ, Ehrman WJ, Dicko CT, et al. 2000. Initial United States clinical trial of robotically assisted endoscopic coronary artery bypass grafting. *J Thorac Cardiovasc Surg* 119:77-82.
- Falk V, Diegeler A, Walther T, et al. 2000. Total endoscopic computer enhanced coronary artery bypass grafting. *Eur J Cardiothorac Surg* 17:38-45.
- Falk V, Diegeler A, Walther T, et al. 2000. Developments in robotic cardiac surgery. *Curr Opin Cardiol* 15:378-87.
- Kappert U, Cichon R, Schneider J, et al. 2000. Robotic coronary artery surgery—the evolution of a new minimally invasive approach in coronary artery surgery. *Thorac Cardiovasc Surg* 48:193-7.
- LaPietra A, Grossi EA, Derivaux CC, et al. 2000. Robotic-assisted instruments enhance minimally invasive mitral valve surgery. *Ann Thorac Surg* 70:835-8.
- Mohr FW, Falk V, Diegeler A, et al. 2001. Computer-enhanced “robotic” cardiac surgery: experience in 148 patients. *J Thorac Cardiovasc Surg* 121:842-53.
- Nataf P, Al-Attar N, Ramadan R, et al. 2000. Thoracoscopic IMA take-down. *J Card Surg* 15:278-82.
- Prasad SM, Ducko CT, Stephenson ER, et al. 2001. Prospective clinical trial of robotically assisted endoscopic coronary grafting with 1-year follow up. *Ann Surg* 233:725-32.
- Stephenson ER, Sankholkar S, Ducko CT, et al. 1998. Robotically assisted microsurgery for endoscopic coronary artery bypass grafting. *Ann Thorac Surg* 66:1064-7.