

Quadruple Valve Replacement with Mechanical Valves: An 11-Year Follow-up Study

Yukun Cao, Chunhu Gu, Guocheng Sun, Shiqiang Yu, Hongbing Wang, Dinghua Yi

Department of Cardiovascular Surgery, Xijing Hospital, Fourth Military Medical University, Xi'an, China

ABSTRACT

Background: We performed the first quadruple valve replacement with mechanical valves, combined with the correction of complex congenital heart disease on November 17, 1999. We report here the 11-year follow-up study.

Methods: A 47-year-old man with subacute rheumatic endocarditis, a ventricular septal defect, and an obstruction of the right ventricular outflow tract required replacement of the aortic, mitral, tricuspid, and pulmonary valves; repair of the ventricular septal defect; and relief of the obstruction of the right ventricular outflow tract. The surgery was done on November 17, 1999, after careful systemic preparation of the patient. Warfarin therapy with a target international normalized ratio (INR) range of 1.5 to 2.0 was used. Follow-up included monitoring the INR, recording the incidences of thromboembolic and bleeding events, electrocardiography, radiography, and echocardiography evaluations.

Results: The patient's INR was maintained between 1.5 and 2.0. All 4 mechanical prosthetic heart valves worked well. He is in generally good health without any thromboembolic or bleeding complications.

Conclusions: Long-term management is challenging for patients who have experienced quadruple valve replacement with mechanical valves; however, promising results could mean that replacement of all 4 heart valves in 1 operation is feasible in patients with quadruple valve disease, and an INR of 1.5 to 2.0 could be appropriate for Chinese patients with undergoing valve replacement with mechanical valves.

INTRODUCTION

Single or double heart valve replacement for endocarditis

Yukun Cao, Chunhu Gu, and Guocheng Sun contributed equally to this work.

Received August 25, 2011; received in revised form October 23, 2011; accepted November 17, 2011.

Correspondence: Chunhu Gu, Department of Cardiovascular Surgery, Xijing Hospital, Fourth Military Medical University, 15# Changle West Rd, Xi'an 710032, China; 86-29-84775309; fax: 86-29-83210092 (e-mail: guchunbu@163.com, guchunbu@fmmu.edu.cn). Dr. Dinghua Yi, Department of Cardiovascular Surgery, Xijing Hospital, Fourth Military Medical University, 15# Changle West Rd, Xi'an 710032, China (e-mail: yidb@fmmu.edu.cn).

is a relatively common operation, but triple valve surgery is usually complex and carries a high operative mortality rate and a low 10-year survival rate [Alsoufi 2006]. Patients with mechanical heart valves must follow lifelong warfarin therapy. Warfarin is a difficult drug to manage, however, because of its narrow and controversial therapeutic window and potentially serious side effects.

Despite improvements in operative and myocardial-protection techniques, multiple valve surgery remains challenging. Patients are subjected to long cardiopulmonary bypass and myocardial ischemia times. The operative mortality rate reported after triple valve surgery is high and ranges between 13% and 25% [Galloway 1992; Alsoufi 2006]. Moreover, the replacement of multiple valves exposes the patient to added long-term morbidities related to prosthetic valves, such as thromboembolism, anticoagulation-related hemorrhage, endocarditis, and paravalvular leakage, compared with the replacement of single valves [Brown 1993]. Finally, triple valve surgery has been associated with diminished long-term survival, with reported survival rates at 5 years and 10 years of 75% and 61%, respectively [Alsoufi 2006]. Lifelong oral anticoagulation therapy is essential for the prevention of thromboembolic events in patients with valves replaced with mechanical valves [Cannegieter 1994]. Factors influencing the risk of arterial thromboembolism include valve type (caged ball, caged disk, tilting disk, or bileaflet), valve site (aortic or mitral), and the number of valves replaced [Salem 2004]; however, this treatment introduces a risk of severe or fatal bleeding [Levine 1989]. The aim of anticoagulation is to balance the lowest risk of bleeding with the lowest risk of thromboembolic complications. The European Society of Cardiology has recommended an INR of 3.0 to 3.5 for mechanical valves in the mitral position, whereas an INR of 2.5 to 3.0 was considered sufficient for mechanical valves in the aortic position [Gohlke-Bärwolf 1995]. The American College of Cardiology and American Heart Association guidelines of 2006 recommend an INR of 2.0 to 3.0 for replacing an aortic valve with a bileaflet mechanical or Medtronic Hall prosthesis in patients with no risk factors. If a patient has risk factors, oral anticoagulants are indicated to achieve an INR of 2.5 to 3.5. After replacement of an aortic valve with other mechanical valves, or after mitral valve replacement, an INR of 2.5 to 3.5 is also recommended [Bonow 2006]. This range is associated with an increased risk of bleeding complications. Because of differences in blood coagulation characteristics, Asian

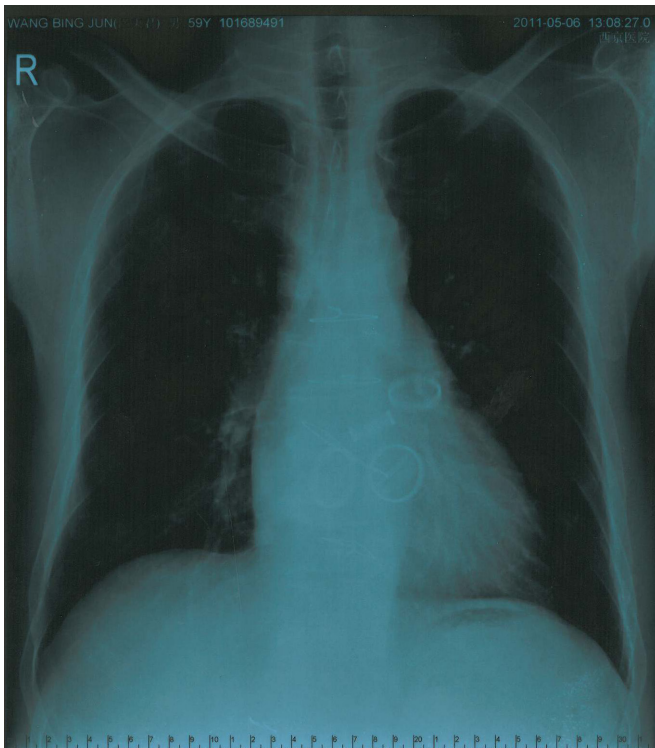


Figure 2. The chest x-ray film reveals a cardiothoracic value of 0.52 and clear lung fields.

RESULTS

At the 11-year follow-up, the patient is in generally good health without any thromboembolic and bleeding complications. Physical examination results are normal. The pulse rate is 103 beats/minute, and the blood pressure is 104/45 mm Hg. Auscultation reveals normal, crisp prosthesis sounds. The electrocardiogram shows atrial tachycardia with 2:1 conduction (Figure 1). The chest radiograph reveals the following: a cardiothoracic value of 0.52 and clear lung fields (Figure 2). Echocardiography evaluation reveals no obvious abnormality in the positions, echoes, and ranges of motion of the mitral, tricuspid, aortic, and pulmonary valves. Color Doppler flow imaging indicates the blood flow of each valve to be normal (mitral valve: maximum velocity [V_{max}] of 157 cm/s and maximum pressure gradient [PG_{max}] of 9 mm Hg; tricuspid valve: V_{max} of 120 cm/s and PG_{max} of 6 mm Hg; aortic valve: V_{max} of 159 cm/s and PG_{max} of 10 mm Hg; pulmonary valve: V_{max} of 126 cm/s and PG_{max} of 6 mm Hg). The left ventricular ejection fraction is 50% (Figure 3).

DISCUSSION

Quadruple valve replacement is complicated and challenging. The patient had underlying myocardial dysfunction because of his multiple valve disease, and he was exposed to prolonged cardiopulmonary bypass and myocardial ischemia. Heart valve replacement for endocarditis is a relatively common operation, but the current case is notable for

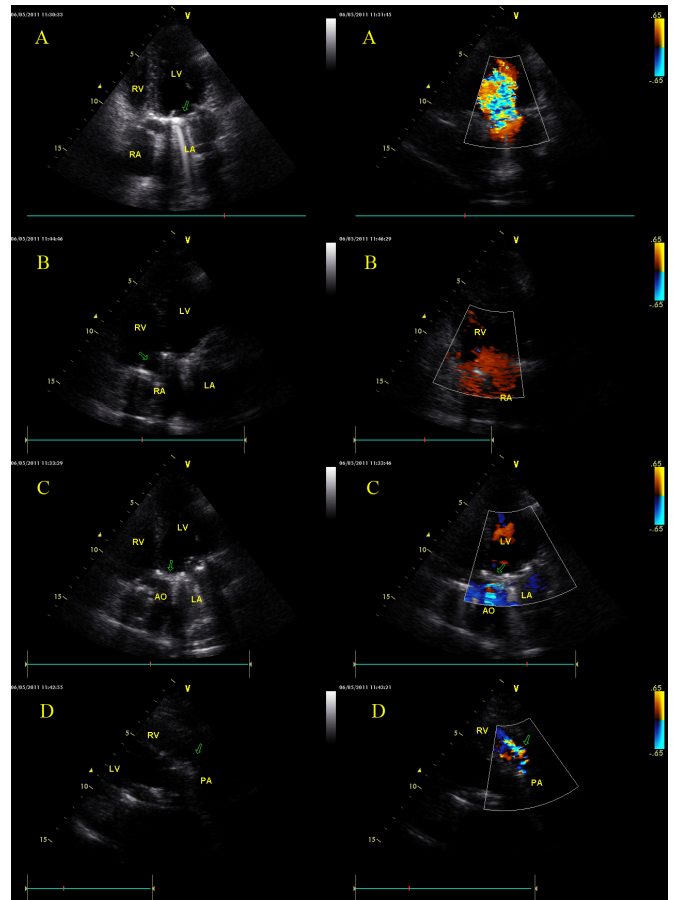


Figure 3. Echocardiography evaluation revealed no obvious abnormality of the positions, echoes, and ranges of motion of the mitral valve (A), tricuspid valve (B), aortic valve (C), or pulmonary valve (D). Color Doppler flow imaging indicates that the blood flow through each valve is normal. LV indicates left ventricle; RV, right ventricle; RA, right atrium; LA, left atrium; AO, aorta; PA, pulmonary artery.

2 reasons: (1) All cardiac valves were replaced with mechanical prosthetic heart valves in combination with correction of complex congenital heart disease in a single operation; and (2) the patient, in whom the INR has been maintained between approximately 1.5 and 2.0, has been living for 11 years without any thromboembolic or bleeding complications. To the best of our knowledge, the current report is the first to describe not only successful quadruple valve replacement with mechanical valves combined with correction of complex congenital heart disease for subacute rheumatic endocarditis, but also long-term survival after the surgery.

In 1987, Hossack and colleagues first reported on a patient with rheumatic involvement of all valves with a good long-term outcome. This patient underwent replacement of the aortic, mitral, and pulmonary valves, and because of severe regurgitation, he subsequently underwent replacement of the tricuspid valve as well [Hossack 1987]. Seeburger and colleagues also reported on a patient with rheumatic involvement of all valves [Seeburger 2009]. With the great medical advances available, especially the use of transesophageal

echocardiography in the diagnosis of infective endocarditis, they successfully replaced all cardiac valves in a single operation, and the patient recovered well. Although the cases mentioned above demonstrate that quadruple valve surgery can be performed successfully, previous reports have indicated that triple valve surgery is associated with a high operative mortality rate (ranging between 13% and 25%) and poor long-term survival, with reported survival rates at 5 years and 10 years of 75% and 61%, respectively [Galloway 1992; Alsoufi 2006]. We believe that improved perioperative care, including increased experience with complex surgical procedures, improved myocardial protection, and improved postoperative care contributed to the very good long-term survival observed in our follow-up study. To the best of our knowledge, our patient's survival time after surgery is the longest described among the current reports of quadruple valve replacement.

Patients who undergo valve replacement with mechanical heart valves require lifelong anticoagulation therapy [Cannegieter 1994]. The optimal anticoagulant intensity in patients with mechanical valves is still a matter of debate, however, and several guidelines have been published. In Western countries, the overall incidence of major hemorrhagic complications was still between 1.2 and 5.6 per 100 patient-years, and the rate of occurrence of thromboembolic events was between 0.4 and 6.5 per 100 patient-years [Levine 2001].

Asians seem to be less vulnerable to thrombotic diseases than Caucasians. The incidence of thromboembolism is low in Japan, despite the less intensive regimen [Kudo 1999]. Most of the current anticoagulation protocols in China are based on clinical results obtained from Western countries. There have been many more anticoagulant-related bleeding complications documented in past years [Sun 2003].

It is generally recommended that the intensity of anticoagulation be controlled within an ideal range to minimize hemorrhagic complications [Cortelazzo 1993]. The European Society of Cardiology has recommended an INR of 3.0 to 3.5 for mechanical valves in the mitral position, whereas an INR of 2.5 to 3.0 was considered sufficient for mechanical valves in the aortic position [Gohlke-Bärwolf 1995]. The American College of Cardiology and American Heart Association guidelines of 2006 recommend an INR of 2.0 to 3.0 for aortic valve replacement. If a patient has risk factors, oral anticoagulants are indicated to achieve an INR of 2.5 to 3.5 [Bonow 2006]. Mori and colleagues, however, found a significant increase in morbidity from bleeding in Japanese patients with an INR >2.5 [Mori 2002]. Uetsuka and colleagues investigated their experiences with 1157 Japanese patients with mechanical heart valve prostheses and discovered that the incidence of thromboembolism did not increase, even when the INR was reduced to 1.5 [Uetsuka 2000]. Some domestic institutions have suggested a target INR of 1.5 to 2.0 for Chinese patients [Dong 2003; Zhuang 2004; Zhou 2005]. Chenhsu and colleagues in Taipei noted a high incidence of bleeding and fatal hemorrhages among 61 patients with a mean INR of 1.9 [Chenhsu 2000]. Zhou and colleagues reported that the linearized rate of bleeding was 5.83 per 100 patient-years but only 0.26 per 100 patient-years for thromboembolism in their study [Zhou 2005]. Therefore, it is more important to focus

on preventing the occurrence of bleeding in Chinese patients than on the incidence of thromboembolism. In our hospital, warfarin therapy with an INR range of 1.5 to 2.0 was used for double or multiple valve replacement.

The Early Self-Controlled Anticoagulation Trial II has provided evidence that the INR target can be reduced from a range of 2.5 to 4.5 to a range of 1.8 to 2.8 in patients with aortic valve replacement, and to 2.5 to 3.5 in patients with mitral valve replacement or double valve replacement, without increasing the risk of thromboembolic events [Koertke 2007]. Nevertheless, their target INR range is higher than ours, and the goal of self-management is hard to realize in developing countries. In China, the monitoring of INR and subsequent adjustment of the warfarin dosage after hospital discharge is a significant challenge because of geographical restrictions, economic conditions, and a lack of medical knowledge. The fluctuation in the INR in the first 6 months was greater than in other periods, and the risk of developing bleeding complications is highest within the first half year after valve replacement [Eitz 2008]. Therefore, following up the patient in the first 6 months after discharge from the hospital is most critical. We suggest that patients be seen at least twice in these defining months.

Our patient made an excellent recovery from a large and complex operation without severe complications. The patient's INR was maintained between 1.5 and 2.0. All 4 mechanical prosthetic heart valves have been working well for the 11 years following the operation. He is in generally good health without any thromboembolic or bleeding complications. This case suggests that with adequate cardiac protection, replacement of all cardiac valves can be accomplished in selected patients with quadruple valve disease. A target INR of 1.5 to 2.0 could be appropriate for Chinese patients who undergo valve replacement with mechanical valves.

REFERENCES

- Alsoufi B, Rao V, Borger MA, et al. 2006. Short- and long-term results of triple valve surgery in the modern era. *Ann Thorac Surg* 81:2172-7; discussion 2177-8.
- Bonow RO, Carabello BA, Kanu C, et al. 2006. ACC/AHA 2006 guidelines for the management of patients with valvular heart disease: a report of the American College of Cardiology/American Heart Association Task Force on Practice Guidelines (writing committee to revise the 1998 Guidelines for the Management of Patients with Valvular Heart Disease): developed in collaboration with the Society of Cardiovascular Anesthesiologists: endorsed by the Society for Cardiovascular Angiography and Interventions and the Society of Thoracic Surgeons. *Circulation* 114:e84-231.
- Brown PS Jr, Roberts CS, McIntosh CL, Swain JA, Clark RE. 1993. Late results after triple-valve replacement with various substitute valves. *Ann Thorac Surg* 55:502-8.
- Cannegieter SC, Rosendaal FR, Briet E. 1994. Thromboembolic and bleeding complications in patients with mechanical heart valve prostheses. *Circulation* 89:635-41.
- Chenhsu RY, Chiang SC, Chou MH, Lin MF. 2000. Long-term treatment with warfarin in Chinese population. *Ann Pharmacother* 34:1395-401.
- Cortelazzo S, Finazzi G, Viero P, et al. 1993. Thrombotic and hemorrhagic

- complications in patients with mechanical heart valve prosthesis attending an anticoagulation clinic. *Thromb Haemost* 69:316-20.
- Dong L, Shi YK, Tian ZP, Ma JY, Wang X, Yi J. 2003. Low intensity anticoagulation therapy after mechanical heart valve replacement [in Chinese]. *Zhonghua Wai Ke Za Zhi* 41:250-2.
- Eitz T, Schenk S, Fritzsche D, et al. 2008. International normalized ratio self-management lowers the risk of thromboembolic events after prosthetic heart valve replacement. *Ann Thorac Surg* 85:949-54; discussion 955.
- Galloway AC, Grossi EA, Baumann FG, et al. 1992. Multiple valve operation for advanced valvular heart disease: results and risk factors in 513 patients. *J Am Coll Cardiol* 19:725-32.
- Gohlke-Bärwolf C, Acar J, Oakley C, et al. 1995. Guidelines for prevention of thromboembolic events in valvular heart disease. Study Group of the Working Group on Valvular Heart Disease of the European Society of Cardiology. *Eur Heart J* 16:1320-30.
- Hossack KF, Hopeman AR, Sutherland EW 3rd. 1987. Long-term follow-up of a patient with quadruple valve replacement. *Tex Heart Inst J* 14:315-7.
- Koertke H, Zittermann A, Tenderich G, et al. 2007. Low-dose oral anticoagulation in patients with mechanical heart valve prostheses: final report from the Early Self-Management Anticoagulation Trial II. *Eur Heart J* 28:2479-84.
- Kudo T, Kawase M, Kawada S, et al. 1999. Anticoagulation after valve replacement: a multicenter retrospective study. *Artif Organs* 23:199-203.
- Levine MN, Raskob G, Hirsh J. 1989. Hemorrhagic complications of long-term anticoagulant therapy. *Chest* 95:26S-36S.
- Levine MN, Raskob G, Landefeld S, Kearon C. 2001. Hemorrhagic complications of anticoagulant treatment. *Chest* 119:108S-21S.
- Mori T, Asano M, Ohtake H, et al. 2002. Anticoagulant therapy after prosthetic valve replacement—optimal PT-INR in Japanese patients. *Ann Thorac Cardiovasc Surg* 8:83-7.
- Salem DN, Stein PD, Al-Ahmad A, et al. 2004. Antithrombotic therapy in valvular heart disease—native and prosthetic: the Seventh ACCP Conference on Antithrombotic and Thrombolytic Therapy. *Chest* 126:457S-82S.
- Seeburger J, Groesdonk H, Borger MA, et al. 2009. Quadruple valve replacement for acute endocarditis. *J Thorac Cardiovasc Surg* 137:1564-5.
- Sun X, Hu S, Qi G, Zhou Y. 2003. Low standard oral anticoagulation therapy for Chinese patients with St. Jude mechanical heart valves. *Chin Med J (Engl)* 116:1175-8.
- Uetsuka Y, Hosoda S, Kasanuki H, et al. 2000. Optimal therapeutic range for oral anticoagulants in Japanese patients with prosthetic heart valves: a preliminary report from a single institution using conversion from thrombotest to PT-INR. *Heart Vessels* 15:124-8.
- Zhou XM, Zhuang W, Hu JG, Li JM, Yu JF, Jiang L. 2005. Low-dose anticoagulation in Chinese patients with mechanical heart valves. *Asian Cardiovasc Thorac Ann* 13:341-4.
- Zhuang W, Zhou XM, Hu JG, et al. 2004. Anticoagulation in Chinese patients with Carbomedics mechanical prosthetic heart valves [in Chinese]. *Zhong Nan Da Xue Xue Bao Yi Xue Ban* 29:460-2.