

Case Report

Bilateral Pectoralis Major Muscle Flaps in Treating Deep Sternal Wound Infection following CABG in Diabetic Patients: Two Case Reports

Zhenhao Liu¹, Yuyuan Hu¹, Xinmeng Cheng¹, Nan Wu¹, Tao Yang¹, Xuening Wang^{1,*}

¹Third Hospital of Shanxi Medical University, Shanxi Bethune Hospital, Shanxi Academy of Medical Sciences, Tongji Shanxi Hospital, 030032 Taiyuan, Shanxi, China

*Correspondence: wangxuening_2004@126.com (Xuening Wang)

Submitted: 9 June 2023 Revised: 15 August 2023 Accepted: 18 August 2023 Published: 6 September 2023

Abstract

Deep sternal wound infection (DSWI) is a life-threatening complication after cardiac operations, especially after coronary artery bypass grafting (CABG) in diabetic patients. Bilateral pectoralis major muscle flaps have been performed to treat DSWI. Two diabetic patients suffering from DSWI after CABG were treated by bilateral pectoralis major muscle flaps in our hospital. Both patients were discharged with full recovery. Satisfactory results can be obtained with bilateral pectoralis major muscle flaps following tissue debridement and drainage. This procedure should be performed when DSWI occurs in diabetic patients after CABG.

Keywords

deep sternal wound infection; coronary artery bypass grafting; diabetes mellitus; pectoralis major muscle flap

Introduction

Deep sternal wound infection (DSWI) following cardiac operation is a serious complication with an incidence of 0.25% to 4% [1]. DSWI in diabetic patients undergoing coronary artery bypass grafting (CABG) has been reported with higher morbidity, leading to longer postoperative hospital stay and increased medical costs. DSWI without surgical treatment has a mortality rate of about 70%–80% [1]. Surgical treatment is recommended muscle flaps using the pectoralis major or the rectus abdominis, have been proved to be safe with good outcomes [2]. Of 156 diabetic patients undergoing CABG during a 24 month in our hospital, DSWI occurred in 2 patients (1.28%). Both received bilateral pectoralis major muscle flaps with debridement of infected tissue and drainage, and were discharged with full recovery. The CARE checklist was used when writing this case report **Supplementary Table 1** [3].

Case Report 1

A 59-year-old female with diabetes was admitted to our hospital with unstable anterior chest pain for 2 months. Coronary arteriography revealed a 50% stenosis in the mid left anterior descending (LAD), an 80% stenosis in the mid left circumflex (LCX), and a total occlusion of the mid right coronary artery (RCA). The patient underwent a CABG×3 via a median sternotomy with the left internal mammary artery (LIMA) to the LAD, and two great saphenous veins to the LCX and posterior descending artery respectively. The sternum was closed with five wires. The patient's vital signs were stable, but drainage was noted from the median sternotomy incision 5 days after surgery. After 3 days of dressing changes, the sternum was debrided and closed primarily. However, the incision did not heal, and the sternum dehiscence after all the wires pulled through. The white blood cell count continued to rise. The original wires were removed, and the sternum was debrided and rewired under general anesthesia in the operating room. The patient was discharged 10 days after the reoperation and remained afebrile. Subsequently, the patient re-admitted for fever (38.6 °C) and incisional drainage. Laboratory data showed that C-reactive protein (CRP) was 416.1 mg/L, procalcitonin was 3.51 ng/mL and white blood cell (WBC) was $21.4 \times 10^9/L$ were higher than normal. The wires were loose, and the sternum was grossly unstable with increased purulent secretions from the sternum (Fig. 1A). Methicillin resistant staphylococcus aureus (MRSA) grew from the wound cultures. According to the Centers for Disease Control and Prevention (CDC), DSWI must meet at least one of the following three criteria: (1) organism(s) are identified from mediastinal tissue or fluid by a culture- or nonculture-based microbiologic testing method that is performed for the purposes of clinical diagnosis or treatment (not for surveillance purpose); (2) evidence of mediastinitis on gross anatomic or histopathologic exam and (3) patient has at least one of the following signs or symptoms: fever (>38.0 °C), chest pain, or sternal instability, and at least one of the following: purulent drainage from mediastinal area or mediastinal widening on imaging test. The patient

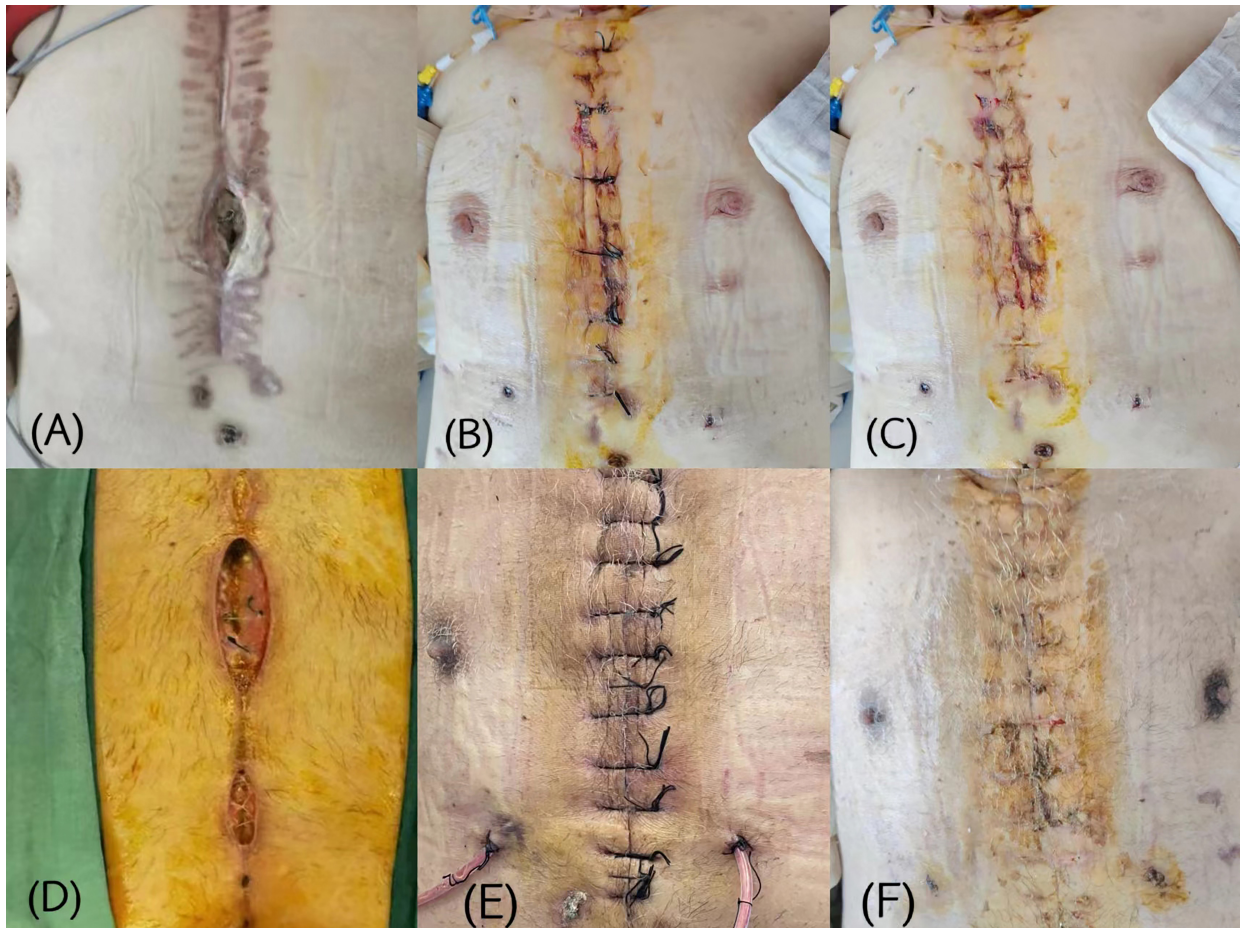


Fig. 1. Comparison of two patients before and after procedures. (A) The incision with DSWI (case 1). (B) The incision healed well and the sutures were removed (case 1). (C) The incision at discharge (case 1). (D) The incision with DSWI (case 2). (E) Incision at the end of operation (case 2). (F) The incision at 3 months of follow-up (case 2). DSWI, deep sternal wound infection.

fulfilled the criteria defined by the CDC and was diagnosed with a DSWI [4]. After careful preoperative discussion, bilateral pectoralis major muscle flaps with adequate infected tissue debridement and drainage was performed.

Surgery was performed under tracheal intubation and general anesthesia. The necrotic skin and subcutaneous tissues of the infected incision were extensively debrided (Fig. 2A). Infected and necrotic sternum and cartilage were removed until fresh and normal bone tissue was exposed (Fig. 2B). The incision was rinsed with hydrogen peroxide, iodophor (10% povidone-iodine) and normal saline. The space between the subcutaneous tissue and the external surface of pectoralis was separated on both sides (Fig. 2C). Then the space between the internal surface of pectoralis and the rib surface was separated on both sides until the muscle flaps could be stretched to the mid-line without tension, and the mediastinal space between the sternum could be completely filled. A porous silica gel drainage tube (No. 24) was placed into the mediastinal defect and two porous silica gel drainage tubes (No. 22) were placed subcutaneously on both sides (Fig. 2D). Then the bilateral pectoralis muscles were sutured by introversion with

3-0 Prolene suture intermittently to fill the mediastinal defect (Fig. 2E) to completely eliminate the residual cavity. A full layer of skin and subcutaneous tissue was sutured with interrupted No. 7 Mousse sutures (Fig. 2F). The three drainage tubes were connected to negative pressure suction. A chest binder was used for a compression dressing. Post-operative antibiotics were administered, the blood glucose level was strictly controlled and the incision was observed closely and the dressing was changed daily. The patient recovered well without fever, and the white blood cell count returned to normal. The drainage tubes were removed one month after the operation. The incision healed well and the sutures were removed at 40 days (Fig. 1B,C). The chest binder was removed 3 months after surgery. All the laboratory data were normal. The patient remained well during 12 months of follow-up.

Case Report 2

A 54-year-old male with diabetes was admitted to our hospital with persistent chest pain for 1 hour. Coronary ar-

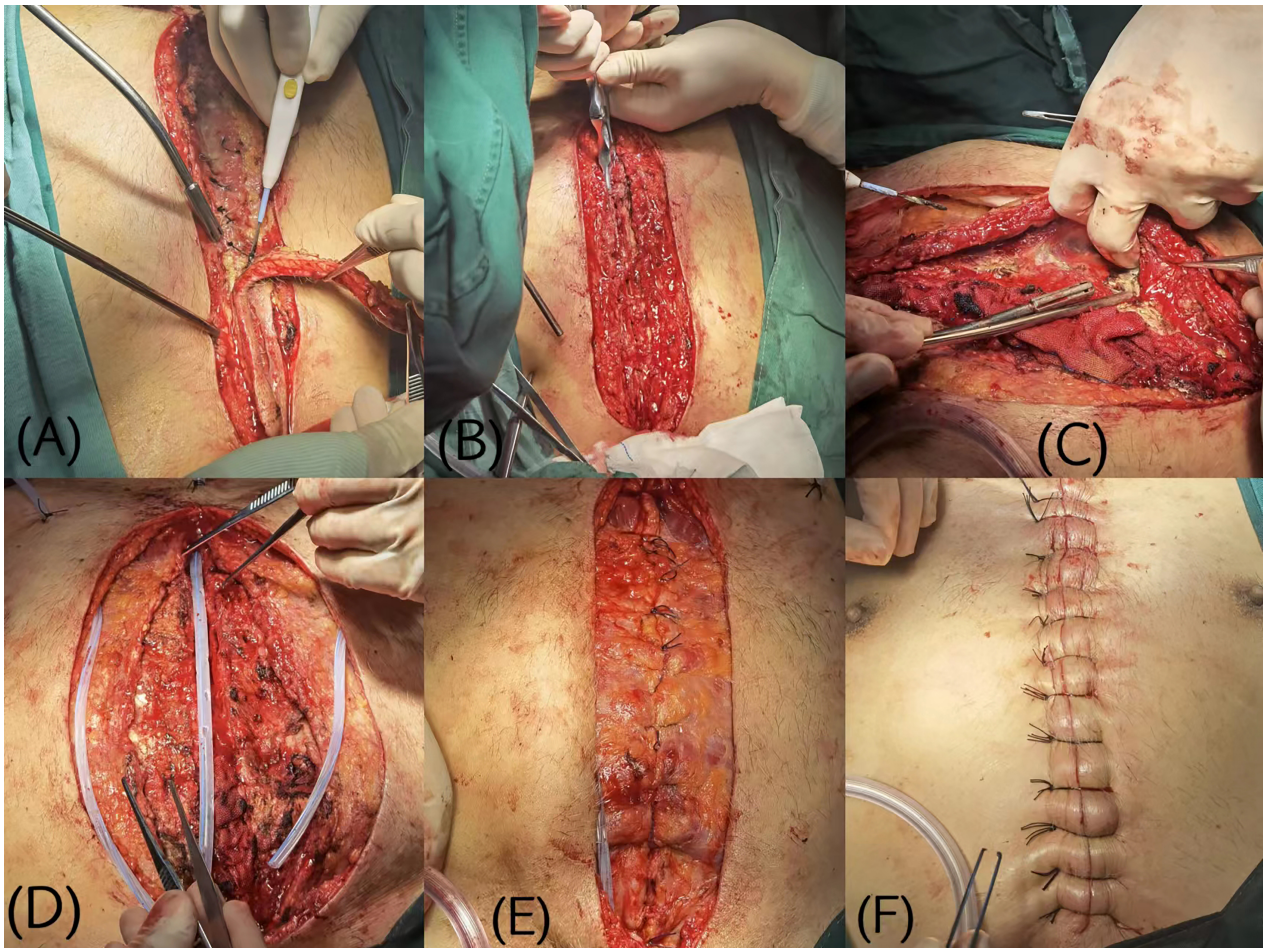


Fig. 2. Procedure of bilateral pectoralis major muscle flaps. (A) Necrotic skin and subcutaneous tissue were excised. (B) Necrotic sternum was removed. (C) Bilateral pectoralis major muscle was mobilized. (D) Drainage tubes were placed. (E) The bilateral pectoralis were sutured by introversion. (F) Skin and subcutaneous tissue was sutured.

tertiography revealed diffuse stenosis of multiple coronary arteries. The patient underwent a CABG \times 3. However, he developed dehiscence of the median sternotomy incision with low fever 7 days after surgery. Sternal instability and drainage were also found (Fig. 1D). The patient's laboratory data showed a marked inflammatory response. The patient was diagnosed with a post-operative DSWI. Bilateral pectoralis major muscle flaps were immediately performed. The patient recovered well and was discharged 20 days after the operation. All the laboratory data were normal. The incision healed well with no complications during 3 to 6 months of follow-up (Fig. 1E,F).

Discussion

DSWI is a life-threatening complication with a high mortality rate without surgical treatment. Multivariable predictors for DSWI are old age, obesity, diabetes, use of the internal mammary artery, increased operation time, unstable sternal fixation, and long postoperative intensive care unit (ICU) stay [1]. CABG is a widely accepted

cardiac surgery for treatment of multivessel coronary disease. Most methods of CABG still use a median sternotomy. The internal mammary artery (IMA) is the most commonly used bypass graft material for CABG. However, as the blood supply of the sternum is reduced, the harvest of the IMA or BIMA might lead to a higher incidence of incisional infection and DSWI [5]. The incidence of postoperative DSWI in patients undergoing CABG is 0.5%–6% higher than that of a conventional median sternotomy [6]. Patients who receive CABG often suffer from diabetic mellitus. Long-term diabetes mellitus will lead to neurovascular lesions, poor wound healing, and low immunity. Therefore, both use of the IMA and diabetes mellitus have been shown to be the independent predictors of DSWI. The incidence of DSWI in diabetic patients following CABG is approximately 8.1%–3.9% higher than that in non-diabetic patients [7]. DSWI after CABG in diabetes is a complex treatment challenge. Conventional treatment methods include povidone iodine irrigation, hydrogen peroxide irrigation, debridement and other procedures, but it is difficult to completely and effectively cure

DSWI, so that the prognosis is poor, with an increased mortality rate. Emerging treatment methods to treat DSWI include vacuum assisted closure (VAC) and skin flap transplantation [8]. According to the latest research, bilateral pectoralis major muscle flaps guarantee better early and late outcomes compared with VAC treatment, manifested as shorter hospital stay, higher long-term survival rate and no damage to respiratory function [9]. Vacuum assisted therapy is currently more recommended as a routine postoperative or even preoperative treatment, and flap transplantation techniques are now the mainstream therapy for DSWI [10]. The use of pectoralis major flaps to repair sternal defects was first described in 1980. It can be used as a unilateral or bilateral flap, depending on the size of the defect. Bilateral pectoralis major myocutaneous flap transplantation can improve sternal stability and further eliminate dead space. In general, pectoralis major muscle flap (PMMF) is a reliable flap for the upper 2/3 of sternal defects. The rectus abdominis flap is an ideal choice for reconstructing the lower third of the sternum. The combination of VAC and tissue flaps is favored by more surgeons because it has significantly reduced mortality [9].

Based on our experience, the procedure of bilateral pectoralis major flaps should be performed once postoperative DSWI occurs in diabetic patients with IMA grafts for CABG. Simple debridement and antibiotics might not control or reduce DSWI, especially with local MRSA infection. Because the bacteria that reproduce and its treatment are the conditions that change the healing processes. The most common pathogens detected in DSWI are *Staphylococcus epidermidis* (49.6%), followed by *Staphylococcus aureus* (38.8%). MRSA was observed in 4.9% of the cohort. It has been shown that the mortality of DSWI caused by MRSA is significantly increased without surgery [11]. The postoperative DSWI of the case one in our study was difficult to control by long-term repeated debridement and drainage. The patient benefited from the bilateral pectoralis major muscle flaps. In addition, reconstruction with pectoralis major flaps provides an acceptable aesthetic result.

For case two, bilateral pectoralis major muscle flaps were performed as soon as DSWI was diagnosed. The patient recovered and was discharged early without complications, with decreased medical costs. Therefore, once postoperative DSWI occurs in diabetic patients in CABG, bilateral pectoralis major flaps should be performed. Despite the positive results in this study, there are still some deficiencies in the treatment of DSWI with bilateral pectoralis major muscle flaps. First, the vast majority of people, even those engaged in manual labor, do not have developed pectoralis major muscle, unless they exercise it intentionally. In many cases, the sternum is completely removed and we can see the heart beating on the chest wall. Increased risk of heart damage. Second, there is still a risk of recurrence of DSWI after bilateral pectoralis major muscle flaps surgery. Despite the good post-operative outcomes in our two cases,

this was not statistically significant. The recurrence rate after muscle flap reconstruction has been reported between 0% to 20% [1].

There are several important points when performing bilateral pectoralis major muscle flaps. (1) All infected and necrotic tissue, sternum and cartilage need to be completely removed. (2) Bilateral turnover flaps are superior to unilateral turnover flaps, which may not be capable of completely filling the mediastinal space. (3) Attention should be paid to avoid injury to bypass grafts during flap procedures. (4) Intercostal thoracic perforator arteries and the vascular pedicle of the pectoralis major need to be protected. (5) Closure with stapler, rapid closure or closure with interrupted prolene should be avoided when closing the skin. (6) Adequate drainage between sternum and subcutaneous is critical. (7) The chest band should be compressed for at least 3 months after surgery to maintain the stability of the thorax. (8) Appropriate and timely antibiotics, especially for patients with MRSA, should be instituted, to adequately treat the appropriate organisms.

Due to the high incidence of DSWI for diabetic patients following CABG, there are some preventive measures that need to be recommended. (1) Recognize and pay attention to the risk factors of DSWI, such as old age, obesity, chronic obstructive pulmonary diseases (COPD), use of IMA, *etc.* (2) Perioperative blood glucose in diabetic patients needs to be strictly controlled. (3) Pay attention to airway management to prevent persistent cough. (4) Closely observe the changes of the surgical incision and change the dressing regularly. (5) Use the chest binder to maintain sternal stability. (6) Maintain proper activity and balanced nutrition after operation.

Conclusion

Satisfactory results can be obtained by bilateral pectoralis major muscle flaps with adequate infected tissue debridement and drainage. This procedure should be performed actively, when DSWI occurs in diabetic patients after CABG.

Abbreviations

DSWI, deep sternal wound infection; CABG, coronary artery bypass grafting; LAD, left anterior descending; LCX, left circumflex; RCA, right coronary artery; LIMA, left internal mammary artery; MRSA, methicillin resistant staphylococcus aureus; CRP, C-reactive protein; WBC, white blood cell; CDC, centers for disease control and prevention; IMA, internal mammary artery; VAC, vacuum-assisted closure; ICU, intensive care unit; PMMF, pectoralis major muscle flap; COPD, chronic obstructive pulmonary diseases.

Availability of Data and Materials

Datasets used and/or analyzed for this study are available from the corresponding author upon appropriate request.

Author Contributions

All authors designed and gave the main idea of this case report. ZL wrote the manuscript. YH made Fig. 1 and Fig. 2. NW and TY collected patient data. XC and XW conducted a control and critical review of the manuscript. All authors contributed to editorial changes in the manuscript. All authors read and approved the final manuscript. All authors have participated sufficiently in the work to take public responsibility for appropriate portions of the content and agreed to be accountable for all aspects of the work in ensuring that questions related to its accuracy or integrity.

Ethics Approval and Consent to Participate

Institutional review board approval was obtained before publication of this manuscript. This study was conducted according to the “Helsinki Declaration” and was approved by Shanxi Bethune Hospital (IRB: SBQKL-2022-034). Before deciding to participate in this trial, each patient was given written informed consent.

Acknowledgment

The first author, Zhenhao Liu, thanks his parents for their encouragement and support.

Funding

This work was supported by the Department of Human Resource and Social Security of Shanxi Province China (grant no. 2019–29) and the Science and Technology Department of Shanxi Province (grant no. 201701D121152).

Conflict of Interest

The authors declare no conflict of interest.

Supplementary Material

Supplementary material associated with this article can be found, in the online version, at <https://doi.org/10.59958/hsf.5847>.

References

- [1] Perezgrovas-Olaria R, Audisio K, Cancelli G, Rahouma M, Ibrahim M, Soletti GJ, *et al.* Deep Sternal Wound Infection and Mortality in Cardiac Surgery: A Meta-analysis. *The Annals of Thoracic Surgery.* 2023; 115: 272–280.
- [2] Zhang H, Lin J, Yang H, Pan Y, Chen L. Bilateral partial pectoralis major muscle turnover flaps for the management of deep sternal wound infection following cardiac surgery. *Journal of Thoracic Disease.* 2020; 12: 6010–6015.
- [3] Riley DS, Barber MS, Kienle GS, Aronson JK, von Schoen-Angerer T, Tugwell P, *et al.* CARE guidelines for case reports: explanation and elaboration document. *Journal of Clinical Epidemiology.* 2017; 89: 218–235.
- [4] Yusuf E, Chan M, Renz N, Trampuz A. Current perspectives on diagnosis and management of sternal wound infections. *Infection and Drug Resistance.* 2018; 11: 961–968.
- [5] Abreu A, Máximo J, Leite-Moreira A. Long-term survival of single versus bilateral internal mammary artery grafting in patients under 70. *Interactive Cardiovascular and Thoracic Surgery.* 2022; 35: ivac225.
- [6] Kaspersen AE, Nielsen SJ, Orrason AW, Petursdottir A, Sigurdsson MI, Jeppsson A, *et al.* Short- and long-term mortality after deep sternal wound infection following cardiac surgery: experiences from SWEDEHEART. *European Journal of Cardiothoracic Surgery.* 2021; 60: 233–241.
- [7] Masroor M, Fu X, Khan UZ, Zhao Y. Effect of bilateral internal thoracic artery harvesting on deep sternal wound infection in diabetic patients: Review of literature. *Annals of Medicine and Surgery (2012).* 2021; 66: 102382.
- [8] Lo Torto F, Turriziani G, Donato C, Marcasciano M, Redi U, Greco M, *et al.* Deep sternal wound infection following cardiac surgery: A comparison of the monolateral with the bilateral pectoralis major flaps. *International Wound Journal.* 2020; 17: 683–691.
- [9] Pan T, Li K, Fan FD, Gao YS, Wang DJ. Vacuum-assisted closure vs. bilateral pectoralis major muscle flaps for deep sternal wounds infection. *Journal of Thoracic Disease.* 2020; 12: 866–875.
- [10] Chen C, Gao Y, Zhao D, Ma Z, Su Y, Mo R. Deep sternal wound infection and pectoralis major muscle flap reconstruction: A single-center 20-year retrospective study. *Frontiers in Surgery.* 2022; 9: 870044.
- [11] Yu J, Wu R, Xiong B, Huang Z, Li H. Metagenomic Next-Generation Sequencing in the Diagnosis of Deep Sternal Wound Infection After Cardiac Transplantation: A Case Report and Literature Review. *The Heart Surgery Forum.* 2021; 24: E1015–E1017.