

## Guidant Heartstring: Initial Experience in OPCAB Surgery

Alberto Weber, Oliver Reuthebuch, Marko Turina

Department of Cardiovascular Surgery, University Hospital, Zurich, Switzerland

### ABSTRACT

**Purpose:** The aim of this study was to evaluate the feasibility of the Heartstring hemostatic seal system for proximal anastomoses without the need for aortic side clamping in off-pump coronary artery bypass surgery.

**Material and Methods:** Between May and November 2003, 50 proximal bypass anastomoses were performed with the Heartstring device in 29 consecutive patients (21 men, 8 women) with calcified aorta (assessed by transesophageal echocardiography/digital palpation). Mean patient age was  $68 \pm 7$  years. A mean of 1.7 anastomoses per patient was performed. Bypass patency was assessed by intraoperative flow measurements. Neurological outcome was graded in 4 severities.

**Results:** The learning curve was completed after deployment of approximately 10 devices. Crack of the seal prior to deployment occurred in 8 cases. No conversion to conventional side clamping was needed. No accidental stitching of the seal or wrapping of the suture around the seal stem occurred. Slight diffuse bleeding occurred with arterial pressure under 65 mm Hg. Bypass graft flow was  $53.7 \pm 23.9$  L/min. No perioperative ischemic events occurred, and there were no postoperative neurological complications.

**Conclusions:** Proximal bypass aortic anastomoses can be performed safely without side clamping using the Heartstring hemostatic seal system. Anastomoses can be completed with no foreign material (stent) remaining.

### BACKGROUND

Off-pump coronary artery bypass (OPCAB) obviates the need for aortic cannulation and cross clamping and offsets untoward effects, such as inflammatory responses [Matata 2000] and aerial or platelet aggregate emboli, related to cardiopulmonary bypass. Nevertheless, the use of partial aortic clamps to construct proximal aortic anastomoses is still necessary. Albeit with a few exceptions [Stamou 2002], to date only modest neurological benefit has been observed following OPCAB in comparison to conventional CABG; consistent and reproducible benefits in terms of major neurologic outcome have not been evident [Iaco 1999, Arom 2000]. These

results have been further corroborated in recent prospective randomized comparative studies [van Dijk 2001, Angelini 2002, Puskas 2003].

Recently, major efforts have been focused on the development of innovative revascularization techniques to reduce neurologic complications and accelerate patient recovery after off-pump coronary revascularization. One of the main goals to be achieved is the reduction of manipulation of the ascending aorta, perhaps the most important factor in reducing neurologic complications.

Clampless OPCAB is associated with reproducible neurologic benefit. Improved neurologic outcome may be conferred irrespective of the method of aortic screening in patients 75 years or older; the use of arterial conduits by in situ or T-graft arterial configurations might be one strategy to achieve the goal of clampless revascularization [Oren Lev-Ran 2004].

Additionally, the development of proximal anastomotic devices opens new possibilities to minimize manipulation of the ascending aorta.

A new device to perform proximal bypass anastomoses without the necessity of side clamping and without leaving behind potential thromboembolic material, the Heartstring proximal seal system, has been developed by Guidant Corporation (Santa Clara, CA, USA). Additionally this new device seems to have several benefits compared to other current proximal anastomotic devices. In the present study we report our initial experience with this device in 29 consecutive patients requiring OPCAB surgery.

### METHODS

#### Patients

Twenty-nine patients, 21 men and 8 women, who underwent CABG on the beating heart without extracorporeal circulation and who received at least 1 bypass graft with proximal aortic anastomosis using the Heartstring proximal seal system device were evaluated. The mean age of the patients was  $68 \pm 7$  years (range, 47 to 83 years). Further preoperative patient profile data are listed in Table 1.

The preoperative patient risk evaluation regarding degree and extent of arteriosclerotic vascular disease was evaluated by means of conventional chest x-ray, neurological clinical evaluation, carotid sonography, and eventually brain computed tomographic (CT) scan (Table 2). Aortic sclerosis was observed on conventional chest x-ray examination in 34% of the cases. The intraoperative atheroma grading (Montgomery-Rivakobe [Montgomery 1996]) of the ascending aorta and the decision for a proximal anastomotic site was assessed by transesophageal echocardiography and digital

*Presented at the 10th Annual CTT Meeting 2004, Miami Beach, Florida, March 10-13, 2004.*

*Address correspondence and reprint requests to: Alberto Weber, University Hospital, Department of Cardiovascular Surgery, Ramistrasse 100, Zurich CH8091, Switzerland (e-mail: alberto.weber@usz.ch).*

Table 1. Preoperative Patients Risk Profile (N = 29)

Risk Profile	%
Coronary artery 3 vessel disease	68.9
Main vessel disease	34.4
Ejection fraction, average	57.4
Peripheral occlusive arterial disease	17.2
Intraaortic balloon pump preoperative	20.6
Arterial hypertension	24.1
Diabetes	24.1
Nicotine	34.4
Dyslipidemia	75.8
Positive family history	41.4
Parsonnet score, average	7.8
Euroscore standard, average	3.8

palpation. Only 3 patients presented with atheroma grade III, whereas all other patients presented with atheroma grade I of the ascending aorta. Intraoperative blood flow was measured for all grafts with the Cardiomed flowmeter (Medi-Stim, Oslo, Norway) according to the transit time principle. Postoperative medical therapy included acetylsalicylic acid (100 mg/d) and clopidrogel (75 mg/d) for all patients.

All patients underwent preoperative and postoperative neurologic evaluation prior to discharge. Neurologic complications were classified as global or focal and reversible or irreversible. Six patients presented with history of cerebrovascular insult and ischemic lesions visible on brain CT. One patient had a global neurological deficit (aphasia), and 5 presented with focal neurological deficits, but all of these deficits were classified as reversible and already in regression prior to OPCAB.

The average number of distal bypass anastomoses was 3.1, and all left anterior descending coronary arteries were revascularized with the left internal mammary artery. Bilateral mammary arteries were used in 7 cases, and 4 patients received a full arterial revascularization including the radial artery.

**Technique**

The Heartstring proximal seal device comprises the proximal seal, a delivery device, and an aortic punch. First, after digital palpation of the ascending aorta, a stitch with a 12-French needle is performed to mark the entrance of the punch (Figure 1). Then, a hole site is created and the aortic punch is carefully rotated into the aorta (Figure 2). To ensure removal

Table 2. Postoperative Maximal Enzymes Values and Transesophageal Echocardiography (TEE) Result\*

Creatinine kinase, U/L	920 ± 753 (<190)
Creatinine kinase-MB isoenzyme, U/L	30 ± 11.5 (<24)
Troponine T, µg/L	0.55 ± 0.4 (<0.01)
Creatinine, µg/L	98 ± 28.6 (70-105)
TEE postoperative	Same as preoperative

\*Data are presented as mean ± SD (normal values).

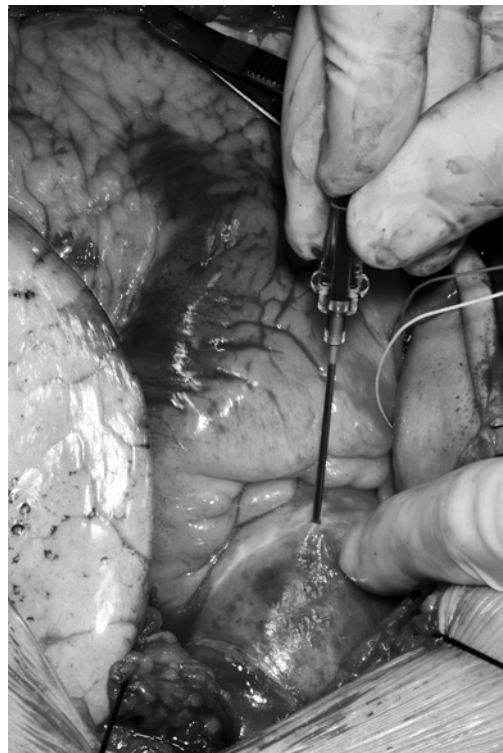


Figure 1. After the ascending aorta is digitally palpated, a stitch with a 12-French needle is performed to mark the entrance of the punch.

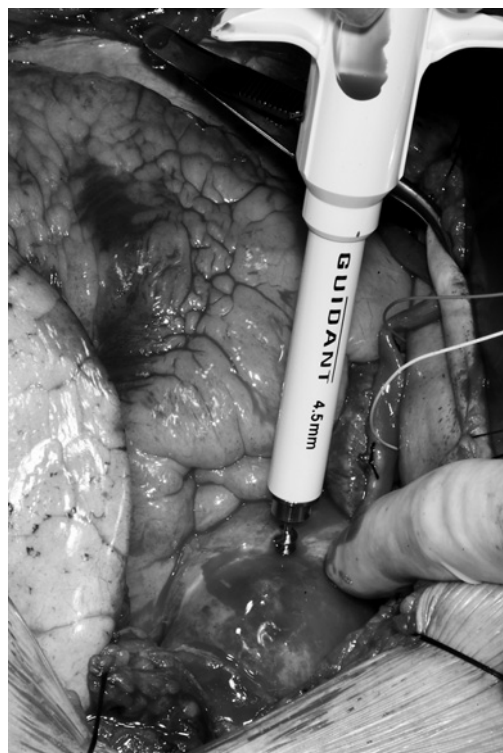


Figure 2. The hole site is created and the aortic punch is carefully rotated into the aorta.

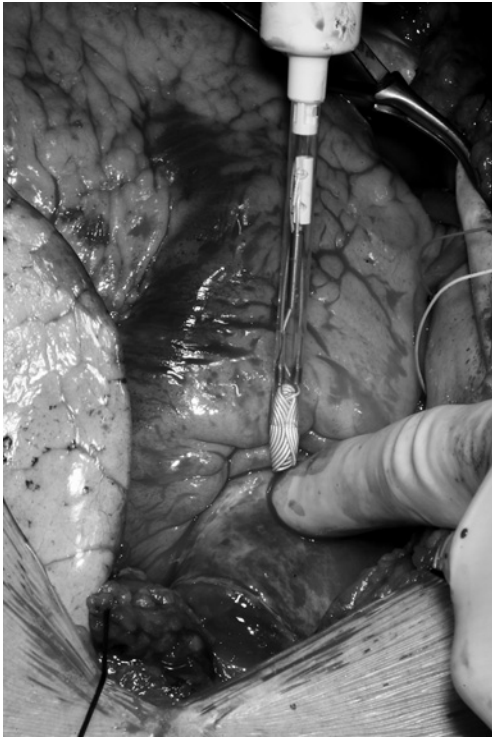


Figure 3. The seal is deployed into the aorta via the punch hole site and provides a sealed region to facilitate the proximal anastomosis.

of the excised aortic tissue from the wound site, after the Guidant aortic punch is activated it has to be removed from the aorta without releasing the plunger. Hemostasis is then provided by digital pressure on the aortic hole. Because of a memory effect of the seal material, the seal must be folded and loaded into the delivery device immediately before application, otherwise maldeployment of the seal will occur. Special care has to be taken at this point to prevent damage to the seal. The seal is then deployed into the aorta via the punch hole site and provides a sealed region to facilitate the proximal anastomosis (Figure 3). The proximal seal covers the punch hole from inside the aorta, providing hemostasis because the blood pressure pushes and a tension spring mechanism pulls the seal against the aortic wall. Mild diffuse bleeding is cleared with a fine suction or a gentle blow mister [Nollert 2003] (Figure 4). Rising of the mean arterial pressure to 70 to 80 mm Hg increases the seal effect and therefore improves the hemostasis. The proximal anastomosis can be performed in a conventional hand-sew technique with polypropylene 6.0 or 7.0 suture for either veins or arteries. Most anastomoses were sewn with Prolene suture 6.0 (Ethicon). The anastomosis can be performed angle independent. Once the anastomosis is finished the seal is unraveled and removed from inside of the aorta by pulling the stem gently (Figures 5 and 6). The suture knot can be tight down and the anastomosis completed with no foreign material remaining other than the polypropylene [Guidant 2002]. The

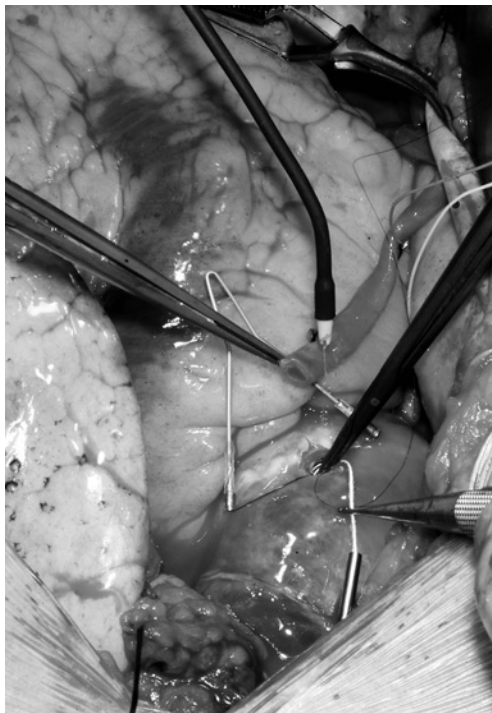


Figure 4. The proximal seal covers the punch hole from inside the aorta, providing hemostasis because the blood pressure pushes and a tension spring mechanism pulls the seal against the aortic wall. Mild diffuse bleeding is cleared with a fine suction or a gentle blow mister.

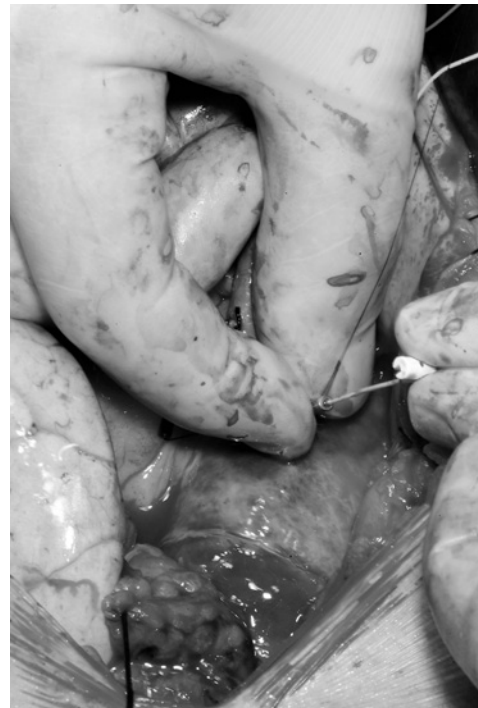

Figure 5. The proximal anastomosis can be performed in a conventional hand-sew technique with polypropylene 6.0 or 7.0 suture for either veins or arteries. Most anastomoses were sewn with Prolene suture 6.0.

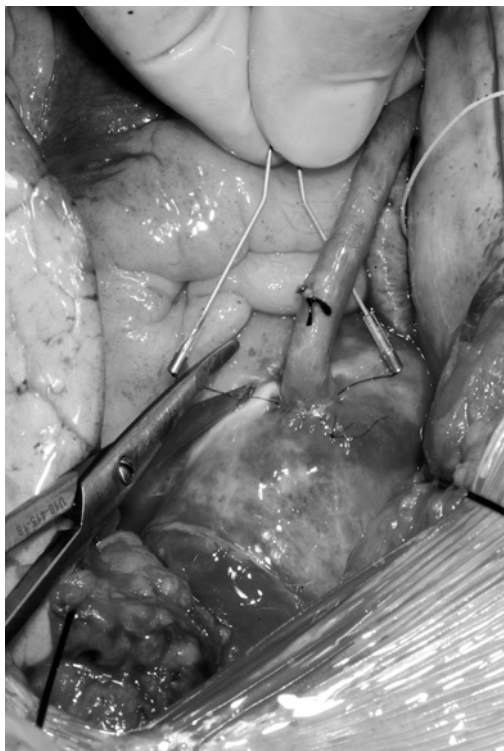


Figure 6. Once the anastomosis is finished the seal is unraveled and removed from inside of the aorta by pulling the stem gently.

proximal bypass graft anastomosis can be performed prior to or after the distal one with equal results.

## RESULTS

A total of 50 Heartstring devices were used to perform an average of 1.7 proximal anastomoses on 29 patients. In 5 patients only 1 proximal anastomosis for 2 vein grafts was performed. In these cases the second vein graft was sewn end to side to the first vein graft. Cracking of the seal prior to deployment happened in 8 cases, mainly during wrapping of the seal and loading the device. For 4 of these 8 damaged seals, the Heartstring device was successfully used to perform the anastomosis. In the remaining 4 cases, a new device had to be used. All anastomoses were performed without any clamping of the aorta. In 7 cases additional remodeling of the punch-hole site by scissors was necessary because of nonclean hole edges due to nonsharp cutting by the punch device. There was no accidental stitching of the seal or wrapping of the suture around the stem while the anastomosis was performed. In 6 cases 1 or 2 additional stitches were necessary to complete a leak-proof anastomosis. All bypass grafts were patent at the end of the procedure. Flow measurement averaged  $53 \pm 23$  mL/min for all grafts. There were no intraoperative or postoperative complications related to the device, no myocardial infarctions, and no deaths. Postoperative transesophageal echocardiographies showed no differences compared to preoperative analysis. The mean time to extubation

was 10.2 hours (range, 4.8-21.3 hours). There were no perioperative ischemic events, and no patient suffered from any neurological complication at discharge (Table 2).

## DISCUSSION

Aside from the use of arterial conduits for in situ or T-graft arterial configurations, the use of proximal anastomotic devices seems to be the most appropriate approach to minimize manipulation of the ascending aorta and therefore reduce the risk for neurologic complications and improve the outcome after off-pump coronary artery revascularization. The Heartstring proximal seal device addresses selectively the question of clampless revascularization without adding new problems derived from the anastomosis technique, which seems to be the drawback of several automatic proximal anastomosis devices currently in development [Reuthebuch 2004]. Basically, this device allows conventional sew techniques with polypropylene suture material and in consequence increases the safety of the system. Compared to other proximal anastomotic devices, the Heartstring system is substantially less invasive. For the use of the Heartstring device it is mandatory to perform one single hole only in the ascending aorta, reducing considerably the potential damage to the aorta and debris induction, specially in calcified aortas, compared to other devices like the Enclose II device from Novare. Additionally, unlike the Enclose II device, the Heartstring procedure does not involve intraluminal shoving of the device along the aorta, so again the potential release of plaques is minimized.

On the other hand, major concerns regarding stenosis of several mechanical or automatic anastomotic devices disappear with the Heartstring device; there is no risk of potential takeoff-angle problems and kinking of the vein. Even more important, there is no foreign material (stent) remaining and therefore there is no stiff vessel portion that can cause additional turbulences that might stimulate intimal proliferation or thrombus and stenosis [Reuthebuch 2004].

In our initial clinical experience the Heartstring was reliable and easy to handle. With this device we produced aortic bypass graft anastomoses equivalent in time and quality to the ones performed with conventional techniques and avoided clamping of the aorta. Another advantage was that the proximal anastomosis could be performed prior to or after the distal anastomosis.

However, we noticed a few limitations that must be addressed. The fact that there is only one size aortic punch (45 mm) requires in some cases additional adaptation and remodeling of the punch hole according to the vein or artery graft diameter. Moreover, because the material of the seal happens to have a memory effect of its 3-dimensional configuration, the seal has to be folded and loaded right before deployment only. In our initial experience all cracked seals occurred during this step, which should if possible be eliminated. A significant improvement would be to have a ready-to-deploy delivery device for which no loading is needed.

As described previously, the proximal seal covers the punch hole from inside the aorta; the blood pressure pushes

and a tension spring mechanism pulls the seal against the aortic wall. Accordingly, the presence of blood while performing the anastomosis and the effectiveness of the seal are blood pressure dependent. Finally, we observed that after Heartstring deployment hemostasis in severe calcified aortas is not as efficient as it is in lower atheroma grades, probably because of the seal rigidity.

In order to find a more extended application, the costs of the Heartstring device should be revised.

This first experience with the Guidant Heartstring proximal seal system is encouraging; however, larger numbers of patients and long-term follow-ups, including angiographies, are necessary to permit a more accurate evaluation.

We believe that proximal bypass aortic anastomoses during off-pump coronary artery revascularization can be performed safely without side clamping using the Guidant Heartstring proximal seal system. This device might constitute an important tool to improve neurological outcomes in these patients.

## REFERENCES

- Angelini GD, Taylor FC, Reeves BC, Ascione R. 2002. Early and mid-term outcome after off-pump and on-pump surgery in beating heart against cardioplegic arrest studies (BHACAS 1 and 2): a pooled analysis of two randomised controlled trials. *Lancet* 359:1194-9.
- Arom KV, Flavin T, Emery RW, et al. 2000. Safety and efficacy of off-pump coronary artery bypass grafting. *Ann Thorac Surg* 69:704-10.
- Guidant Corporation. 2002. Heartstring Proximal Seal System. Instructions for use. Santa Clara, Calif.
- Iaco AL, Contini M, Teodori G, et al. 1999. Off or on bypass: what is the safety threshold? *Ann Thorac Surg* 68:1486-9.
- Lev-Ran O, Loberman D, Matsa M, et al. 2004. Reduced strokes in the elderly: the benefits of untouched aorta off-pump coronary surgery. *Ann Thorac Surg* 77:102-7.
- Matata BM, Sosonowski AW, Galinanes M. 2000. Off-pump bypass graft operation significantly reduces oxidative stress and inflammation. *Ann Thorac Surg* 69:785-91.
- Montgomery DH, Ververis JJ, McGorisk G, Frohwein S, Martin RP, Taylor WR. 1996. Natural history of severe atheromatous disease of the thoracic aorta: a transesophageal echocardiographic study. *JACC* 27(1):95-101.
- Nollert G, Oberhoffer M, Reichart B, Vicol C. 2003. Combination of the heartstring proximal seal system with a blower mister: a possible source of gas emboli. *J Thorac Cardiovasc Surg* 126:1192-4.
- Puskas JD, Williams WH, Duke PG, et al. 2003. Off-pump coronary artery bypass grafting provides complete revascularization with reduced myocardial injury, transfusion requirements and length of stay: a prospective randomized comparison of two hundred unselected patients undergoing off-pump versus conventional coronary artery bypass grafting. *J Thorac Cardiovasc Surg* 125:797-808.
- Reuthebuch O, Kadner A, Lachat M, Kuenzli A, Schurr, U, Turina M. 2004. Early bypass occlusion after deployment of Nitinol connector devices. *J Thorac Cardiovasc Surg* 127(4):1-6.
- Stamou SC, Jablonski KA, Pfister AJ, et al. 2002. Stroke after conventional versus minimally invasive coronary artery bypass. *Ann Thorac Surg* 74:394-9.
- van Dijk D, Nierich AP, Jansen EW, et al. 2001. Early outcome after off-pump versus on-pump coronary artery bypass surgery: results from a randomized study. *Circulation* 104:1761-6.