

# Recommendations for the Implantation of the Pericarbon Freedom Stentless Valve

Sven Beholz,<sup>1</sup> Steven Hunter,<sup>2</sup> Carlos A. Infantes Alcón,<sup>3</sup> Claudio Zussa<sup>4</sup>

<sup>1</sup>Charité–University Medicine Berlin, Berlin, Germany; <sup>2</sup>The James Cook University Hospital, Middlesbrough, United Kingdom; <sup>3</sup>Virgen Macarena Hospital, Sevilla, Spain; <sup>4</sup>Umberto I° Hospital, Venezia Mestre, Italy

## ABSTRACT

Based on our experience of 1000 subcoronary implants of the Sorin Pericarbon Freedom stentless valve, we give recommendations for the exact implantation technique. This article illustrates basic issues in the implantation technique with respect to continuous and interrupted suture to enable beginners and experienced surgeons to avoid some of the pitfalls. Additional remarks about sizing and early intraoperative echocardiographic findings complete this technical overview.

## INTRODUCTION

The Pericarbon Freedom stentless valve (Sorin, Saluggia, Italy), formed of 2 sheets of glutaraldehyde fixed bovine pericardium, detoxified by homocystic acid [Stacchino 1995], has excellent proven hemodynamics in the early and midterm course [Jin 2001, Bonacchi 2002]. The first description of the implantation technique is mainly based on the experience with porcine stentless valves [Westaby 2001], although there are substantial differences resulting from the flexible configuration of this valve. This technical paper represents the experience of 1000 implants performed by the authors and does not focus on clinical results.

## CASE DESCRIPTION

A transverse incision of the aorta, approximately 1 cm above the sino-tubular junction (STJ), is preferable, but a complete transverse aortotomy may be performed in small aortic roots. Thorough decalcification of the annulus and aortic sinuses is mandatory, and exploration of the aortic root with attention to coronary ostia position is mandatory. If the ostia are displaced, the prosthesis should be rotated, avoiding valve distortion.

Received September 4, 2005; accepted September 17, 2005.

Address correspondence and reprint requests to: Sven Beholz, MD, PhD, Cardiovascular Surgery, Charité–University Medicine Berlin, Schumannstr. 20/21, 10117 Berlin, Germany; 49-30-450-522196; fax 49-30-450-522921 (e-mail: [sven.beholz@charite.de](mailto:sven.beholz@charite.de)).

Sizing evaluates the tissue annulus diameter (TAD) and the STJ diameter. No oversizing with respect to the TAD is recommended but proper sizing according to the usually 10% to 15% bigger STJ to avoid central regurgitation. If the discrepancy between the TAD and the STJ does not exceed 2 mm in 19 to 25 sizes or 3 to 4 mm in 27 to 29 sizes, the valve size according to the STJ diameter is chosen. Otherwise, a 2 mm size larger than the TAD is used and the STJ is pliated by means of aortoplasty.

## Implantation

In subcoronary implantation the 2 planes, identified by the nadir of the coronary sinuses and the posts, must remain parallel to prevent the valve from distortion resulting in eccentric regurgitation. The inflow side area may be scalloped corresponding to the membranous septum to reduce the risk of septal perforation.

**Continuous Inflow Suture Line.** Three 3-0 polypropylene sutures are placed about 2 mm below the nadir of left and right coronary sinuses to follow a horizontal line. If the non-coronary sinus is relatively prolapsed, this reference stitch should be placed in a higher position, to maintain the horizontal plane. The sutures are passed through the inflow pericardial skirt in the midpoint of each sinus (Figure 1).

After the valve is inverted into the left ventricular outflow tract (LVOT), the sutures are tied and each half suture is passed in a continuous fashion through the valve and the annulus. The sutures are tied in the space between the prosthesis and the aorta.

**Interrupted Inflow Suture Line.** Eighteen to 24 interrupted single 3-0 braided polyester sutures are passed through the annulus and the valve in a horizontal plane. Each suture can be passed through the annulus and the prosthesis at the same time to make the procedure shorter, or the procedure can be performed in 2 steps, particularly during the learning period (Figure 2).

After the valve is inverted into the LVOT and possible trapped loops have been checked for, the sutures are tied, avoiding excessive traction that may produce tears, mostly in the muscular portion between the 2 coronary sinuses. All sutures will be covered by the prosthesis.

**Outflow Suture Line.** After the valve from the LVOT is everted, the outflow skirt is trimmed to ensure the coronary ostia clearance, including the noncoronary sinus to reduce

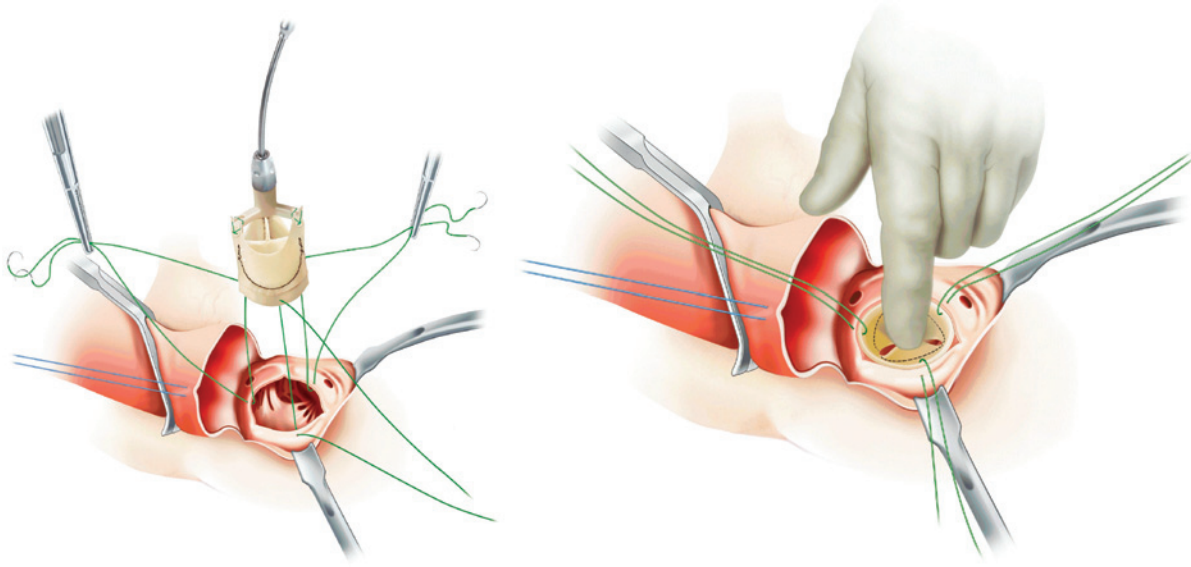


Figure 1. Continuous suture at inflow site.

the hematoma in this area. Using 3 4-0 polypropylene sutures, each post is approximated to the aortic wall. Starting from between the coronary sinuses, the prosthesis is attached to the aortic wall first in the left, then in the non, and finally in the right coronary cusp (Figure 3) to (1) maintain the plane of the commissures parallel to the inflow side with adequate leaflet coaptation; (2) maintain the angular diversion among the commissures; (3) avoid distortion of the leaflets in the commissural areas; and (4) avoid tension on the commissures, instead allowing the prosthesis to lie down on the natural sinuses.

Any suture close to coronary ostia should be radial to the ostia and not to the valve, to avoid stretching the ostia (Figure 4). Before closing the aortotomy, the clearance of the coronary ostia and coaptation of the valve leaflets are checked.

#### ***Intraoperative TEE***

Free movement of each leaflet should be demonstrated. Impaired movement may lead to thrombus formation and thromboembolism and requires immediate revision. One possible reason may be an improper distance between the suture lines, causing unphysiological stress.

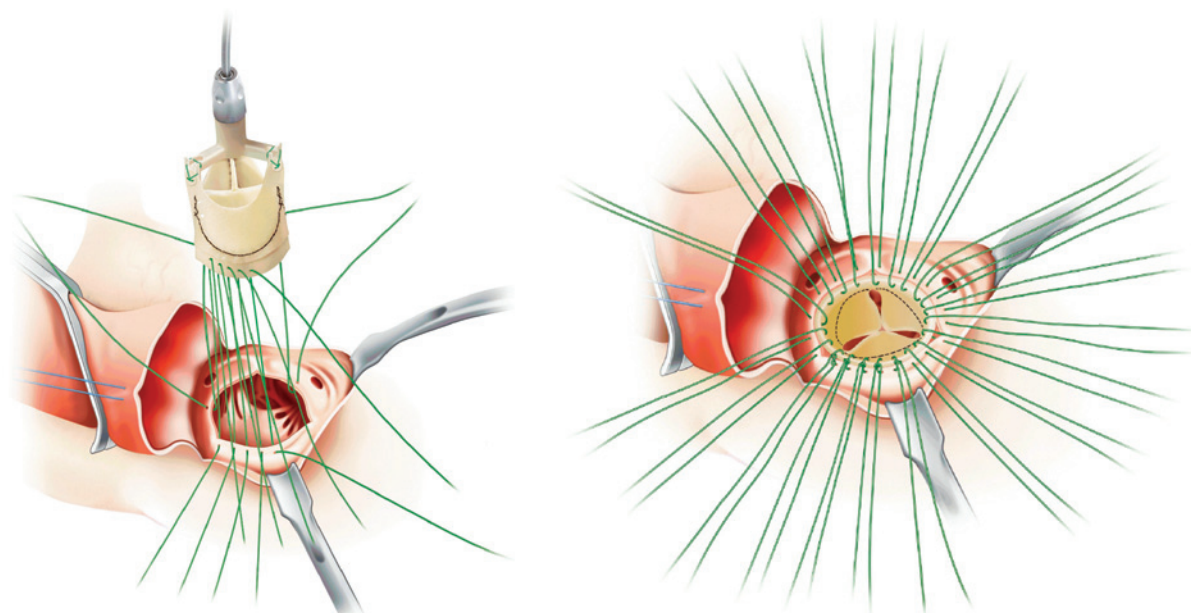


Figure 2. Interrupted suture line at inflow site.

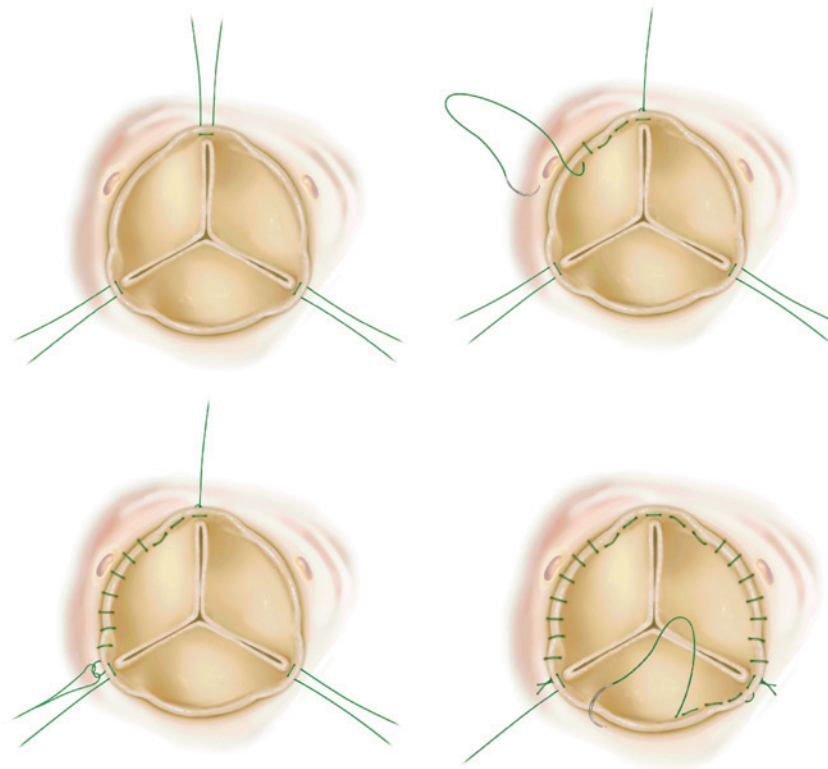


Figure 3. Continuous suture line for subcoronary attachment.

In case of more than a paraphysiological central jet, a prompt revision of the implant should be performed, looking for torn sutures or misaligned commissures. In case of inadequate sizing with a too small prosthesis observed by transeosophageal echocardiography (TEE), a strip of pericardium or felt may be put around the STJ to re-establish leaflet coaptation.

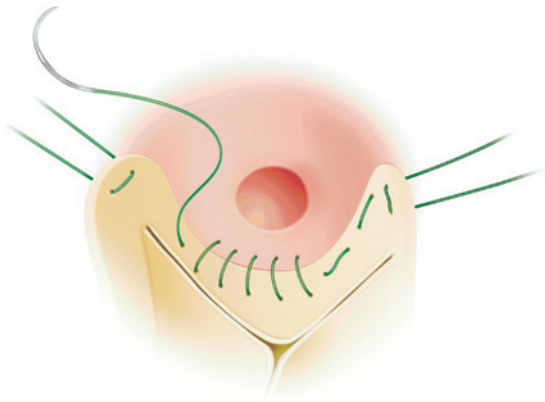


Figure 4. Stitches below coronary ostia radial to the ostium to avoid distortion.

A small wall hematoma is usually present and disappears in about 30 to 40 days. If flow is observed in this hematoma, a revision is suggested to prevent paravalvular leakage.

#### DISCUSSION

Because of its flexible structure, the Sorin Pericarbon Freedom stentless valve is a convenient prosthesis designed for subcoronary aortic valve replacement. Keeping in mind the cylindrical shape and avoiding distortion during implantation, this valve preserves excellent hemodynamics. Intraoperative TEE is mandatory to demonstrate proper valve function, especially in the learning period.

#### REFERENCES

- Bonacchi M, Giunti G, Prifti E, et al. 2002. Early postoperative outcome and hemodynamic performance of the Sorin Pericarbon stentless aortic valve. *J Heart Valve Dis* 11:703-9.
- Jin XY, Westaby S. 2001. Pericardial and porcine stentless aortic valves: are they hemodynamically different? *Ann Thorac Surg* 71:S311-4.
- Stacchino C, Bona G, Rinaldi S, Vallana F. 1995. Design and performance characteristics of the Pericarbon Stentless valve. *J Heart Valve Dis* 4:S102-5.
- Westaby S. 2001. Implant technique for the Sorin stentless pericardial valve. *Operat Tech Thorac Cardiovasc Surg* 6:101-5.