

Aortic Repair Through a Left Thoracotomy in a 12-Year-Old Child with Traumatic Aortic Pseudoaneurysm: A Case Report

Kan Wang,^{1,2} Wenliu Xu,^{1,3} Chaojie Wang,^{1,3} Jiaxin Hu,^{1,3} Songtao Tan,^{1,3} Xiaoping Fan^{1,3}

¹Department of Cardiothoracic Surgery, the Second Clinical College, Guangzhou University of Chinese Medicine, Guangzhou, China; ²Applicants for Equivalent PhD, Guangzhou University of Chinese Medicine, Guangzhou, China; ³Department of Cardiovascular Surgery, Guangdong Provincial Hospital of Chinese Medicine, The Second Affiliated Hospital of Guangzhou University of Chinese Medicine, Guangzhou, China

ABSTRACT

Traumatic pseudoaneurysm of the descending aorta is a rare but life-threatening disease, especially in children. Open surgical replacement and thoracic endovascular repair in treating traumatic pseudoaneurysm to prevent aortic rupture rarely have been reported in children. Here, we present a rare case of aortic pseudoaneurysm caused by trauma in a 12-year-old child treated with an alternative surgical strategy. Aortic repair without an implant assisted by distal perfusion was performed through a left thoracotomy. The child satisfactorily recovered, was discharged, and remained in a good condition during the follow-up period.

INTRODUCTION

Traumatic pseudoaneurysm of the descending aorta in children is a rare but fatal disease with few reported treatment options [Karmy-Jones 2003]. Although open surgical replacement and thoracic endovascular repair have achieved satisfactory results in treating adult aortic pseudoaneurysm [Pang 2019], endovascular stent grafting and synthetic graft replacement rarely have been performed in children, considering the long-term outcome of treatment in children remains uncertain. Here, we report a case of traumatic aortic pseudoaneurysm in a 12-year-old child who was treated with aortic repair assisted by distal perfusion through a left thoracotomy.

Received July 17, 2022; received in revised form August 20, 2022; accepted August 22, 2022.

Correspondence: Xiaoping Fan, Department of Cardiothoracic Surgery, the Second Clinical College, Guangzhou University of Chinese Medicine, Guangzhou, China, and Department of Cardiovascular Surgery, Guangdong Provincial Hospital of Chinese Medicine, The Second Affiliated Hospital of Guangzhou University of Chinese Medicine, Guangzhou, China (e-mail: fukui-hanson@hotmail.com).

CASE PRESENTATION

A 12-year-old boy, 168 cm in height and 57 kg in weight, with a history of a traffic accident injury 7 months prior, was admitted to our department and diagnosed with a traumatic aortic pseudoaneurysm. The accident caused lung, kidney, spleen, and liver lacerations, as well as fractures of the humerus and radius, and the child is recovering well after treatment.

Computed tomography angiography suggested the formation of a pseudoaneurysm in the descending aorta next to the lesser curvature of the aortic arch. (Figure 1) The normal vasculature of the descending aorta was 16 mm in diameter. There was no chest or back pain, no fever, no increased inflammatory markers (C-reactive protein < 0.10mg/l, white blood cell $5.49 \times 10^9/L$), and no obvious abnormalities in a normal liver (alanine transaminase 12U/L, aspartate transaminase 18U/L) and kidney function (creatinine 50 μmol). Electrocardiogram suggested sinus arrhythmia, and there was no obvious abnormality in the echocardiography. The operation was carried out after completing the examination, eliminating contraindications, and discussion of the surgical details with his parents, who then signed informed consent.

Under conventional anesthesia, the patient was placed in the right decubitus position. A fourth intercostal thoracotomy of the left chest was performed, followed by careful separation of the descending aorta. An aneurysm 30 mm in diameter was found in the descending aorta next to the lesser curvature of the aortic arch (Figure 2A). (Figure 2) The ductus arteriosus was ligated and severed (Figure 2B). After heparinization, a pipeline (Figure 3) was used to connect the proximal and distal vessels of the pseudoaneurysm to ensure perfusion of the distal aorta after aorta cross-clamping. (Figure 3) After the descending aorta was blocked, the aneurysm was dissected transversely (Figure 2C), and a few thromboses were found between the middle and adventitia of the aorta. The descending aorta was not involved except for a lesion on the side of the dissected pseudoaneurysm. The diseased vessels were excised, followed by horizontal mattress sutures and continuous sutures (Figure 2D and Figure 2E), which then were reinforced with purse sutures (Figure 2F). Heparin was neutralized with protamine, and the pipeline was removed. Finally, the chest gradually was closed after careful hemostasis.

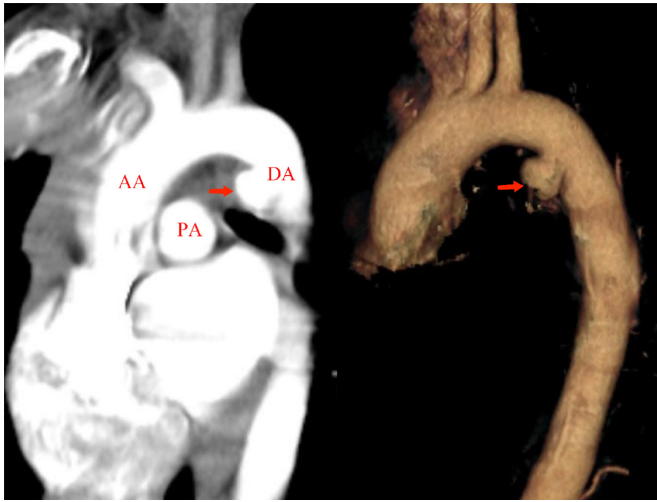


Figure 1. Computed tomography angiography suggested the formation of a pseudoaneurysm (red arrow) in the descending aorta next to the lesser curvature of the aortic arch. AA, ascending aorta; PA, pulmonary artery; DA, descending aorta

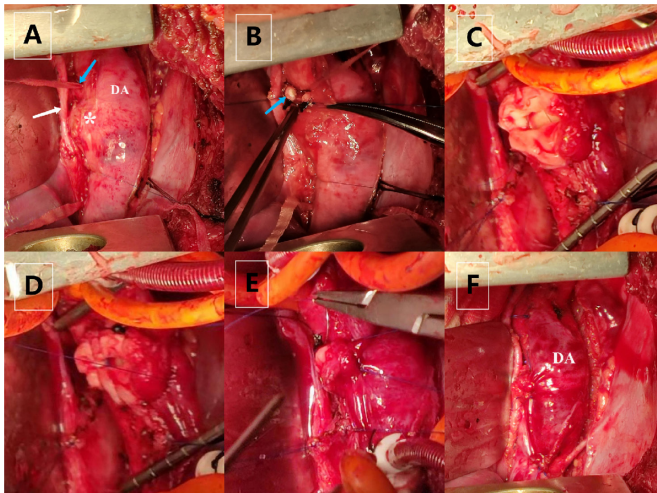


Figure 2. Surgical procedure used for aortic repair. (A) A pseudoaneurysm (asterisk) was found in the descending aorta next to the lesser curvature of the aortic arch. The left recurrent laryngeal nerve is indicated by a white arrow and the ductus arteriosus by a blue arrow. (B) The ductus arteriosus (blue arrow) was ligated and severed. (C) The pseudoaneurysm was dissected transversely. (D) The aorta was sutured using horizontal mattress sutures. (E) The aorta was sutured using continuous sutures. (F) The resection and vascular anastomosis of the pseudoaneurysm were completed. DA, descending aorta

Pathology of the excised vessel showed myxoid degeneration without clear inflammatory infiltration. Postoperative computed tomography angiography showed that the aorta was in good condition without obvious stenosis. (Figure 4) The child recovered satisfactorily without bleeding, infection, paraplegia, or other complications. He was discharged 7 days after surgery and remained without apparent stenosis during the 10-month follow-up period.

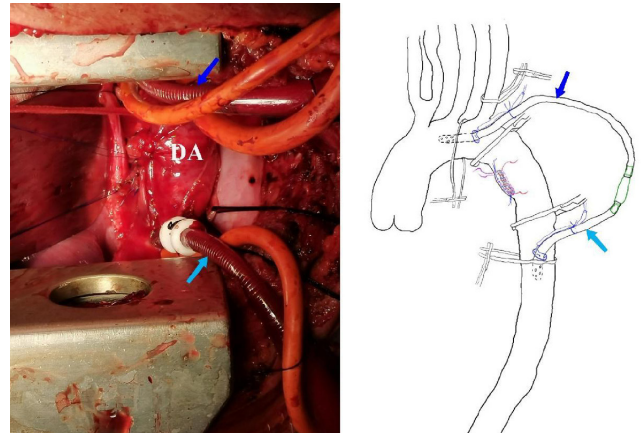


Figure 3. A pipeline (arrow) was used to connect the proximal and distal vessels of the pseudoaneurysm to ensure perfusion of the distal aorta after aorta cross-clamping. DA, descending aorta

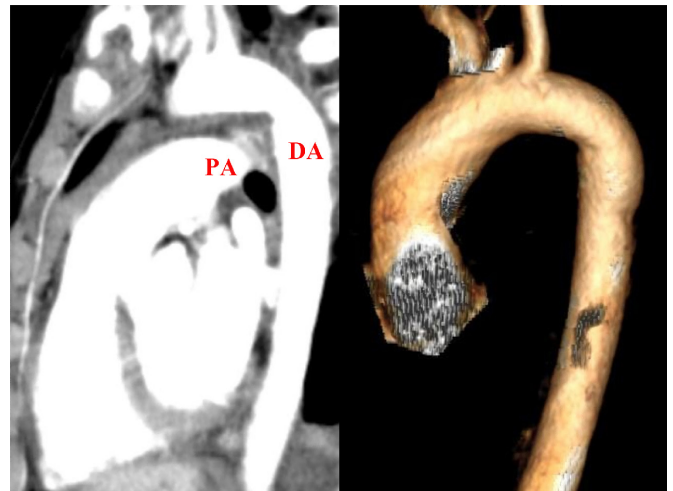


Figure 4. Postoperative computed tomography angiography showed that the aorta was in good condition without obvious stenosis. PA, pulmonary artery; DA, descending aorta

DISCUSSION

Traumatic pseudoaneurysm of the descending aorta is a rare but life-threatening disease, of which the most common site is in the ductus arteriosus region of the descending aorta. Anatomically, the descending aorta far from the ductus arteriosus is relatively fixed, while the aortic arch, ascending aorta, pulmonary artery, and heart are relatively active. When the child received blunt traumatic injuries to the chest, the shear force generated by the inertial forward movement of the aortic arch during the sudden deceleration of the human body led to aortic tearing, resulting in a pseudoaneurysm [Gandhi 2003].

There is no unified treatment for traumatic pseudoaneurysm in children. Although open surgical replacement and thoracic endovascular repair have achieved satisfactory results in adults, endovascular stent grafting and synthetic graft

replacement rarely have been performed in children. Reoperation may be unavoidable, due to the mismatch that develops between the synthetic graft and native vessel as the child grows [Ono 2011]. For pseudoaneurysms of the descending aorta in children, end-to-end anastomosis or direct repair after resection of the diseased site may have better long-term results, due to the absence of a prosthesis and allows the child growth. Although the height and weight of the child are close to an adult, the normal vascular of the descending aorta was 16 mm in diameter and still continues to grow. Therefore, it is still controversial whether endovascular stent grafting is suitable for the child [Karmy-Jones 2003].

In addition, to decrease the frequency of perioperative ischemic complications of distal organs while avoiding the use of extracorporeal perfusion techniques, a distal perfusion pipeline connected to the proximal and distal vessels of the pseudoaneurysm was used during aortic repair in this child. This technique maintains distal aortic perfusion, provides the opportunity to manage complex descending aortic lesions, and minimizes hemodynamic changes during the period immediately after clamping and clamp release [Ouriel 2003].

These findings suggest that traumatic pseudoaneurysm of the descending aorta in children can be treated with aortic

repair assisted by distal perfusion through a left thoracotomy, making it a safer treatment strategy leading to faster recovery. In addition, a synthetic graft was avoided to ensure the long-term prognosis of the child.

REFERENCES

- Gandhi SK, et al. 2003. Traumatic aortic transection in a child with an anomalous right subclavian artery. *Ann Thorac Surg.* 76(6):2087-9.
- Karmy-Jones R, et al. 2003. Management of traumatic rupture of the thoracic aorta in pediatric patients. *Ann Thorac Surg.* 75: 1513-7.
- Ono T, et al. 2011. Open aortic stent grafting and prosthetic bypass in a child. *Ann Thorac Surg.* 92(4):1518-20.
- Ouriel K. 2003. The use of an aortoiliac side-arm conduit to maintain distal perfusion during thoracoabdominal aortic aneurysm repair. *J Vasc Surg.* 37: 214-8.
- Pang D, et al. 2019. Thoracic endovascular repair (TEVAR) versus open surgery for blunt traumatic thoracic aortic injury. *Cochrane Database Syst Rev.* 2(2):CD006642.