

Permanent Atrial Fibrillation is Restored And Sinus Rhythm Maintained Without Catheter Ablation After Atrial Septal Defect Closure: A Case Report

Yuan guo Chen,¹ Peng Wu,¹ Xin Zhao,¹ Yan wu Liu,² Peng Bai,² Haibo Zhang,¹ Ping Ren¹

¹Department of Cardiovascular Medicine, the Ya'an People's Hospital, Sichuan Province, P. R. China; ²Department of Ultrasound, the Ya'an People's Hospital, Sichuan Province, P. R. China

ABSTRACT

Giant atrial septal defect (ASD) often is associated with atrial arrhythmia, such as atrial fibrillation (AF). The recovery rate of AF is very low. Moreover, it is difficult for the intervention of a giant atrial septal defect, and it also is more difficult to perform atrial septal puncture and left atrial appendage (LAA) closure after ASD occlusion. Here, we report a case of a giant ASD and permanent AF. We find that the AF is significantly improved after atrial septal defect (ASD) occlusion and left atrial appendage (LAA) occlusion, which is manifested by spontaneous restoration and maintenance of normal sinus rhythm.

INTRODUCTION

ASD is a common congenital heart disease with a left-to-right shunt on the atrial level. This defect often results in elevated blood circulation in the right heart and lungs, leading to arrhythmia, such as atrial fibrillation, which further aggravates heart dysfunction and increases the risk of stroke. ASD closure can block the left-to-right shunt, thereby reducing the right heart pressure and pulmonary artery pressure and restoring cardiac structure and function. Moreover, the left atrial appendage occlusion, an alternative to long-term oral anticoagulants, can reduce the risk of stroke in patients with atrial fibrillation. Here, we report a case with a giant ASD and permanent atrial fibrillation (AF) that was spontaneously restored after "one-stop shop" operation. The patient regained normal sinus rhythm after operation; the subject gave her written informed consent to publish her case, including the publication of images.

CASE REPORT

The patient was a 42-year-old woman who had a large ASD (Figure 1). She was admitted to the Ya'an People's Hospital with recurrent heart failure symptoms, such as lower limb edema for more than two years. First, echocardiography

indicated that the right ventricle significantly was enlarged with a 40% reduction in ejection fraction (EF) accompanied by moderate mitral and tricuspid regurgitation and accelerated pulmonary artery blood velocity (2.8 m/s). Second, AF was diagnosed by electrocardiogram (ECG) in this patient one year prior (Figure 2). In this case, warfarin, an anticoagulant was not changed, but the international normalized ratio (INR) was fluctuant with a score of CHA2DS2-VASC being 2, which indicates a congestive heart failure. Notably, the patient had a history of gastrointestinal bleeding.

Additionally, cardiac CTA showed significant enlargement of the right heart. The maximum atrial septal defect was 34 mm (Figure 3). There was no thrombosis in the left atrium (LA) and LAA. The landing zones of LAA was 22mm-24mm, respectively (Figure 3).

For surgical treatment, the patient refused thoracotomy to repair ASD. Therefore, we recommended one-stop closure of ASD and left atrial appendage (LAA) because LAA closure can reduce the risk of stroke, and it is a good alternative to prevent stroke in patients with AF. Also, ASD closure

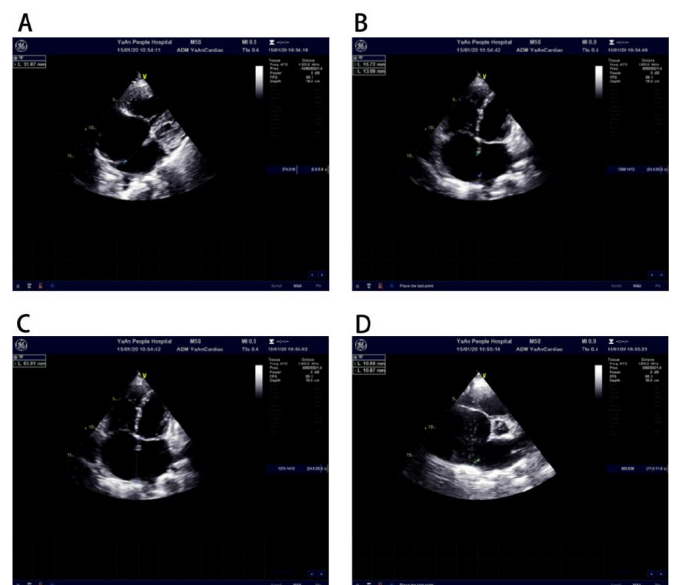


Figure 1. Color ultrasound showing the atrial septal defect was 34 mm (A), which is 15 mm from the atrioventricular valve (B), 13 mm from the pulmonary vein (C), and 10 mm from the aorta (D), which are in line with the indication for ASD intervention.

Received June 22, 2022; accepted July 13, 2022.

Correspondence: Ping Ren, Department of Cardiovascular Medicine, the Ya'an People's Hospital, Sichuan Province, P. R. China (e-mail: 283767641@qq.com).

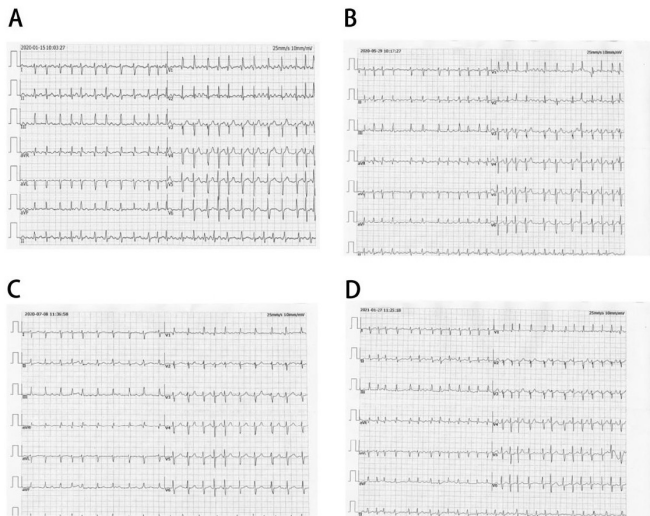


Figure 2. Electrocardiogram showing atrial fibrillation before interventional therapy: more than 1 year before intervention (A); 9 months before intervention (B); 5 months before intervention (C); 10 days before intervention (D).

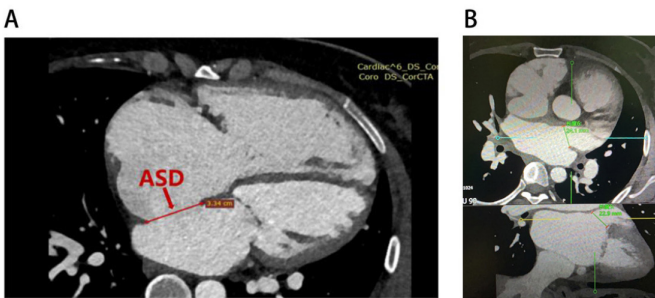


Figure 3. Cardiac CTA showed significant enlargement of the right heart (A) and no thrombosis in the LAA (B).

can block the left-to-right shunt at the atrial level and restore cardiac structure and function. Prior to the operation, the pulmonary to systemic flow ratio was approximately 2.43, and the pulmonary artery pressure was about 43/21(28) mmHg in this patient, which fell in the diagnostic range of massive left-to-right shunt. The operation was performed under general anesthesia and TEE. A 6F multipurpose catheter (Model MPA2) and a 0.035-inch hydrophilic guide wire (Terumo, Tokyo, Japan) were introduced into the pulmonary artery, and a 0.035-inch rigid guide wire (Codis, USA) was placed into the pulmonary vein. Due to the giant ASD, the punctuation of the atrial septal was not needed; however, stabilizing the sheath was a challenge. To circumvent this obstacle, we used a homemade septal occluder (42 mm) through a 14F sheath tube (Shenzhen Xijian Company, Guangdong, China) for trial sealing of ASD (pulmonary vein release method). After the trial sealing, the residual shunt in the atrial septal defect disappeared, the sealing device was in good shape, and the atrioventricular valve and pulmonary vein were not compressed. Additionally, the sealing device was stable as

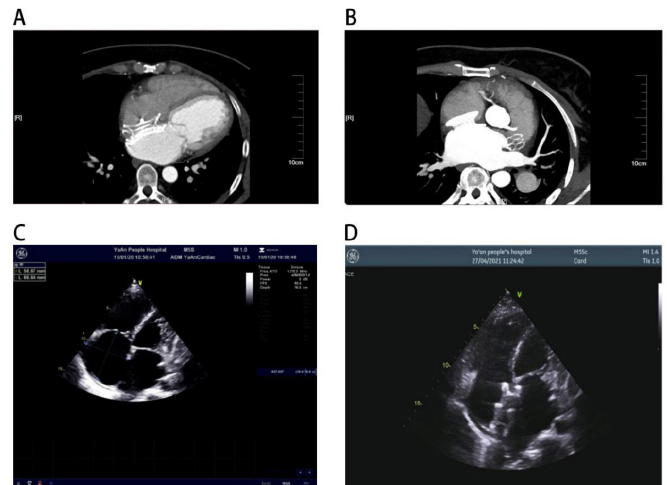


Figure 4. CTA showed significant reduction of the right heart after intervention (A). The atrial septal defect was completely closed, and there was no residual fistula with the left atrial appendage sealing device (B). Echocardiography showed significant reduction of the right heart (C and D).

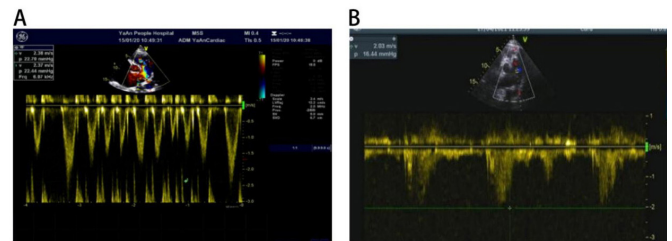


Figure 5. Pulmonary valve flow velocity before intervention (A) and after intervention (B) (m/s).

indicated by the pull test. After successful trial closure, the atrial septal occluder was withdrawn, and the double curved scabbard tube (14F) was exchanged. Next, we performed LAA angiography through this sheath using a 5F pigtail catheter to depict the anatomy and size of the LAA. The maximum LAA was about 22 mm. Based on these measurements, we selected a 27mm occluder (Watchman, Boston Scientific) for LAA closure. The LAA successfully was blocked. After the left atrial appendage occluder was released, the sheath tube was replaced again, and the atrial septal defect successfully was closed by the pulmonary vein release way using the 42 mm occluder. TEE confirmed that the residual shunt was improved, sealing device was in good shape, and the device was released without interventional complications. After that, the sheath tube was pulled out.

After discharge from the hospital, the patient was given rivaroxaban (Xarelto™; Bayer Schering Pharma AG, Berlin, Germany) 20 mg daily by oral administration. After 2 months of occlusion, the ECG of the patient revealed normal sinus rhythm. After half a year, cardiac CTA reexamination suggested that the left atrial appendage occlusion was completely endothelialized, and the size of the right heart returned to normal (Figure 4).

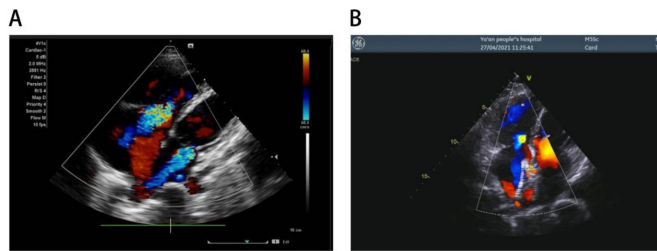


Figure 6. Moderate mitral and tricuspid regurgitation before intervention (A) and mild mitral and tricuspid regurgitation after intervention (B).

Moreover, the velocity of pulmonary valve blood flow markedly was reduced to near normal velocity (1.5 m/s) (Figure 5), tricuspid regurgitation significantly was reduced to a mild level (Figure 6), and sinus rhythm was continuously normal (Figure 7). Considering the significant improvement, we then changed the antithrombotic regimen to replace rivaroxaban with aspirin 100 mg QD for the following recovery.

DISCUSSION

The main characteristics of this case were the anomalously enlarged ASD and permanent AF that significantly were improved by the "one-stop shop" operation. Half a year after the closure of ASD, the oversized right heart had almost returned to normal size, with heart function being much improved, proving that ASD also can be cured by the closure. Therefore, if anatomically suitable, interventional therapy can avoid more postoperative arrhythmias [Magnin-Poull 2005; Yang 2015; Sun 2021], such as incision-related atrial tachycardia [Yang 2015; Sun 2021], atrial flutter, etc. In this patient, the pulmonary artery was strikingly expanded. Since the pulmonary artery is next to the left atrial appendage, left atrial appendage occlusion may damage the pulmonary artery. Due to this intricacy, it is, therefore, particularly important to select an occlusion device of appropriate size. Previous evidence has shown that the risk of atrial arrhythmia is significantly increased in patients with atrial septal defect [Vyas 2020]. However, some studies have shown that atrial arrhythmia cannot be recovered after ASD closure [Vyas 2020; Duong 2017]. So, in this case, the spontaneous restoration and maintained sinus rhythm may be related to the recovery of the right heart size and the reduction of intracardiac pressure, especially in the right atrium. To put it another way, the restoration of AF benefits from ASD occlusion rather than LAA occlusion. At present, catheter ablation is mainly performed for recovering the left atrium, in particular the pulmonary vein. Therefore, catheter ablation is not recommended for structural heart disease complicated with AF [Wang 2019; Nitta 2013].

In this case, AF returned to sinus rhythm, which may have benefited from the following favorable factors. First, the patient's history of atrial fibrillation was relatively short (about one year), and the f waves in the ECG were big enough. Second, the cardiac structure of this patient returned to normal after the ASD occlusion. Third, the patient had no severe pulmonary hypertension. Fourth, the patient was

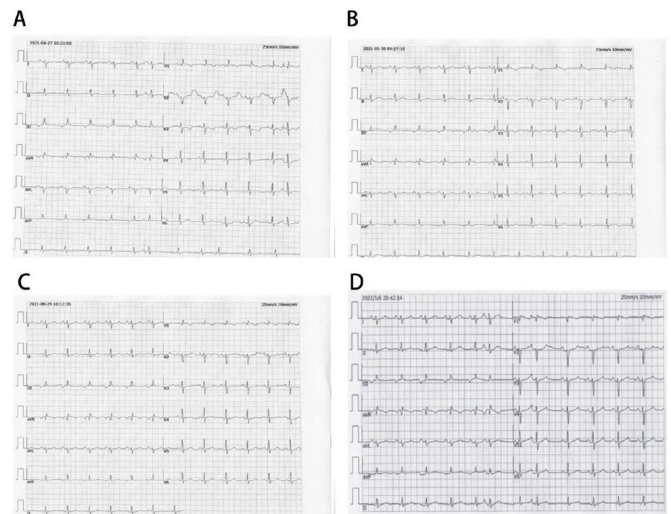


Figure 7. ECG showed sinus rhythm about 2 months after intervention (A); 3 months after intervention, ECG showed sinus rhythm (B); 5 months after intervention, ECG showed sinus rhythm (C); 15 months after intervention, ECG still showed sinus rhythm.

young and had no other chronic diseases. These factors may be conducive to the recovery of sinus rhythm.

Due to the nature of the atrial septal defect, there was no need to puncture the atrial septum during left atrial appendage occlusion, which also reduces the risk of surgical complications and postoperative abnormal embolism. Due to the large surface of the occluder, the risk of thrombosis on the surface of the instrument is high. To prevent thrombosis, we prescribed an anticoagulant (rivaroxaban) for 6 months. It turned out that rivaroxaban effectively prevented thrombosis.

The right atrium and right ventricle dilation is the indicator of the efficacy of interventional therapy for ASD. It is well known that the elevated pulmonary blood flow velocity is not caused by pulmonary stenosis, but instead by the increased blood flow caused by the massive left to right shunt. Thus, the narrowed pulmonary valve is the main etiological risk for ASD. Therefore, the pulmonary artery flow velocity could return to normal after occlusion.

In this reported patient, angiography showed that the left appendage exhibited cauliflower type, indicative of a left atrial appendage occlusion, though CHA2DS2-VASc score is 2 points. Therefore, considering INR fluctuation during oral warfarin and the history of bleeding, it is reasonable for this patient to undergo the "one-stop" intervention for LAA occlusion and ASD occlusion to prevent cardiogenic arterial embolism, a similar intervention that has been reported before [Zhang 2020].

In conclusion, we reported a rare case of a female diagnosed with a giant ASD, which was demonstrably attributed to ASD occlusion. To recover the cardiac structure and function, we successfully performed the "one-stop" intervention for the atrial septal defect and AF. More importantly, the patient's permanent AF was improved, and the normal sinus rhythm was restored and maintained. In the future, we will continue to follow up on the prognosis of this patient.

REFERENCES

- Duong P, et al. 2017. Atrial arrhythmia after transcatheter closure of secundum atrial septal defects in patients ≥ 40 years of age. *Europace*. 19, 1322-1326.
- Magnin-Poull I, De Chillou C, Miljoen H, Andronache M, Aliot E. 2005. Mechanisms of Right Atrial Tachycardia Occurring Late After Surgical Closure of Atrial Septal Defects. *Journal of Cardiovascular Electrophysiology*. 16, 681-687
- Nitta T, et al. 2013. Reentrant and focal activations during atrial fibrillation in patients with atrial septal defect. *Ann Thorac Surg*. 96, 1266-1272.
- Sun H, et al. 2021. Prediction of arrhythmia after intervention in children with atrial septal defect based on random forest. *BMC Pediatr*. 21, 280.
- Vyas V, Kaura A, Sawhney V, Lowe M, Ezzat V. 2020. Atrial tachyarrhythmias following percutaneous device closure of secundum atrial septal defects. *Int J Cardiol Heart Vasc*. 27, 100490.
- Wang H, Wang C, Chen J, Zhao L, Pan X. 2019. Long-term outcome of catheter ablation for atrial tachyarrhythmias in patients with atrial septal defect. *J Interv Card Electrophysiol*. 54, 217-224.
- Yang G, et al. 2015. Prevention of postsurgical atrial tachycardia with a modified right atrial free wall incision. *Heart Rhythm*. 12, 1611-1618.
- Zhang ZH, et al. 2020. "One-stop shop": safety and efficacy of combining atrial septal defect occlusion and left atrial appendage closure for patients with atrial septal defect and atrial fibrillation. *BMC Cardiovasc Disord*. 20, 444.