

## The Use of Suture Anchors for Sternal Nonunion as a New Technical Approach (Demircin-Dogan Technique)

Omer Faruk Dogan,<sup>1</sup> Metin Demircin, MD,<sup>1</sup> Umit Duman,<sup>1</sup> Fatma Ozsoy, MD,<sup>1</sup> Emre Acaroglu, MD<sup>2</sup>

Departments of <sup>1</sup>Cardiovascular Surgery and <sup>2</sup>Orthopaedic Surgery, Hacettepe University Faculty of Medicine, Ankara, Turkey



Omer Faruk Dogan

### ABSTRACT

**Objectives:** Various comparative studies and techniques have been described for median sternotomy closure in the literature, previously. However, some patients are still under risk of sternal dehiscence, malunion or nonunion due to intrinsic or extrinsic factors after median sternotomy closure. Sternal nonunion described as sternal pain, with clicking, instability, or both for more than 3 months in the absence of infection, is an uncommon complication of midline sternotomy incision. To date, only a few studies have addressed the entity of sternal nonunion and its treatment.

**Material and Method:** The suture anchor system has been described for the fixation of tendons or ligaments to the bone in the orthopedic, and then in cardiac surgery for closure of sternum. In the present study, we used different methods for correction and reduction of sternal nonunion with the use of suture anchors and it accompanied steel wires as an alternative technique in a male patient after coronary artery bypass grafting.

**Results:** There was no complication due to suture anchors. Sternal stability, reduction, and fixation were achieved successfully.

**Conclusion:** Sternal nonunion and dehiscence may be the cause of prolonged hospitalization and increased mortality and morbidity if the patient is not treated surgically. This device may protect the wire from cutting into the sternal bone because the thoracic lateral enforcement may be decreased by the devices when the patient is breathing, and with upper extremity movement. This technique can be used easily, safely, and effectively in the repair of sternal nonunion.

### INTRODUCTION

The median sternotomy incision is generally reapproximated with stainless steel wires in a standard fashion after

cardiothoracic surgery. Complications of the sternotomy closure are induration due to local allergic reactions which might deteriorate the comfort of the patient, cause chest pain and sternal nonunion due to the wire from cutting into the sternal bone. Healing complications occur in .3-5% of cases, and are associated with a 14-47% mortality rate if mediastinitis supervenes [El Oakley 1996, Satta 1998]. Optimal sternal wound healing is the result of many different factors. Activity of surgical procedure, obesity, diabetes mellitus (DM), osteoporosis, and prior sternotomy increase the incidence of sternal nonunion. Suture anchors have been first defined in the use of orthopedic surgical procedures such as distal chevron osteotomy [Oznur 2002], fixation of tendons or ligaments to the bone. This system has been reported for the use of sternal approximation in a previous study as a new technique in the literature [Dogan 2004]. Because sternal nonunion is a rare complication, there is no consensus on how to treat these particular patients. Here, we describe a different technical approach for the sternal nonunion with the use of suture anchors in a patient with sterile sternal nonunion developed 3 months after surgery.

### TECHNIQUE

The suture anchor is designed to permit efficient reattachment of the soft tissue to bone. Attachment is secured by anchoring the suture within cortical or cancellous bone. Each of the two free ends of anchored suture is then 'loaded' through the eyelet of a curved free needle. The suture anchor is a self-drilling, self-tapping threaded device. A doubled-strand, braided suture is looped through the eyelet of the anchor. A driver delivers the suture anchor to the desired depth of the bone. Various size anchors are provided for utility, corresponding to the anatomic size requirements. The Statac soft tissue attachment device (Zimmer, Warsaw, IN) assembly is inserted into the Jacob's Chuck of the drill. Drill with driver in place is pulled away from the site. The suture will disengage from the cap, and the driver may be discarded. Excess suture is trimmed after hand tying. The first study of the suture anchors had been applied for sternal closure in two fresh cadavers and one case after coronary artery grafting in our institution. A 56-year-old male patient was referred to our clinic complaining with severe sternal instability, early fatigue, insomnia, irritability on the sternum, and

Received June 28, 2005; received in revised form July 5, 2005; accepted July 7, 2005.

Address correspondence and reprint requests to: Omer Faruk Dogan, Birlik Mahallesi, 59. Sokak, 9/1, 06670, Çankaya, Ankara, Turkey; 90 (312) 495 68 98; fax: 90 (312) 311 73 77 (e-mail: [ofdogan@hacettepe.edu.tr](mailto:ofdogan@hacettepe.edu.tr)).

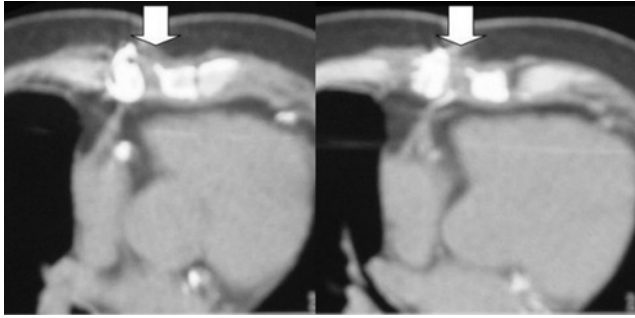


Figure 1. Thoracic computed tomography shows the sternal nonunion and multiple fractures on both sides of the sternum.

dehiscence along the sternum. This patient had been operated for coronary artery bypass grafting in our clinic, previously (before 3 months of this admission). Sternal instability was detected in his physical and radiological examination. Sternum was cut by the surgical steel wires. Sternal nonunion along the sternum and fractured sternal or costal osseal parts were visualized in the thoracic computed tomography (Figure 1). This patient was hospitalized immediately, and surgery was planned with the consultation of orthopedic surgery. After the midline sternotomy incision, all steel wires were removed from the sternum. Mediastinal adhesions were released with the use of an electrocooter. There were fractures in the upper and lower part of the sternum, when the sternum was exposed. Pseudoarthrosis was debrided and fractured bone particles were cleared along the upper and undersurface of the sternum (Figure 2). From both sternal sides, adhesions were released to the left and the right mammary arteries. Sterno-costal junctions were clearly visualized from manubrium to xiphoid. Then, pectoralis muscles were dissected from the sternal edge of about 6 cm of far costo-sternal junctions bilaterally because strong osseous area was clearly visualized for obtaining the sterno-costal junctions (Figure 2). Treatment of dehiscence involves two components: implementation of a lateral reinforcement of the sternum by lacing with wires around each rib parallel to the sternum from the costal margin up to the manubrium, and returning in the opposite direction. The suture is tightened at the bottom end and cut. The maneuver is repeated on the opposite side also to obtain the suitable costal structure forces, and repairing of the sternal fracture (Figure 3). The figure of eight wire sutures were then placed to approximate the sternum. The first and the second suture anchors (Statac®, 5 mm) (Figure 4) angle settled down to the manubrium of the sternum with a drill bit; we implanted the devices on the manubrium approximately 20-25 mm lateral from the edge of the sternum (Figure 5). The metallic part is withdrawn. Totally 10 devices have been fixed strongly to the manubrium and the body of the sternum bilaterally with the aid of a drill bit. Two suture wires were inserted in a figure of eight fashion, and sternum was attempted to reapproximation (Figure 6). Even after attempts to approximate the upper and lower ends of the sternum, there was a space in the mid and lower part of the sternum. Demineralized bony

material was put in these gaps (OrthoBlast II Putty, amount of 10 cc) because of stimulated rapid and complete union (Figure 8). The 2/0 Ethibond double free sutures of the devices were knotted. Application of the free suture ends were then tied up separately and reapproximation was successfully achieved (Figure 7A). After stretching these sutures it was noted that no lateral movement or sliding was observed. After the closure of the sternum, instability was not detected (Figure 7B). In the patient, activity was limited to 8 weeks during recovery from the operation. However, we detected collection in the soft tissue 10 days after surgery. The collection was cleared through skin incision (about 2 cm) under local anesthesia. Fortunately, this collection was sterile, and bacterial colonization was not detected in the laboratory workup. No complications were seen on the post-

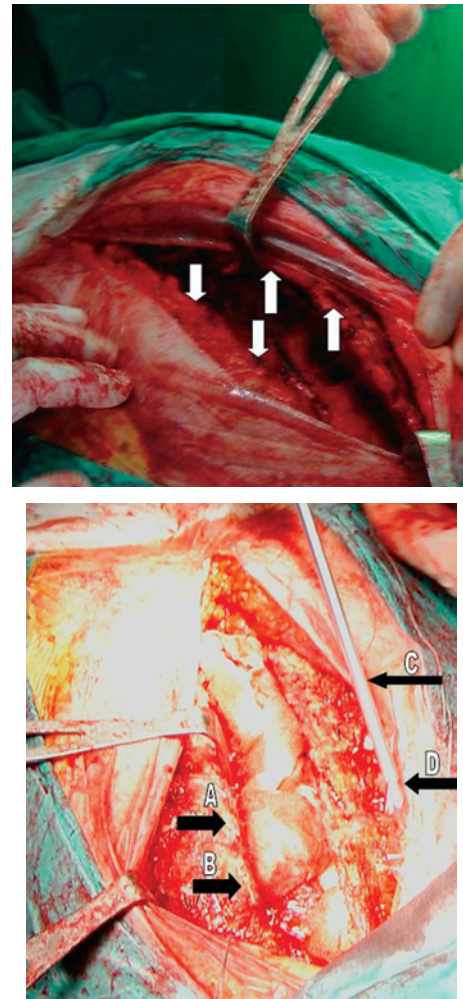


Figure 2. Pseudoarthrosis and fractured bone materials are cleared along the upper and undersurface of the sternum. The edges of the sternum are freed from adhesions, and sterno-costal junctions are shown after removing the fractured bone materials in this picture. A and B Arrowheads indicate cleared sternal edge, and arrowheads C and D indicate the corpus and 5 mm Statac, respectively as parts of suture anchor system.

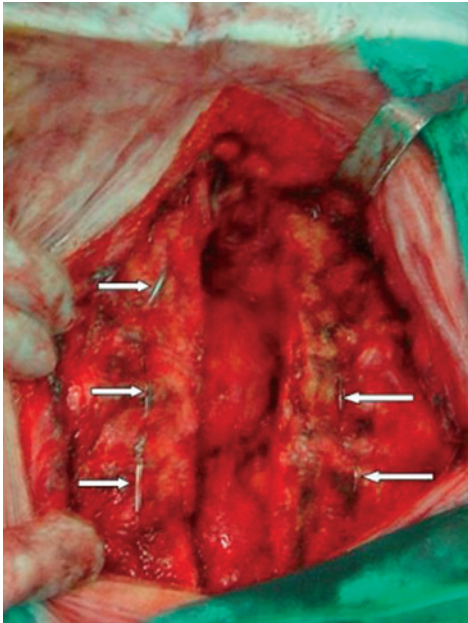


Figure 3. Lateral reinforcement of the sternum by lacing with wires (bilaterally arrowed) around each rib parallel to the sternum from the costal margin up to the manubrium, and returning in the opposite direction. The suture is tightened at the bottom of the sternum.

operative period. The patient became pain-free and had no sternal instability. Figures 8A and 8B demonstrate the suture anchors as lateral and postero-anterior chest x-ray films. There was no sternal nonunion in his three-dimensional thoracic CT examination (Figures 9A and 9B). The patient was discharged from the hospital on the 15th day after surgery in a well clinical condition.

## DISCUSSION

Median sternotomy is one of the most widely used approach for operations in the cardiothoracic surgery. Some patients are under risk of sternal dehiscence, nonunion, and




Figure 4. The suture anchor system is shown. A indicates the Statac® as a suture anchor (5 mm), B indicates the corpus of the suture system, which includes 2/0 Ethibond suture (20 cm in length).

mediastinitis [El Oakley 1996, Satta 1998] though various techniques have been described for sternal approximation, previously [Sirivelle 1987, Hendrickson 1996, Ozaki 1998, McGregor 1999, Dogan 2004]. There is still no consensus among the surgeons on the optimal method for sternal closure when the sternal nonunion is present. In addition, only a few studies have addressed the entity of sternal nonunion and its treatment because this pathologic condition is a rare complication. A few techniques have been developed over the years, including rigid or semirigid type of fixation, with or without bone grafts [Mayba 1985, Hendrickson 1996, Eich 2000, Bertin 2002, Coons 2002]. Wu et al have reported successful surgical treatment of sternal nonunion by use of rigid-plate fixation in their 6 patients [Wu 2004]. Major trauma was the main cause in these cases. In their technique, the exposure required minimal dissection of the periosteal tissue.

Optimal sternal wound healing is affected from many different factors after the cardiac surgery. Activity of surgical procedure, patients' smoking history, obesity, diabetes, and prior sternotomy increase the incidence of wound complications. This complication is a separation of the sternum, which can result in a nonunion and other complications such as mediastinitis. Poor sternal healing leading to sternal separation and dehiscence is a significant complication after sternotomy which occurs in .3-5% of cases [Tavilla 1991, El Oakley 1996, Satta 1998, Wu 2004]. Sternal dehiscence is the cause of patients discomfort, mediastinitis, osteomyelitis, and chronic sternal instability and is associated with a 10-40% mortality rate [Stahle 1997, Goldman 1998].

The suture anchors have been frequently used in orthopedic procedures [Oznur 2002]. These are principally used for the fixation of tendons or ligaments to the bone. However, recently this system has been defined for sternotomy closure [Dogan 2004].

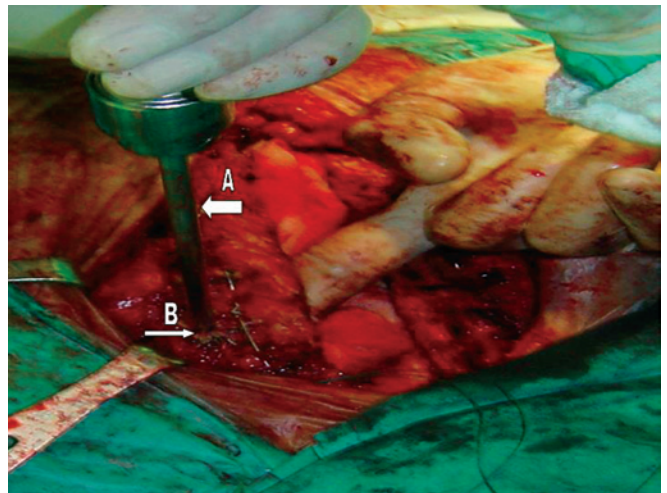


Figure 5. Fixation of suture anchors is performed with the aid of a drill within a strong sterno-costal junction. Digital control is performed due to prevention from laceration of the suture anchor. Arrows A and B indicate the corpus and the 5 mm Statac.

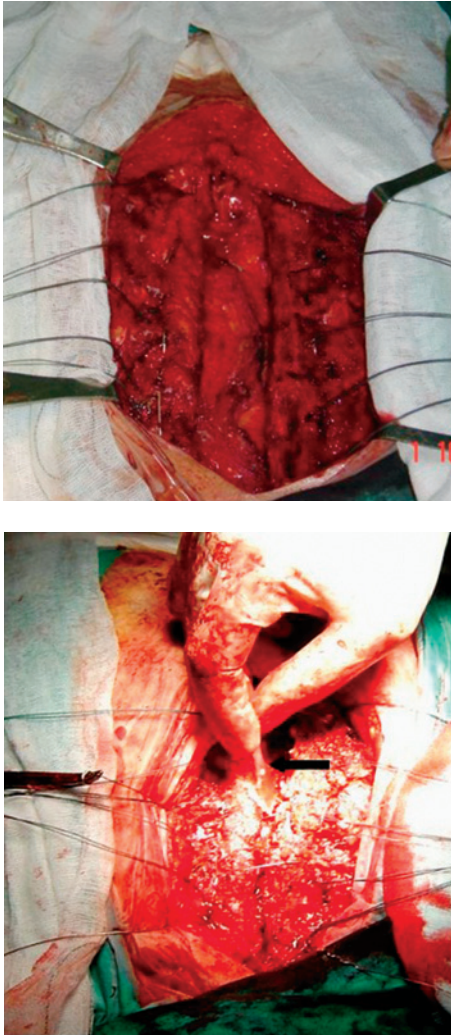


Figure 6. The appearance of the suture anchors (Statac®, 5 mm) to the manubrium after the fixation. The two implanted devices are on the manubrium and the other three are on the body of the sternum, approximately 20-25 mm from the lateral sternal edge. Approximation of the median sternotomy is achieved with the use of suture wires in a figure of eight fashion. Demineralized bone material is filled in the gap, and complete union is achieved.

In the present study, we first described the use of suture anchors accompanied with the stainless wires in the sternal nonunion. Our technique was successful in relieving the pain and healing the sternal nonunion and bony fractures due to the steel wire. The equipment and application technique had been reported previously for the median sternotomy closure [Dogan 2004]. The biomedical studies have demonstrated the superiority of suture anchor systems, and the screw of the anchor is also buried into the intramedullary cavity of the sternum. The present study differs from the previous study in that the use of suture anchor system requires maximal dissection extending to the lateral edges and upper and undersurface of the sternum, and removing of the fractured bony material. The success of the present technique is dependent

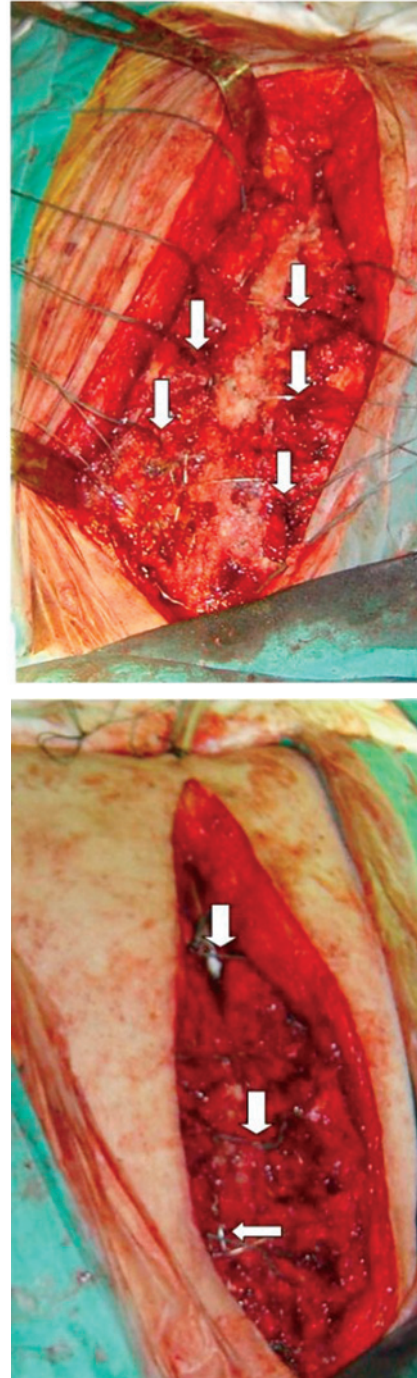


Figure 7. Finally, 2/0 Ethibond-free sutures are knotting.

on the proper reduction of the fractures, suitable and strong bone for purchase of the suture anchor. Shortening of suture anchor was not required because of prevention of significant penetration of the back of the sternum. In addition, this case required the surgical steel wire for obtaining the stability and fixation of the multiple lateral sterno-costal fractures, which would resist the forces of breathing and upper extremity movement. We proposed the demineralized bony material,

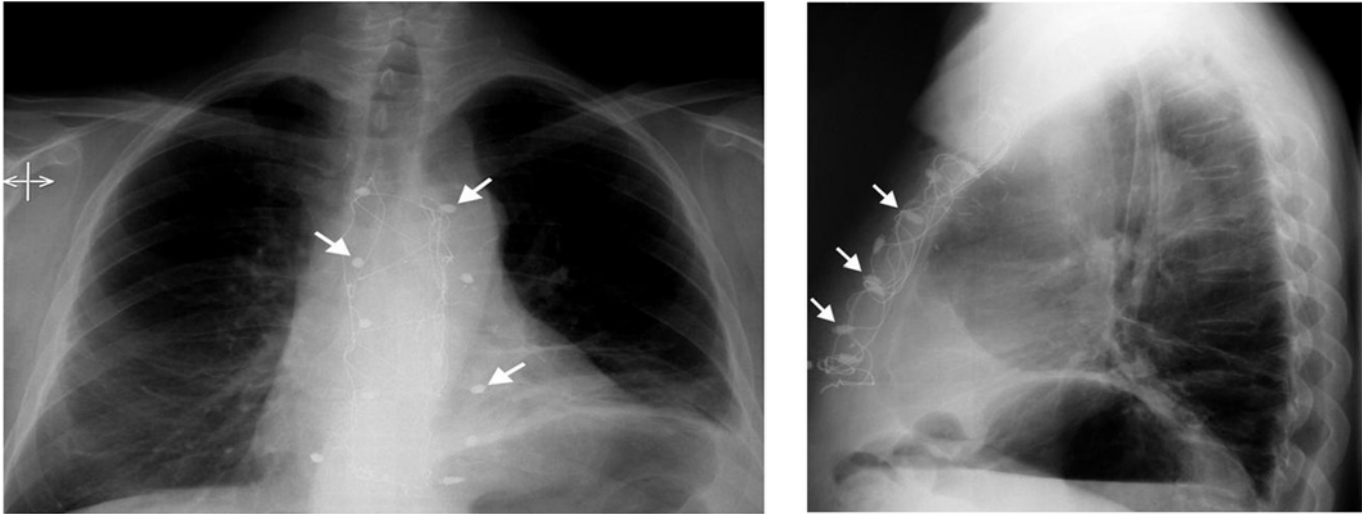


Figure 8. Postero-anterior and lateral chest x-ray films show the suture anchors and the steel wires after 10 days postoperatively. Arrowheads show the Statacs.

not autogenous bone, for the complete healing of the gaps between two sternal edges. So, sternal reapproximation and stability was successfully achieved.

We suggested that the suture anchor provides sufficient decrease of dynamic forces of the lateral thorax with movement of the chest wall during breathing and movement. The sternal or sterno-costal fractures are subjected to forces that tend to distract the fragments. Barber et al compared the suture anchors currently available in terms of modes of failure, ultimate failure strengths, and implant security. Statac suture anchors (5.0 mm) had the highest mean failure strength in cancellous bone compared to other suture

anchors in this study. This suture anchor (Statac 5.0 mm) had significantly better pullout strength, which was 237 pounds [Barber 1995].

The use of these devices may serve protecting the fragmentation of the sternum because of the decrease of dynamic forces of lateral thorax when the patient is moving and breathing. So, this technique may be an alternative and may be used accompanied with the wires when closing a sternotomy with the potential for a major complication, especially in patients with DM, osteoporosis, long entubation time, and reoperation, who are at risk for developing sternal bony destruction due to wire cutting.

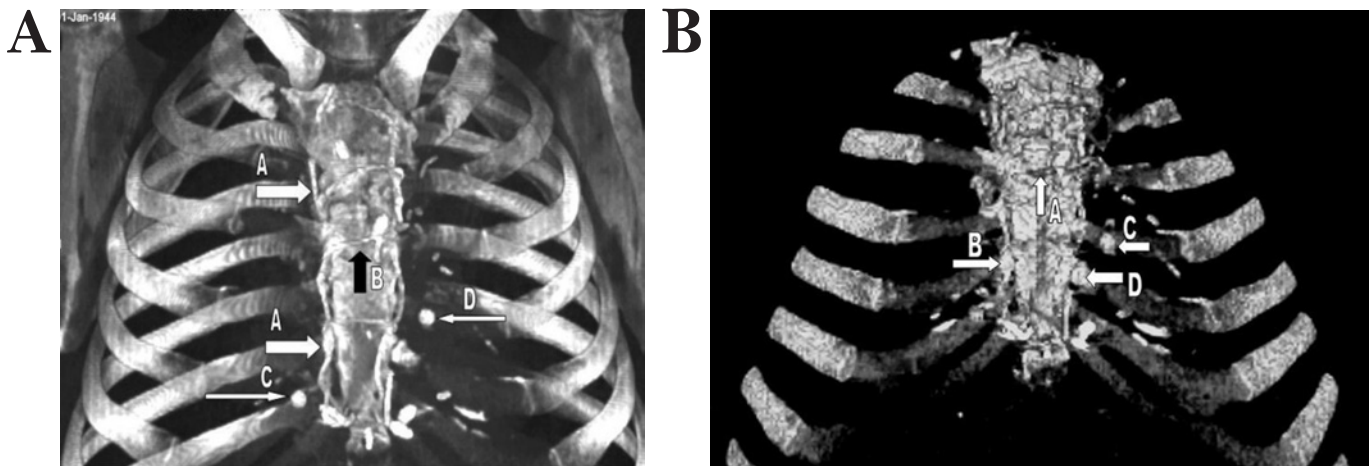


Figure 9. There is no nonunion or gap between the sternal edges in the three-dimensional thoracic CT examination (from anterior (A), and posterior (B) appearances) 15 days postoperatively. The images show how they appear on a 3-D thoracic CT and show the correct placement of the sutures in the post-operative period. Arrowheads A and B display the parasternal wires, and arrowheads C and D demonstrate the wires with a figure of eight fashion from anterior of 3-D CT examination. The other small arrowheads show the suture anchors.

The lack of quality bone in the sternum is an obstacle that must be overcome to achieve effective repair of the injury. We believe that the limitation in quality of sternal bone is addressed by using strong enough material such as an anchor system.

We recommend 5 mm suture anchors (Statac®) which cannot penetrate the posterior aspect of the sternum according to this biomechanical study. Since these suture anchors consisted of Ethibond sutures, they are very easily and quickly removed, especially in the emergency revisions.

We have not observed any complications related to sternal closure when this technique is employed. We recommended this technical approach in patients, who have sternal nonunion, severe osteoporosis, and poor sternal bone quality (metabolic bone disease) since it causes no damage by tension in the weak bone. In summary, especially in cases with sternal nonunion or under risk of mal or nonunion, it will be convenient for the surgeons closing the sternotomy or since this newly generated technique has previously mentioned benefits.

## REFERENCES

- Barber FA, Herbert MA, Click JN. 1995. The ultimate strength of suture anchors. *Arthroscopy* 11:21-8.
- Bertin KC, Rice RS, Doty DB, Jones KW. 2002. Repair of transverse sternal nonunions using metal plates and autogenous bone graft. *Ann Thorac Surg* 73:1661-2.
- Coons DA, Pitcher JD, Braxton M, Bickley BT. 2002. Sternal nonunion. *Orthopedics* 25:89-91.
- Dogan OF, Oznur A, Demircin M. 2004. A new technical approach for sternal closure with suture anchors (Dogan Technique). *Heart Surg Forum* 7:328-32.
- Eich BS, Heinz TR. 2000. Treatment of sternal nonunion with Dall-Miles cable system. *Plast Reconstr Surg* 106:1075-8.
- El Oakley RM, Wright JE. 1996. Postoperative mediastinitis: classification and management. *Ann Thorac Surg* 61:1030-6.
- Goldman G, Nostel R, Spir E, Vidne B. 1998. Effective technique of sternum closure in high risk patients. *Arch Surg* 123:386-7.
- Hendrickson SC, Koger KE, Morea CJ, Aponte RL, Smith PK, Levin LS. 1996. Sternal plating for the treatment of sternal nonunion. *Ann Thorac Surg* 62:512-8.
- Mayba II. 1985. Non-union of fractures of sternum. *J Bone Joint Surg Am* 67:1091-3.
- McGregor NE, Trumble DR, Magovern JA. 1999. Mechanical analyses of midline sternotomy wound closure. *J Thorac Cardiovasc Surg* 117:1144-50.
- Ozaki W, Buchmann SR, Lannetoni MD, Frankenburg EP. 1998. Biomechanical study of sternal closure using rigid fixation techniques in human cadavers. *Ann Thorac Surg* 65:1660-5.
- Oznur A. 2002. A new technique for fixation of distal chevron osteotomy. *Foot & Ankle Int* 23(10):949-51.
- Satta J, Lahtinen J, Raisanen L, Salmela E, Juvonen T. 1998. Options for the management of poststernotomy mediastinitis. *Scan Cardiovasc J* 32:29.
- Sirivelle S, Zikria EA, Ford WB, Samadani SR, Miller WH, Sullivan ME. 1987. Improved technique for sternal closure of median sternotomy incision: mersilene tapes versus standard wire closure. *J Thorac Cardiovasc Surg* 94:591-5.
- Stahle E, Tammalin A, Bergstrom R, Hambreus A, Nystrom SO, Hanssen HE. 1997. Sternal wound complications—incidence, microbiology and risk factors. *Eur J Cardiovasc Surg* 11:1146-53.
- Tavilla G, van son JAM, Verhagen AF, Lacquet LK. 1991. Modified Robisceck technique for complicated sternal closure. *Ann Thorac Surg* 52:1179-80.
- Wu LC, Renucci J, Song DH. 2004. Rigid-plate fixation for the treatment of sternal nonunion. *J Thorac Cardiovasc Surg* 128:623-4.