

Simplified Temporary Right Ventricular Support after Implantation of a Left Ventricular Assist Device

Marien Lenoir,¹ Astrid Quessard,² Anthony N'Guyen,¹ Matthias Kirsch¹

¹Division of Thoracic and Cardiovascular Surgery and ²Anesthesia and Intensive Care Unit, Institute of Cardiology, Université Pierre et Marie Curie, Paris VI, APHP, Groupe Hospitalier Pitié-Salpêtrière, Paris, France

ABSTRACT

Right ventricular failure is one of the most feared complications after implantation of a left ventricular assist device. We provide the technical details for a simplified, percutaneous approach to temporary right heart support.

INTRODUCTION

Right ventricular failure (RVF) is one of the most serious complications following institution of left ventricular assist device (LVAD) therapy and is associated with significant post-operative morbidity and mortality. Approximately 15% of recipients of the latest generation of continuous-flow LVADs will experience RVF. Despite significant improvements in medical management, the use of temporary RV mechanical support is still required in approximately 6% of recipients [John 2010].

The ideal device for temporary RV support should be able to provide complete support for the failing ventricle and maintain antegrade blood flow through the pulmonary vasculature to ensure an adequate LVAD preload. Furthermore, the device should be easy to implant and explant, ideally without general anesthesia and/or reopening of the chest. We recently adopted a simplified technique for the temporary percutaneous RV-support method previously described by other groups [De Silva 2012; Haneya 2012]. In the present report, we detail our approach to the original technique.

SURGICAL TECHNIQUE

The LVAD was implanted in the usual fashion between the left ventricular apex and the ascending aorta while the patient was on cardiopulmonary bypass. The present simplified RV-support technique was used only in patients who experienced overt RVF during or immediately after weaning from cardiopulmonary bypass while the sternum was still open, or in

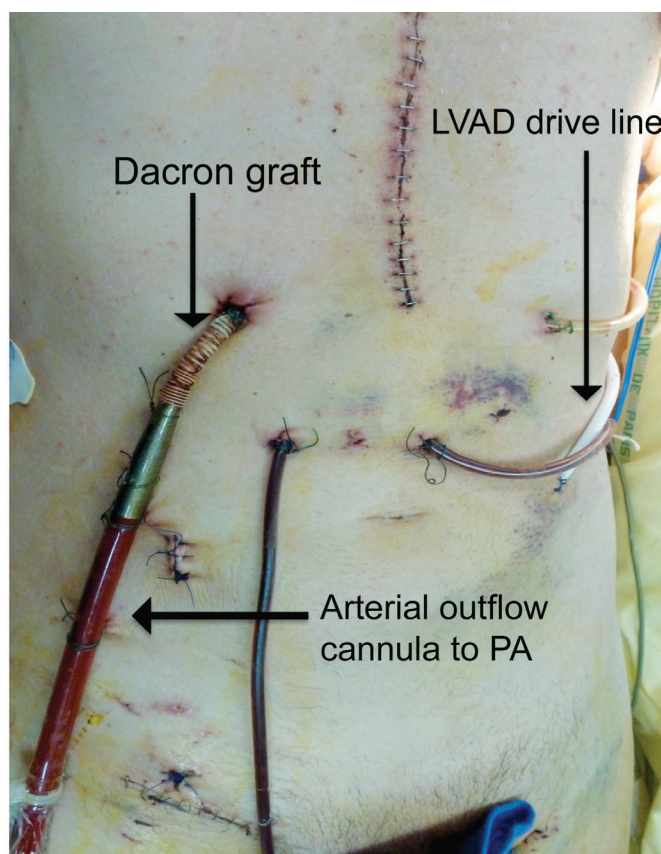


Figure 1. Patient front view with the Dacron graft tunneled under the right costal margin. PA indicates pulmonary artery; LVAD, left ventricular assist device.

patients who were considered at high risk for RVF and for whom temporary RV support was planned preoperatively.

The venous inflow cannula (Biomedicus venous cannula, sizes 24-26; Medtronic, Minneapolis, MN, USA) was placed percutaneously into the right atrium through a femoral vein via the Seldinger technique. For the outflow cannula, an 8-mm Gelweave Dacron graft (Vascutek, Renfrewshire, Scotland, UK) was anastomosed end-to-side to the main pulmonary artery (PA) with a 5-0 polypropylene running suture and

Received January 7, 2013; accepted June 5, 2013.

Correspondence: Pr. Matthias Kirsch, Institut de Cardiologie, Groupe Hospitalier Pitié-Salpêtrière, 47-83 Boulevard de l'Hôpital, 75651, Paris Cedex 13, France; 00-33-1-42-16-56-01; fax: 00-33-1-42-16-56-39 (email: matthias.kirsch@psl.apbp.fr).

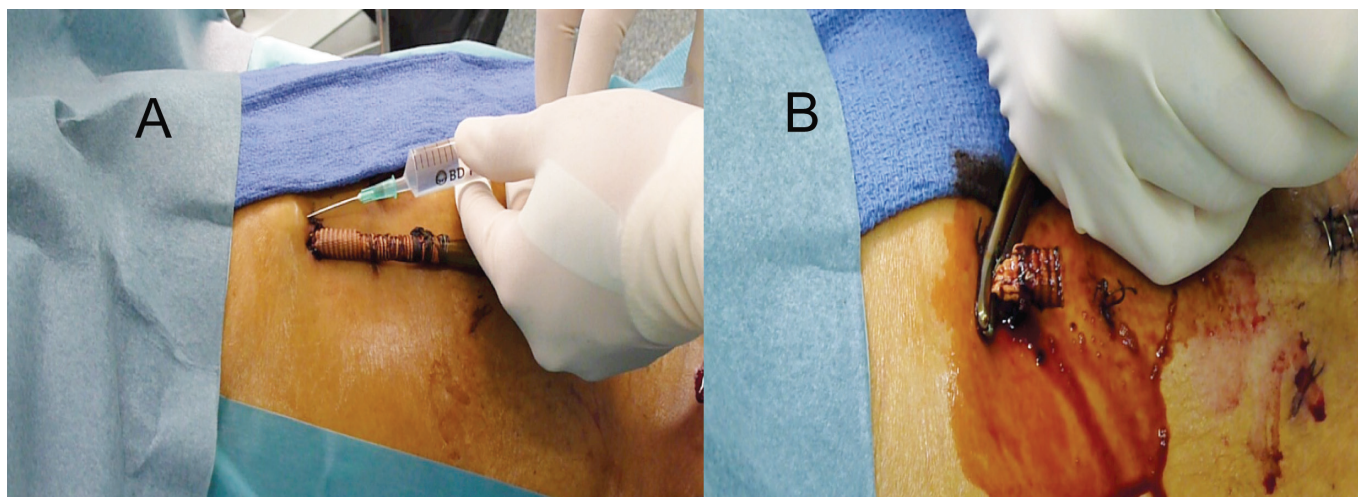


Figure 2. A, Retrieval of the device under local anesthesia. B, Traction on the Dacron graft allowed sterile portions from inside the chest to be exposed.

a Satinsky side clamp. This Dacron graft was positioned in front of the LVAD outflow graft and tunneled under the right costal margin to keep its percutaneous exit site at a distance from the LVAD pump housing and drive line (Figure 1). The outflow arterial cannula (Optisite arterial cannula; Edwards Lifesciences, Irvine, CA, USA) was then inserted into the Dacron graft. The wire-reinforced part of the arterial cannula should be inserted far enough to extend beyond the crossing of the Dacron graft with the LVAD outflow to avoid its compression between the latter and the chest wall. The Dacron graft was then tied tightly around the cannula with umbilical tapes. These ties were applied only to the extracorporeal portion of the Dacron graft to facilitate subsequent decannulation. Both inflow and outflow cannulas were secured firmly to the chest wall with multiple heavy sutures and connected to a centrifugal pump (Rotaflow RF32 centrifugal pump; Maquet Cardiopulmonary, Hirrlingen, Germany). This setup was usually implemented with an oxygenator (Quadrox D oxygenator; Maquet Cardiopulmonary) to assist pulmonary function. The pericardium was reconstructed in front of the LVAD and the Dacron graft with a Gore-Tex pericardial membrane (Gore Preclude pericardial membrane (W. L. Gore and Associates, Flagstaff, AZ, USA) to facilitate sternal reentry at transplantation. The chest was then permanently closed.

After end-organ recovery, patients were evaluated daily for RV recovery. Right ventricular assist device (RVAD) flow was reduced to approximately 1.5 L/min for 15 minutes. RV function was considered recovered when LVAD flow and systemic arterial pressures remained stable without major inotropic support and when a transthoracic echocardiography examination showed satisfactory RV systolic function without RV dilatation. Central venous pressure or other right-sided hemodynamic parameters were not considered, because their interpretation under partial RVAD support is awkward.

Explantation of the device was performed in the operating room. After an ultimate weaning trial, the inflow and outflow lines of the RVAD were clamped. The exit site of the Dacron graft on the skin was widely prepared and draped. After local

anesthesia of the cutaneous exit site, gentle traction on the Dacron graft allowed sterile portions from inside the chest to be exposed (Figure 2). The umbilical tapes were cut, and the arterial cannula was removed. The Dacron graft was clamped at skin level, divided and oversewn with polypropylene sutures, and finally allowed to retract at least 2 cm into the chest. The skin incision was loosely closed with interrupted sutures. The femoral vein was decannulated percutaneously, and manual compression ensured hemostasis at the venipuncture site.

DISCUSSION

Among the several techniques available for temporary RV support after LVAD implantation, we can distinguish 3 approaches, depending on the need to open the chest for implantation and retrieval of the device.

The most conventional approach requires open chest cannulation of the right atrium and the PA and uses pulsatile, centrifugal, or axial flow pumps to support the RV [Sugiki 2009; John 2010]. This approach allows complete unloading of the RV and provides complete antegrade transpulmonary blood flow with an adequate preload for the LVAD. Its major limitation, however, is that general anesthesia and reopening of the sternum are necessary to retrieve the device, which exposes the patient to additional risks of inherent bleeding and infectious complications.

To avoid these limitations, some authors have proposed peripheral venoarterial extracorporeal life support (ECLS) to assist the failing RV [Scherer 2011]. The major advantage of ECLS is that it can be implemented and retrieved rapidly at bedside without opening of the chest. Furthermore, it can provide pulmonary support in patients who are critically ill; however, venoarterial ECLS causes (1) pulmonary shunting with reduced transpulmonary blood flow [Vardi 1995] and LVAD preload, and (2) retrograde aortic perfusion, which increases the LVAD afterload. Therefore, this technique impedes the adequate function of load-dependent LVADs and might increase the risk of pump thrombosis.

Preimplantation Characteristics of the Patients*

Patient No.	Sex	Age, y	Etiology	RVF Risk Score	Preimplantation ECLS	Duration of RV Support, d
1	M	39	Myocarditis	6	Yes	4
2	M	47	Idiopathic DCM	0	Yes	7
3	F	45	Toxic DCM	7	No	10
4	M	42	Idiopathic DCM	6.5	Yes	8
5	F	60	Ischemic DCM	9.5	No	14

*RVF indicates right ventricular failure; ECLS, extracorporeal life support; RV, right ventricle; DCM, dilated cardiomyopathy.

Alternatively, completely percutaneous approaches for isolated RV support have been reported. Takayama et al [2012] use a centrifugal pump connected to an inflow cannula placed from the femoral vein into the right atrium and a flexible outflow cannula introduced from the right internal jugular vein into the PA. This approach requires fluoroscopy, however, and is technically demanding. Recently, an intracardiac percutaneous microaxial blood pump has been proposed for isolated RV support (Impella RP; Abiomed, Danvers, MA, USA) [Haggerty 2012]. It is implanted with fluoroscopy guidance through the right femoral vein. Its inlet area is located in the inferior caval vein, and the outlet is placed in the PA, thereby providing intracardial bypass of the RV. This device remains under investigation, however.

As a compromise, we propose a hybrid solution, in which implantation is made with an open chest but retrieval can be made without general anesthesia and reopening of the sternum. We have used it successfully in 5 HeartMate II (Thoratec, Pleasanton, CA, USA) recipients for a mean duration of 8.6 days (range, 4-14 days). The Table shows the preoperative data. During support, we noted no infections of the cutaneous exit site of the Dacron graft. After weaning, we observed no infectious or thromboembolic complications related to the residual intrathoracic Dacron graft. Similar good results have been reported by others [De Silva 2012; Haneya 2012]. The major limitation of this approach is that it cannot easily be implanted secondarily once the patient is back in intensive care. Considering its extreme ease of retrieval, however, we have significantly reduced our threshold for temporary RV support during LVAD placement.

REFERENCES

- De Silva RJ, Soto C, Spratt P. 2012. Extra corporeal membrane oxygenation as right heart support following left ventricular assist device placement: a new cannulation technique. *Heart Lung Circ* 21:218-20.
- Haggerty CM, Fynn-Thompson F, McElhinney DB, et al. 2012. Experimental and numeric investigation of Impella pumps as cavopulmonary assistance for a failing Fontan. *J Thorac Cardiovasc Surg* 144:563-9.
- Haneya A, Philipp A, Puehler T, et al. 2012. Temporary percutaneous right ventricular support using a centrifugal pump in patients with post-operative acute refractory right ventricular failure after left ventricular assist device implantation. *Eur J Cardiothorac Surg* 41:219-23.
- John R, Lee S, Eckman P, Liao K. 2010. Right ventricular failure: a continuing problem in patients with left ventricular assist device support. *J Cardiovasc Transl Res* 3:604-11.
- Scherer M, Sirat AS, Mortiz A, Martens S. 2011. Extracorporeal membrane oxygenation as perioperative right ventricular support in patients with biventricular failure undergoing left ventricular assist device implantation. *Eur J Cardiothorac Surg* 39:939-44.
- Sugiki H, Nakashima K, Vermes E, Loisanca D, Kirsch M. 2009. Temporary right ventricular support with Impella Recover RD axial flow pump. *Asian Cardiovasc Thorac Ann* 17:395-400.
- Takayama H, Naka Y, Kodali SK, et al. 2012. A novel approach to percutaneous right-ventricular mechanical support. *Eur J Cardiothorac Surg* 41:423-6.
- Vardi A, Jessen ME, Chao RY, Brink LW, Levin DL, Johnson RL. 1995. Effect of extracorporeal membrane oxygenation flow on pulmonary capillary blood flow. *Crit Care Med* 23:726-32.