

# Does Preoperative Multislice Computed Tomography Predict Operative Times in Total Endoscopic Coronary Artery Bypass Grafting?

Thomas Schachner, Gudrun Feuchtner, Nikolaos Bonaros, Armin Oehlinger, Eva Gassner, Guy Friedrich, Alexander Smekal, Guenther Laufer, Johannes Bonatti

Departments of Cardiac Surgery, Cardiology, and Radiology, Innsbruck Medical University, Innsbruck, Austria

## ABSTRACT

**Objective:** Multislice computed tomography (MSCT) is currently discussed as a potential tool for procedure planning in endoscopic heart surgery. We aimed to assess the influence of various thoracic measurements on operative times in arrested heart totally endoscopic coronary artery bypass grafting (AHTECAB).

**Methods:** 34 patients (aged 59 years, 71% male) scheduled for AHTECAB were examined prospectively with ECG-gated 16-channel MSCT angiography of coronary arteries and internal mammary arteries. All AHTECABs were single LIMA to LAD bypass operations using the Da Vinci™ telemanipulator and the ESTECH™ remote access perfusion system.

**Results:** The LIMA–LAD distances were: I (at origin of the first diagonal branch) 4.3 cm (2.5–6.0), II (aortic valve level) 3.7 cm (1.1–6.4), III (mitral valve level) 2.9 cm (0.7–5.0), and IV (basis cordis) 2.3 cm (0.6–4.3). The anteroposterior thoracic diameter was 12.4 cm (8.9–15.6), and the transverse diameter was 24.9 cm (21.1–26.8). LIMA–LAD distances I ( $P = .025$ ,  $r = .396$ ) and III ( $P = .042$ ,  $r = .356$ ) significantly correlated with the anastomotic time. Increased rotation of the heart to the left was associated with a decreased cardiopulmonary bypass time ( $p = .016$ ,  $r = -.451$ ).

**Conclusion:** These data suggest that MSCT has the potential to predict operative times in robotic AHTECAB.

## INTRODUCTION

The 16-channel multislice computed tomography (MSCT) provides a new, non-invasive cardiovascular imaging modality which has already created new perspectives for car-

diac surgery and cardiology in the past few years. CT scans have been discussed as a means of anatomic procedure planning in endoscopic cardiac surgery.

Advanced 16-channel MSCT technology provides high spatial and temporal resolution which allows an assessment of small diameter vessels such as coronary arteries and internal mammary arteries. Beyond this fact, by use of retrospective ECG-gating, nearly motion-artifact free imaging is feasible. Coronary MSCT angiography has been shown to detect significant coronary artery stenoses with acceptable sensitivity and specificity and allows atherosclerotic plaque morphology characterization [Kuettner 2004, Leber 2004, Mollet 2004]. Aside, MSCT permits noninvasive diagnosis of coronary artery disease by quantification of coronary calcium [Becker 1999, Kopp 2004]. In cardiac surgery, MSCT can be used to assess coronary artery bypass graft patency, and to preoperatively evaluate the patients before redo CABG, MIDCAB, and total endoscopic CABG (TECAB) [Cremer 1998, Dewey 2003, Niemann 2003, Yoo 2003, Demaria 2004, Herzog 2004, Martuscelli 2004, Schlosser 2004].

The aim of this study was to assess the influence of various thoracic measurements performed using ECG-gated coronary MSCT angiography, on operative times in arrested heart total endoscopic coronary artery bypass grafting (AHTECAB).

## PATIENTS AND METHODS

The patient characteristics and operative times are summarized in Tables 1 and 2.

### Operative Technique

From October 2001 to December 2004, 34 patients underwent AHTECAB. All AHTECABs were single left internal mammary artery (LIMA) to left anterior descending artery (LAD) bypass operations using the da Vinci™ telemanipulation system (Intuitive Inc., CA). Cardiopulmonary bypass was conducted using the ESTECH™ remote access perfusion system (ESTECH Inc., CA) via cannulation of the left femoral artery. A 23, 25, or 27 F venous return cannula (Biomedicus™, Medtronic Inc.) was placed into the left femoral vein. After balloon endoocclusion of the ascending aorta, cardioplegia was performed with St. Thomas solution. The anastomosis

*Presented at the 2nd Integrated Coronary Revascularization (ICR) Workshop for Interventional Cardiologists and Cardiac Surgeons, Innsbruck, Austria, February 24–25, 2005.*

*Address correspondence and reprint requests to: Thomas Schachner, MD, Department of Cardiac Surgery, Medical University Innsbruck, Anichstrasse 35, 6020 Innsbruck, Austria; 43 512 504 80820; fax: 43 512 504 22528 (e-mail: Thomas.Schachner@uibk.ac.at).*

Table 1. Patient Characteristics and of 34 Patients Undergoing AHTECAB and Preoperative MSCT

Age, y	59 (44-70)
Male gender	71%
Body mass index	26 (19-32)
Preoperative serum creatinine, mg/dL	1.03 (.58-1.53)
Hypercholesterolemia	25/34 (74%)
Diabetes mellitus	3/34 (9%)
Hypertension	28/34 (82%)
Left ventricular ejection fraction, %	60 (40-80)
Angina class (CCSC*)	3 (1-4)
Previous myocardial infarction	11/34 (32%)
EURO score	1 (0-5)

\*CCSC indicates Canadian Cardiovascular Society Classification.

was carried out in a completely endoscopic fashion using 7/0 Pronova (Ethicon). The detailed operative technique has been described by us previously [Bonatti 2004, Schachner 2004].

### MSCT Examination Protocol

Contrast-enhanced MSCT was performed using a 16-channel MSCT scanner (Sensation 16(tm), Siemens Inc., Germany) with the following scan protocol:  $16 \times 0.75$  mm collimation, table feed 6.7 mm/second, gantry rotation time 0.42 second, tube current 500 eff. mAs at tube voltage 120 kV. Radiation dose was approximately 4-5 mSv. 80-100 ml iodine contrast agent (Visipaque 320, Amersham Health) was injected intravenously into an antecubital vein with a 20 gauge cannula and flow rate of 3-4 mL/second by use of a power injector (Urich Inc., Ulm, Germany). Scan delay was calculated by measuring CT attenuation values in the ascending aorta with a dedicated software (DynEva, Siemens) after the injection of a 20 mL test bolus contrast agent (+ 20 mL saline chaser); the time point of the highest CT attenuation was taken as scan delay. Scan direction was craniocaudally during one single inspiratory breath-hold of 20-28 seconds. If the heart rate was >80 bpm, a beta receptor blocker (1-5 mg metoprolol tartrate, Beloc) was given intravenously in order to lower heart rate. The heart rate at the time of examination was 64 (45-89) bpm, and all patients had sinus rhythm. The scan ranged from the aortic arch to the basis cordis. Exclusion criteria were renal dysfunction or other contraindications for application of iodine contrast agent (e.g., known allergy, thyroid disorder).

Table 2. Operative Variables of 34 Patients Undergoing AHTECAB and Preoperative MSCT\*

Duration of TECAB, min	268 (225-355)
LIMA harvesting time, min	48 (35-85)
LIMA to LAD anastomosis, min	33 (23-66)
Cardiopulmonary bypass time, min	112 (72-280)
Aortic endoocclusion time, min	72 (44-153)
Intensive care unit stay, h	23 (11-384)
Hospital mortality	0%

\*TECAB indicates total endoscopic coronary artery bypass grafting; LIMA, left internal mammary artery; LAD, left anterior descending artery.

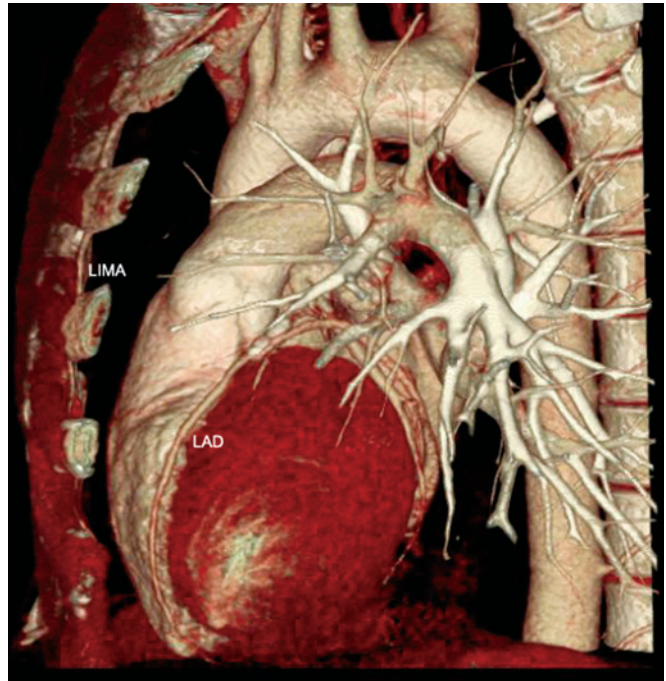


Figure 1. 3D reconstruction of the LIMA and LAD.

### MSCT Image Reconstruction and Analysis

The acquired data set was referenced retrospectively to the ECG-signal, image reconstruction window was set at mid-end diastole (60% of RR-interval) depending on the heart rate. Transaxial slices were generated with an increment of 0.4 (medium convolution kernel B 35 f and smooth convolution kernel B 10 f) and transferred to a dedicated off-line workstation (Leonardo, Siemens Inc., Germany). 3D images were reconstructed with multiplanar reformation (MPR) technique and reviewed by an experienced observer (G.F, Figure 1).

### Definitions of Thoracic Measurements and Operative Times

The distance between LIMA and LAD was measured at 4 transversal images (origin of the first diagonal branch of the LAD (I), aortic valve level (II), mitral valve level (III), and basis cordis (IV)). Compare Figure 2.

The anterior posterior thoracic diameter was measured at the level of the pulmonary artery bifurcation between the posterior wall of the sternum and the anterior wall of the corpus vertebrae. The thoracic ratio was calculated by the division of anterior posterior thoracic diameter/transverse thoracic diameter. The cardiac rotation to the left was defined as the angle between the interventricular septum and the median sagittal line. See Figure 2.

The anastomotic time was calculated from the first stitch of the anastomosis until completion of the last suture knot. The AHTECAB duration was calculated from the beginning of the port placement until completion of the port closure.

### Statistical Analysis

Statistical calculations were performed on SPSS 10.0 statistical software package (SPSS Inc, Chicago, Ill). Continuous

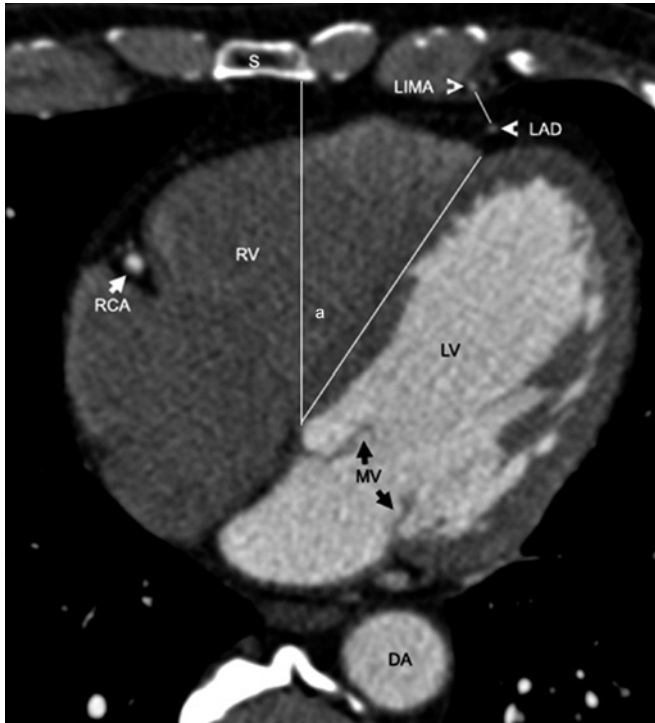

Figure 2. Calculation of the LIMA to LAD distance III (white line), and cardiac rotation angle (a) in MSCT. S, indicates sternum; RV, right ventricle; LV, left ventricle; MV, mitral valve; DA, descending aorta.

variables are given as median and range, and categorical variables are given as absolute values and percentages. For calculation of regression curves models with linear curve fit were applied. Correlations were calculated using Pearson's correlation coefficient (*r*).

**RESULTS**

The various thoracic measurements are listed in Table 3. The LIMA to LAD distance I (at the origin of first diagonal branch of LAD) significantly correlated with the anastomotic time ( $P = .025, r = .396$ , Figure 3).

Table 3. Thoracic Measurements using 16-channel Cardiac MSCT in 34 Patients Undergoing AHTECAB.

*LIMA to LAD distance I, cm	4.3 (2.5-6.0)
LIMA to LAD distance II, cm	3.7 (1.1-6.4)
LIMA to LAD distance III, cm	2.9 (.7-5.0)
LIMA to LAD distance IV, cm	2.3 (.6-4.3)
Minimum LIMA to LAD distance, cm	2.3 (.5-4.6)
Anterior posterior thoracic diameter, cm	12.4 (8.9-15.6)
Thoracic ratio (AP/Transverse diameter)	.51 (.40-.60)
Cardiac rotation to the left, deg	46 (26-59)

\*The distance between LIMA and LAD was measured at 4 transversal images (origin of first diagonal branch of LAD (I), aortic valve level (II), mitral valve level (III), and basis cordis (IV)). LIMA indicates left internal mammary artery; LAD, left anterior descending artery.

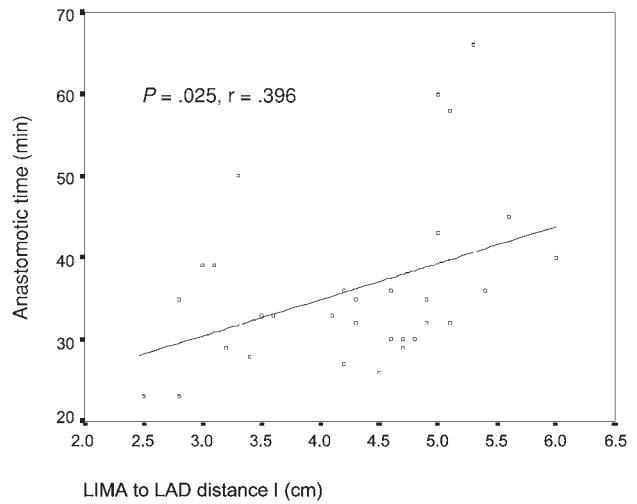


Figure 3. Regression line shows influence of LIMA to LAD distance I on LIMA to LAD anastomotic time in 34 AHTECAB patients undergoing preoperative assessment with MSCT. The regression line is significant ( $P = .025$ ) and follows the function:  $y = 17.16 + (4.43 * \text{distance [cm]})$ , where  $y = \text{anastomotic time [minutes]}$ .

An increased LIMA to LAD distance III (at mitral valve level) was associated with an increased anastomotic time ( $P = .042, r = .356$ , Figure 4).

The following additional correlation was found: The more the heart was rotated to the left side, the shorter was the cardiopulmonary bypass time ( $P = .016, r = -.451$ , Figure 5).

The LIMA to LAD distances II and IV, the minimum LIMA to LAD distance, the anterior posterior thoracic diameter, and the thoracic ratio were not associated with either

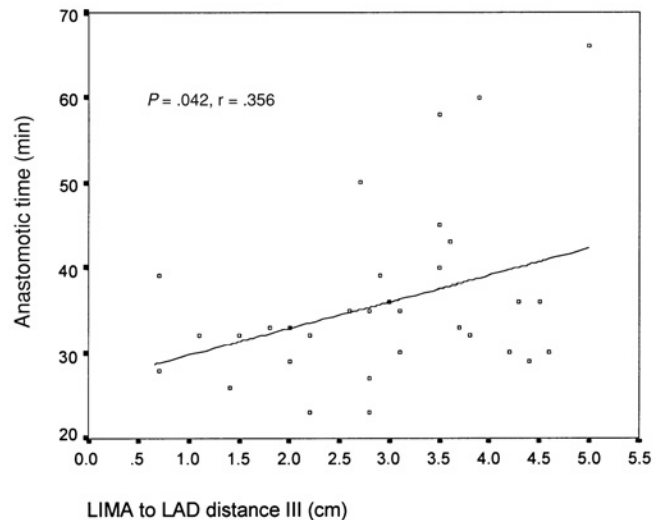


Figure 4. Regression line shows influence of LIMA to LAD distance III on the LIMA to LAD anastomotic time in 34 AHTECAB patients undergoing preoperative assessment with MSCT. The regression line is significant ( $P = .042$ ) and follows the function:  $y = 26.66 + (3.11 * \text{distance [cm]})$ , where  $y = \text{anastomotic time [minutes]}$ .

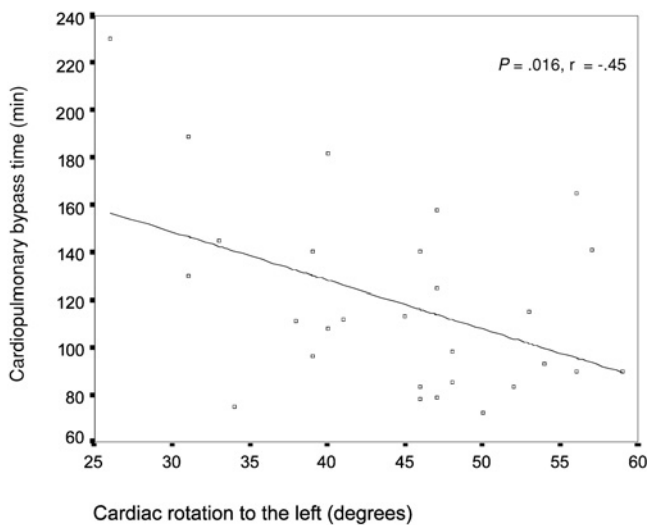


Figure 5. Regression line shows influence of the cardiac rotation to the left on the cardiopulmonary bypass time in 34 AHTECAB patients undergoing preoperative assessment with MSCT. The regression line is significant ( $P = .016$ ) and follows the function:  $y = 209.91 - (2.04 * \text{rotation [degrees]})$ , where  $y$  = cardiopulmonary bypass time [minutes].

cardiopulmonary bypass time, aortic endoocclusion time, anastomotic time, LIMA harvesting time, or AHTECAB duration.

## DISCUSSION

Endoscopic techniques have undergone a rapid evolution in cardiac surgery during the last years [Kappert 2001, Mohr 2001, Dogan 2002, Bonatti 2004]. Robotic technology, such as the da Vinci™ telemanipulator, enables total endoscopic cardiac surgery. Both, beating heart and arrested heart approaches, have been successfully performed. At our institution we favor the arrested heart approach using remote access perfusion via the femoral vessels. Since TECAB is quite a complex procedure, preoperative patient evaluation is essential. MSCT gives a detailed structural information of the thoracic anatomy. First, assessment of the ascending aortic diameter and severity of aortic atherosclerosis is required for the decision if remote access perfusion is feasible or a beating heart TECAB (BHTECAB) has to be conducted. An ascending aortic dilatation and severe atherosclerosis of the aorta are contraindications for the use of femoral access perfusion devices with balloon carrying catheter tips. Second, an intramyocardial course of the LAD can be displayed by MSCT, a fact which may influence the selection of the anastomotic site. However, there is much information for the cardiac surgeon left to be extracted from MSCT.

Preoperative localization of the LIMA by computed tomography has been shown advantageous for adaptation of the minithoracotomy site in MIDCAB [Gulbins 1998, Caimmi 2004]. In our series the LIMA to LAD distance appeared to be a thoracic distance which was associated with prolonged anastomotic time in AHTECAB. The LIMA to LAD distance was typically longer when there was more fatty

tissue between the heart and the sternum (i.e., epicardial fat and tissue in the anterior mediastinum). A more difficult access to a LAD, which is surrounded by a lot of fat, is theoretically one reason why the anastomotic time was longer in patients with a longer LIMA to LAD distance. Another explanation is that if the LIMA is located closer to the LAD the bypass conduit can be placed next to the target vessel easier and without disturbing tensions.

Moreover, we found that an increased rotation of the heart to the left was associated with a decreased cardiopulmonary bypass time. One possible explanation is that endoscopic surgical maneuvers and inspection of the anastomotic site during reperfusion is easier with the heart rotated toward the 3D camera. Additionally, with an increased rotation to the left the apex moves away from the ribs, thus giving more space for the surgeon.

One limitation of this study is the fact that LIMA to LAD distances change with an arrested and unloaded heart. Nevertheless the intersubject difference remains, and influences of the patients anatomy on the operation can be estimated.

## CONCLUSION

MSCT is a promising tool in preoperative evaluation of patients and has the potential to predict operative times in AHTECAB.

## REFERENCES

- Becker CR, Knez A, Jakobs TF, et al. 1999. Detection and quantification of coronary artery calcification with electron-beam and conventional CT. *Eur Radiol* 9:620-4.
- Bonatti J, Schachner T, Bernecker O, et al. 2004. Robotic totally endoscopic coronary artery bypass: Program development and learning curve issues. *J Thorac Cardiovasc Surg* 127:504-10.
- Caimmi PP, Fossaceca R, Lanfranchi M, et al. 2004. Cardiac angio-CT scan for planning MIDCAB. *Heart Surg Forum* 7:E113-6.
- Cremer J, Teebken OE, Simon A, Hutzelmann A, Heller M, Haverich A. 1998. Thoracic computed tomography prior to redo coronary surgery. *Eur J Cardio-thorac Surg* 13:650-4.
- Demaria RG, Vernhet H, Batistella P, Frapier JM, Rouviere P, Alba. 2004. Off-pump coronary artery bypass grafts assessment by multislice computed tomography. *Heart Surg Forum* 7:51-4.
- Dewey M, Lembcke A, Enzweiler C, Hamm B, Rogalla P. 2003. Isotropic half-millimeter angiography of coronary artery bypass grafts with 16-slice computed tomography. *Ann Thorac Surg* 77:800-4.
- Dogan S, Aybek T, Andressen E, et al. 2002. Totally endoscopic coronary artery bypass grafting on cardiopulmonary bypass with robotically enhanced telemanipulation: Report of forty-five cases. *J Thorac Cardiovasc Surg* 123:1125-31.
- Gulbins H, Reichensperner H, Becker C, et al. 1998. Preoperative reconstructions of ultrafast-CT images for the planning of minimally invasive direct coronary artery bypass operation (MIDCAB). *Heart Surg Forum* 1:111-5.
- Herzog C, Dogan S, Diebold T, et al. 2003. Multi-detector row CT versus coronary angiography: preoperative evaluation before totally endoscopic coronary artery bypass grafting. *Radiology* 229:200-8.
- Herzog C, Wimmer-Greinecker G, Schwarz W, et al. 2004. Progress in

- CT imaging for the cardiac surgeon. *Semin Thorac Cardiovasc Surg* 16:242-8.
- Kappert U, Cichon R, Schneider J, et al. 2001. Technique of closed chest coronary artery surgery on the beating heart. *Eur J Cardio-thorac Surg* 20:765-9.
- Kopp AF, Küttner A, Trabold T, Heuschmid M, Schröder S, Claussen CD. 2004. Multislice CT in cardiac and coronary angiography. *Br J Radiol* 77:S87-97.
- Kuettner A, Kopp A, Schroeder S, et al. 2004. Diagnostic accuracy of multidetector computed angiography in patients with angiographically proven coronary artery disease. *J Am Coll Cardiol* 43:831-9.
- Leber AW, Knez A, Becker A, et al. 2004. Accuracy of multidetector spiral computed tomography in identifying and differentiating the composition of coronary atherosclerotic plaques: a comparative study with intracoronary ultrasound. *J Am Coll Cardiol* 43:1241-7.
- Martuscelli E, Romagnoli A, D'Eliseo A, et al. 2004. Evaluation of venous and arterial conduit patency by 16-slice spiral computer tomography. *Circulation* 110:3234-8.
- Mohr FW, Falk V, Diegeler A, et al. 2001. Computer-enhanced "robotic" cardiac surgery: Experience in 148 patients. *J Thorac Cardiovasc Surg* 121:842-53.
- Mollet N, Cademartiri F, Nieman K. 2004. Multislice spiral computed tomography in patients with stable angina pectoris. *J Am Coll Cardiol* 43:2265-70.
- Niemann K, Pattynama PM, Rensing BJ, Van Geuns RJ, De Feyter PJ. 2003. Evaluation of patients after coronary artery bypass surgery: CT angiographic assessment of grafts and coronary arteries. *Radiology* 229:749-56.
- Schachner T, Bonaros N, Laufer G, Bonatti J. 2004. The Estech Remote Access Perfusion Cannula in Minimally Invasive Cardiac Surgery. *Heart Surg Forum* 7(6): E632-5.
- Schlosser T, Konorza T, Hunold P, Kühl H, Schmermund A, Barkhausen J. 2004. Noninvasive visualization of coronary artery bypass grafts using 16-detector row computed tomography. *J Am Coll Cardiol* 44:1224-9.
- Yoo KJ, Choi D, Choi B, Lim SH, Chang BC. 2003. The comparison of the graft patency after coronary artery bypass grafting using coronary angiography and multi-slice computed tomography. *Eur J Cardio-Thorac Surg* 24:86-91.