

## Implantation of CardioWest Total Artificial Heart for Irreversible Acute Myocardial Infarction Shock

M. Morshuis, N. Reiss, L. Arusoglu, G. Tenderich, R. Körfer, A. El-Banayosy

Clinic for Thoracic and Cardiovascular Surgery, Heart and Diabetes Center North Rhine-Westphalia, University Hospital of the Ruhr-University of Bochum, Bad Oeynhausen, Germany

### ABSTRACT

Patients who develop cardiogenic shock after acute myocardial infarction have a very high mortality rate despite early reperfusion therapy. Hemodynamic stabilization can often only be achieved by implanting a mechanical circulatory support system. When, in cases representing expansive myocardial impairment without any chance of recovery, pharmacological therapy and the use of percutaneous assist devices have failed, the implantation of a total artificial heart is indicated. We report our first experiences with this extensive and innovative method of managing irreversible cardiogenic shock patients. The CardioWest total artificial heart was implanted in 5 patients (male; mean age, 50 years). All patients were in irreversible cardiogenic shock despite maximum dosages of catecholamines, an intra-aortic balloon pump and/or a femoro-femoral bypass. In all patients early reperfusion therapy was performed. After implantation of the CardioWest system, all dysfunctional organ systems rapidly recovered in all patients. Four of 5 patients underwent successful heart transplantation after a mean support time of 156 days. One patient died because of enterocolic necroses caused by an embolic event after termination of dicumarol therapy. In summary, our first experiences justify this extensive management in young patients who would otherwise have died within a few hours.

### INTRODUCTION

Cardiogenic shock following acute myocardial infarction remains a complication with a very high mortality rate. In larger studies, the incidence in patients receiving inpatient treatment because of acute myocardial infarction is between 5% and 10% [Bengtson 1992; Moosvi 1992; Holmes 1995]. According to autopsy findings, cardiogenic shock occurs

when more than 40% of the myocardium has been damaged [Harnarayan 1970; Pafe 1971; Alonso 1973]. The loss of the myocardium can be attributed to either a recent extended myocardial infarction or a combination of recent necrosis and previous infarction scarring [Alonso 1973]. Necrosis is an advancing development, with the size of the myocardial area supplied by the occluded coronary artery determining the emergence of left-ventricular pumping failure. Energy reserves in the myocardium are further depleted by the significantly reduced ejection fraction in such a shock situation, and irreversible cardiogenic shock is the ultimate outcome [Gunnar 1988].

Treatment for cardiogenic shock ranges from drug therapy via interventional or surgical reperfusion measures to the implantation of mechanical circulatory support systems. The conservative, purely pharmacological treatment has an extremely high mortality rate of 80% to 90% [Goldberg 1991; Bengtson 1992]. Thrombolytic therapy in patients with cardiogenic shock is also less than convincing and, according to the data available from controlled studies, has not led to any significant improvement in the survival rate [GISSI 1986; GISSI 1990; Holmes 1995; Berger 1997].

However, the prognosis can be positively and significantly influenced through successful coronary angioplasty [Lee 1991; Moosvi 1992]. If reopening the coronary artery is not successful, however, or if there is a repeat occlusion and the patient remains in cardiogenic shock, then sufficient hemodynamic conditions can only be achieved by implanting a mechanical assist device.

The development of ventricular assist devices (VAD) has advanced considerably over the past 2 decades and the following system types are now available: (1) intra-aortic balloon pump, (2) implantable turbine pump (hemopump), (3) centrifugal pump (femoro-femoral bypass), (4) paracorporeal or partially implantable support system, (5) completely implantable total artificial heart [Körfer 1995].

The first 3 of the abovementioned systems can be implanted percutaneously and therefore by cardiologists in the cardiac catheter laboratory. The most significant of these for interventional cardiologists is the intra-aortic balloon pump, which can be implanted easily and quickly in shock patients, and which affects prognosis positively, especially in combination with successful reperfusion [Mueller 1994].

*Presented at the 3rd Integrated Coronary Revascularization (ICR) Workshop for Interventional Cardiologists and Cardiac Surgeons, Innsbruck, Austria, December 6-8, 2006.*

*Correspondence: Prof. Dr. Nils Reiss, Clinic for Thoracic and Cardiovascular Surgery, Heart and Diabetes Center North Rhine-Westphalia, Georgstr. 11, D-32545 Bad Oeynhausen, Germany; 05731/97-3103 (nreiss@gmx.de).*

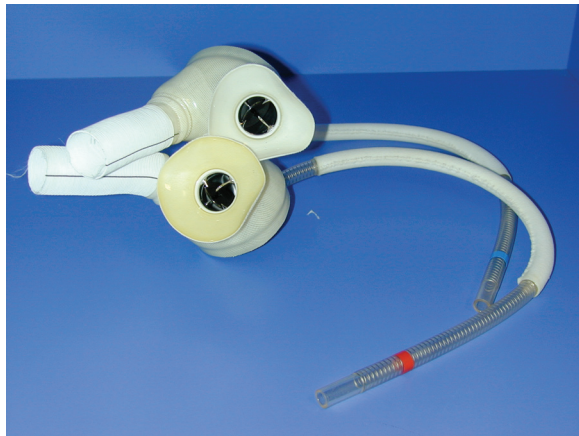


Figure 1. The CardioWest total artificial heart-artificial ventricle with Medtronic-Hall prosthetic valves.

If cardiogenic shock persists despite high-dosage drug therapy and the use of percutaneous assist devices, the implantation of an artificial heart system suited to longer-term support is indicated. This type of VAD can assist one ventricle in isolation or both ventricles. Successful weaning from this system and its use as a bridge to heart transplantation have both been reported [Hill 1986; Moritz 1993; Park 2000].

In a few cases, akinesia of the left ventricle remains despite ventricular assistance. Even with appropriate anticoagulation there is a risk of ventricular thrombosis. In other rare cases, sternotomy reveals severe damage of the myocardium. The myocardial tissue is so fragile that it is impossible to implant a paracorporeal or partially implantable system while leaving the heart as it is. With such a VAD recovery is not to be expected. In both cases, the heart should be replaced and the patient bridged to transplantation with a total artificial heart [Copeland 1996].

In this paper, we report our first experience with this complex and innovative treatment strategy for patients with irreversible cardiogenic shock following acute myocardial infarction.

## METHODS

### *The CardioWest Total Artificial Heart*

The CardioWest total artificial heart (Syncardia Systems, Tuscon, AZ, USA), implanted in all cases, is a direct successor of the Jarvik 7-70 system. It is a biventricular, pulsatile, and pneumatically driven blood pump that is implanted orthotopically. The ventricles are made of polyurethane; Medtronic-Hall artificial valves (Medtronic, Minneapolis, MN, USA) ensure unidirectional flow (Figure 1). Blood and air are separated by a 4-layer polyurethane septum that retreats during the diastole and advances during the systole via compressed air, driving the blood out of the artificial ventricle. The CardioWest system can guarantee flows of up to 10L/min, with normal target flows of 6 to 8L/min. Following implantation of the ventricle, the connecting cable to the drive console is passed out below the left costal arch.

The drive console permits the beat rate, the duration of the systole, and the pressures in the drive lines all to be set individually for each ventricle. The CardioWest system functions on the basis of a complete filling of the ventricles, followed by a complete emptying on each beat. The filling of the ventricles is determined by the atrial pressure on each side; as the atrial pressure increases, the cardiac output and ejection fraction also increase.

### *Implantation Technique*

The implantation technique has been described in detail by Arabia et al [1999]. Here, the most important steps are summarized below.

First the heart-lung machine is connected in the conventional manner. The heart is totally bypassed and then excision begins, using a method that is fundamentally different from that used for transplantation. Both the tricuspid valve annulus and the mitral valve annulus are preserved. Then an incision is made on the ventricular side of the atrioventricular cavity and continued forward across the right-ventricular outflow tract to the proximity of the pulmonary valve. The incision extends backward to the interventricular septum and through the septum, in turn remaining on the ventricular side of the atrioventricular cavity. The incisions are extended from both sides to the pulmonalis bifurcation. The large vessels are then prepared slightly above valve level. Following excision of the heart, the right- and left-atrial cuffs are sutured using Teflon felt.

After this, the large vessels are anastomosed, first the pulmonary artery and then the aorta. The conduits are shortened to the appropriate length. Finally, the artificial heart is carefully vented and positioned. An x-ray of the CardioWest total artificial heart after implantation is provided in Figure 2.

### *Anticoagulation*

Circulatory support using the CardioWest total artificial heart initially caused heparinization with activated coagulation time values corresponding to 1.5 times baseline. After removal

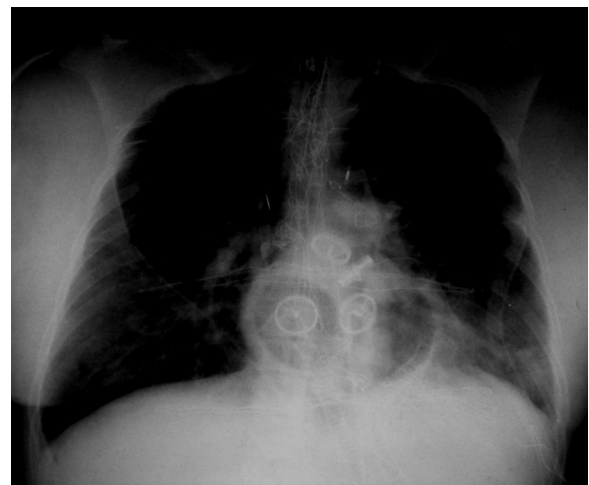


Figure 2. Thoracic x-ray after implantation of a CardioWest total artificial heart.

of the thoracic drainage system, marcumar with target International Normalized Ratio levels of 2.5 to 3.5 was introduced, as well as an additional antiaggregation with 100 mg acetylsalicylic acid.

## RESULTS

### Case 1

A 39-year-old man with extended myocardial infarction was admitted to an outside hospital. There, coronary angioplasty was performed with stent implantations in the proximity of the left anterior descending artery and the circumflex artery. After 3 days the patient required reanimation. Because of acute occlusion of the left anterior descending artery and the circumflex artery, a repeat percutaneous transluminal coronary angioplasty (PTCA) was performed, with stent implantation and lysis therapy. The cardiac index was 1.6 L/min per m<sup>2</sup>.

Still at the other hospital, a Biomedicus femoro-femoral centrifugal pump (Eden Prairie, MN, USA) was implanted to provide hemodynamic stabilization. The patient was then transported to our hospital. Here, surgical myocardial revascularization was performed, with the placement of 2 aorto-coronary venous grafts to the left anterior descending artery and the marginal branch. In conjunction with continued low-output syndrome, the femoro-femoral bypass was retained. After 3 days there was still no indication of myocardial recovery. Severe biventricular dysfunction was observed.

It was decided to implant a biventricular assist device. In the operating theater both the right and left ventricles were akinetic, as well as extensively damaged, with the tissue so fragile as to render the implantation of an assist device to support the existing heart impossible. For this reason, the heart was removed and a CardioWest total artificial heart implanted.

The patient could be extubated on the first postoperative day. After support for 6 days, the previously increased retention levels had returned to the normal range (creatinine from 3 mg/dL to 1.1 mg/dL, urea from 90 mg/dL to 26 mg/dL). The bilirubin level increased on the system to 11.9 mg/dL on the fourth day, after which it continually decreased, entering the normal range after 3 weeks. After a support period of 152 days, the patient was transplanted in a completely mobilized state, free of infection, and with all organ systems recovered.

### Case 2

A 44-year-old patient had severe biventricular dysfunction following an extended anterior wall infarction that was first treated with systemic lysis therapy. After 3 days the patient suffered a repeat infarction. A PTCA was performed with stent implantation in the region of the right anterior descending artery. Five days after this, the patient required reanimation. To maintain adequate circulatory conditions, an intra-aortic balloon pump and a femoro-femoral bypass were introduced. Following hemodynamic stabilization, a repeat PTCA of the right anterior descending artery was performed. Since the patient was still in cardiogenic shock and there were no signs of recovery, implantation of a VAD was

indicated. Sternotomy and pericardiectomy revealed severe biventricular dysfunction. Both ventricles displayed severe myocardial damage. For this reason, it was decided to implant a CardioWest total artificial heart.

Following the intervention, all the organ systems recovered rapidly. On the third postoperative day the patient could be extubated; during the first 14 days the patient still required intermittent veno-venous hemofiltration. Total bilirubin increased to a maximum 10.4 mg/dL before re-entering the normal range after 14 days. The patient could be successively mobilized and was transplanted after 191 days on support in a good general condition and free of infection.

### Case 3

A 59-year-old patient developed severe left-ventricular dysfunction following extended anterior wall infarction in conjunction with severe coronary triple-vessel disease (occlusion of the right anterior descending artery and the right coronary artery, as well as severe stenosis of the circumflex artery). When the patient failed to recover he was transferred to our hospital for implantation of a VAD.

Following placement of an intra-aortic balloon pump, his hemodynamic situation first stabilized but then rapidly deteriorated, so that implantation of a left-VAD (LVAD) was indicated. During surgery, the left ventricle displayed no contractions; the tissue was already clearly fragile. A Thoratec LVAD (Pleasanton, CA, USA) was implanted. Because of the developments described above, the left atrium and the ascending aorta were cannulated rather than the left apex.

Following the intervention, the patient's hemodynamic situation was sufficient, but in the course of the first week increasing right heart failure could be observed, which failed to respond to drug therapy. In addition, the patient was not recovering and developed a thrombus in the left ventricle on the 6th day after device implantation. On the basis of these findings, the implantation of a total artificial heart was indicated.

Following the intervention, veno-venous hemofiltration was carried out as it had been preoperatively and total bilirubin rose to a maximum 5.5 mg/dL. Following extubation, the patient showed a cerebro-organic psychosyndrome that, however, continually improved. Following a 6-week stay in intensive care, the patient could be transferred to a normal ward. Here his general condition improved daily.

After support for 5 months, the patient suffered gastrointestinal hemorrhaging with a significant loss of blood, meaning that conventional dicumarol therapy had to be replaced by intravenous heparinization. A few days later the patient had a transitory ischemic attack. Two days after that the patient complained of severe abdominal pains, and explorative laparotomy revealed necroses caused by an embolic event throughout the intestine. The patient died on the 167th day after implantation of the system.

### Case 4

A 73-year-old patient developed cardiogenic shock in conjunction with extended anterior wall infarction. Coronary angiography performed in an outside hospital revealed severe

coronary triple-vessel disease with a 90% stenosis of the main trunk. The patient required reanimation and an intra-aortic balloon pump was implanted in the cardiac catheter laboratory. Following stabilization, the patient was transferred to our hospital.

Here, the creatinine kinase level on admission was already 4.777 U/L, CK-MB was 274 U/L, and cardiac troponin was 346 mg/L. Surgical myocardial revascularization was immediately performed, with venous grafts sequentially to the right anterior descending artery and the diagonal branch, as well as sequentially to the right posterior descending artery and the right posterolateral branch. It proved impossible, however, to wean the patient from the cardiopulmonary bypass, and severe biventricular dysfunction was observed.

After all the conventional measures had been exhausted, it was decided to implant a CardioWest total artificial heart. The patient could be extubated on the third postoperative day. In the first 10 days he required intermittent veno-venous hemofiltration. The total bilirubin level rose to 15.2 mg/dL on the 12th postoperative day and did not re-enter the normal range until 6 weeks after implantation. On the 13th postoperative day, the patient could be transferred to a normal ward. After support for 180 days he was then transplanted in a very good general condition.

**Case 5**

A 36-year-old patient with extended myocardial infarction and cardiogenic shock underwent coronary angioplasty in an outside hospital, with stent implantation of the right anterior descending artery and the circumflex branch. During this intervention the patient required reanimation. Since he remained hemodynamically unstable even after the intervention, an intra-aortic balloon pump was implanted. The patient was then transferred to our hospital. Here, echocardiography revealed an ejection fraction of 16% and a cardiac index of 1.5 L/min per m<sup>2</sup>. Creatinine kinase was 4.524 U/L, CK-MB was 346 h/L, and cardiac troponin was 596 µg/h.

Despite extensive pharmacological therapy and the intra-aortic balloon pump, adequate hemodynamic conditions could not be achieved, so the patient was brought to the operating theater for implantation of a VAD. Here it was discovered that the entire left ventricle was massively infarcted. A CardioWest total artificial heart was implanted.

The patient could be extubated on the third postoperative day. After support for 6 days, both the retention and the bilirubin levels were within the normal range. Lipase increased to 1.200 U/L but no organic correlation could be found using sonography. After 101 days on the system, the patient could be transplanted in a completely mobilized, infection-free condition with all laboratory parameters normal.

**DISCUSSION**

In the last few decades, the mortality rate for acute myocardial infarction has been significantly lowered through the further development of drug, interventional, and surgical therapies. Despite these therapeutic options, a low percentage of infarction patients (~7%) develop cardiogenic shock [Vogt 1999]. This patient group has an extremely poor prognosis and a hospital mortality rate of 60% to almost 100%. An improvement in survival has been reported through rapid reopening of the infarcted vessel with PTCA or operative myocardial revascularization [Beyersdorf 1990; Allen 1993].

The restoration of adequate blood flow may limit the size of the infarction, prevent infarction extension, or improve the function of the remaining myocardium [Grines 1989], but once the patient is already in cardiogenic shock it is usually too late to save the myocardium within the infarcted area. The patients are often still young—in our study averaging 50 years—and yet have barely any chance of surviving. The only remaining therapeutic option to restore sufficient circulation is the implantation of a mechanical VAD.

Mechanical circulatory support devices are mainly implanted in patients with terminal heart failure as a bridge to

**Patient Characteristics**

	Patient 1	Patient 2	Patient 3	Patient 4	Patient 5
Sex	M	M	M	M	M
Age, y	39	44	59	73	36
Weight, kg	77	85	72	80	95
Body surface area, m <sup>2</sup>	1.9	2.09	1.88	2.00	2.20
Reanimation	Yes	Yes	No	Yes	Yes
Intra-aortic balloon pump	No	Yes	Yes	Yes	Yes
Femoro-femoral bypass	Yes	Yes	No	No	No
Respiration	Yes	Yes	Yes	Yes	Yes
Ejection fraction, %	18	20	25	20	16
Cardiac index, L/min/m <sup>2</sup>	1.6	1.8	1.6	1.7	1.5
Intervention	PTCA + stent LAD/Cx, re-PTCA + stent LAD/Cx + lysis therapy double CABG	PTCA + stent LAD, lysis therapy, re-PTCA LAD	PTCA + stent LAD, initial implantation of a Thoratec LVAD	Quadruple CABG	PTCA + stent LAD/Cx

\*PTCA indicates percutaneous transluminal coronary angioplasty; LAD, left anterior descending artery; Cx, circumflex artery; CABG, coronary artery bypass grafting.

heart transplantation [Farrar 1990; Körfer 1995]. Cardiogenic shock following acute myocardial infarction is a more rare indication for the implantation of an assist device [Page 1971; Zumbro 1987; Moritz 1993; Chen 1999; Körfer 1995; Reiss 1995].

Assist devices provide the options of supporting the damaged heart or completely replacing it. Numerous systems are currently available, ranging from the intra-aortic balloon pump via centrifugal and roller pumps and VADs to the total artificial heart. The standard options are to use the system until the patient can be weaned or as a bridge until heart transplantation. The percutaneous systems such as the intra-aortic balloon pump and the centrifugal pump are only suited to short-term support. The prognosis following weaning is poor, however, with survival rates between 0% and 35%, meaning that ultimately the only options with a better prognosis are the use of VADs or replacement of the heart with a total artificial heart [Raithel 1989; Reichmann 1990; Kern 1993; Zeymer 1993; Chen 1999].

Most reports are of isolated left-heart support. Myocardial infarctions primarily restrict left-ventricular output; the implantation of an LVAD thus often appears to be the adequate solution to achieve sufficient circulation. The first system that was used as an LVAD in patients with cardiogenic shock following myocardial infarction was the Thoratec system [Hill 1986]. The patient could successfully be transplanted after being supported on the system for just 2 days.

Chen et al reported their experience with the HeartMate LVAD in conjunction with acute myocardial infarction. Their bridge-to-transplant rate was 64%. Only one patient could be successfully weaned [Chen 1999]. Similarly low weaning rates were also reported by other groups [Park 2000].

With isolated left-heart support 2 significant problems occur [Park 2000]. First, some patients (up to 30%) experience right-heart failure. Second, approximately 30% to 40% of patients develop malignant ventricular arrhythmias [Moritz 1993; Chen 1999; Park 2000]. The implantation of a biventricular support system or a total artificial heart can prevent the abovementioned problems from developing. The biventricular assist device is, however, inferior to the total artificial heart in cases involving irreversible cardiogenic shock. First, the total artificial heart is capable of guaranteeing higher pump flows of up to 10 L/min. Unlike patients with chronic heart failure, patients suffering from acute cardiogenic shock are not used to reduced perfusion of the vital organs; in our experience with both forms of circulatory support, the higher pump flows are crucial to subsequent organ system recovery in these patients. In addition, previously applied toxic doses of catecholamines can be completely discontinued, also preventing secondary organ damage. Second, if the myocardium fails to recover after use of a VAD, there is a risk of ventricular thrombosis. We observed this phenomenon in our third patient, in whom we initially implanted a Thoratec system in the hope that this option would enable him to recover. This, together with right-heart failure, was cause for us to remove his heart and implant a CardioWest system.

One disadvantage of the CardioWest system should not




Figure 3. Patients during mobilization on the CardioWest system.

remain unmentioned. The drive console is considerably larger than that of the various VADs available. During the rehabilitation and mobility phases, patients have difficulty moving around without help (Figure 3).

In this paper we have reported our first experiences with the total artificial heart in patients with irreversible cardiogenic shock following myocardial infarction; ie, an extreme form of cardiogenic shock that cannot be treated pharmacologically, interventionaly, or with percutaneous assist devices. The marked fragility of the myocardium rendered it impossible to implant a paracorporeal or partially implantable system with the option of weaning on recovery.

The results of this management strategy, which is extensive regarding both financing and personnel, are extremely encouraging. Four of 5 patients who otherwise would certainly have died within the next few hours were successfully transplanted following a mean support period of >5 months. Regretfully one patient died after 167 days on the system because of enterocolic necroses caused by an embolic event, after hemorrhaging had rendered conventional dicumarol therapy impossible.

In all 5 patients, recovery of all dysfunctional organ systems was rapid following implantation of the CardioWest system. All patients could be mobilized on the system and were free of infections throughout the entire support period. Infections in the vicinity of the drive cables, a frequent occurrence with some LVADs, were not observed.

In summary, the implantation of a total artificial heart represents the only life-saving therapeutic option in patients with irreversible cardiogenic shock. In cases where the shock is irreversible, this system is superior to all other assist devices. First experiences in a predominantly young patient cohort produced results that justified the effort involved. In cases of irreversible cardiogenic shock, patients should be given the chance to exhaust the final therapeutic option available to them by ensuring that a center with a mechanical circulatory support program at its disposal is contacted in good time.

## REFERENCES

- Allen BS, Buckberg GD, Fontan FM, et al. 1993. Superiority of controlled surgical reperfusion versus percutaneous transluminal coronary angioplasty in acute coronary occlusion. *J Thorac Cardiovasc Surg* 105:864-84.

- Alonso DR, Scheidt S, Post M, Killip T. 1973. Pathophysiology of cardiogenic shock. Quantification of myocardial necrosis, clinical pathologic and electrocardiographic correlations. *Circulation* 48:588-96.
- Arabia FA, Copeland JG, Pavie A, Smith RG. 1999. Implantation technique for the CardioWest Total Artificial Heart. *Ann Thorac Surg* 68:698-704.
- Bengtson JR, Kaplan AJ, Pieper KS, et al. 1992. Prognosis in cardiogenic shock after acute myocardial infarction in the interventional era. *J Am Coll Cardiol* 20:1482-9.
- Berger PB, Holmes DR Jr, Stebbins AL, Bates EF, Califf RM, Topol EJ. 1997. Impact of an aggressive invasive catheterization and revascularization strategy on mortality in patients with cardiogenic shock in the Global Utilization of Streptokinase and Tissue Plasminogen Activator for Occluded Coronary Arteries (GUSTO-1) trial. An observational study. *Circulation* 96:122-7.
- Beyersdorf F, Sarai K, Wendt T, Eckel L, Schneider M, Kubitzky W. 1990. Prolonged abnormalities of LV regional wall motion after reperfusion of patients with preoperative cardiogenic shock. *Thorac Cardiovasc Surg* 38:165-74.
- Chen JM, DeRose JJ, Slater JP, et al. 1999. Improved survival rates support left ventricular assist device implantation early after myocardial infarction. *J Am Coll Cardiol* 33:1903-8.
- Copeland JG, Pavie A, Duveau D, et al. 1996. Bridge to transplantation with the CardioWest total artificial heart: the international experience 1993-1995. *J Heart Lung Transplant* 15:94-9.
- GISSI-2 The International Study Group. 1990. In-hospital mortality and clinical course of 20,891 patients with suspected acute myocardial infarction randomised between alteplase and streptokinase with or without heparin. *Lancet* 336:71-5.
- Goldberg RS, Gare JM, Alpert JS, et al. 1997. Cardiogenic shock after acute myocardial infarction. Incidence and mortality from community-wide perspective, 1975-1988. *N Engl J Med* 325:1117-22.
- Grines CL, Topol EJ, Califf RM, et al. 1989. Prognostic implications and predictors of enhanced regional wall motion of the noninfarct zone after thrombolysis and angioplasty therapy of acute myocardial infarction. The TAMI Study Groups. *Circulation* 80:245-53.
- Gruppo Italiano per lo Studio della Streptochinasi nell'Infarto Miocardio (GISSI). 1986. Effectiveness of intravenous thrombolytic treatment in acute myocardial infarction. *Lancet* 1:397-402.
- Gunnar RM. 1988. Cardiogenic shock complicating myocardial infarction. *Circulation* 78:1508-10.
- Harnarayan C, Bennett MA, Pentecost BL, Brewer DB. 1970. Quantitative study of infarcted myocardium in cardiogenic shock. *Br Heart J* 32:728-32.
- Hill JD, Farrar DJ, Hershon JJ, et al. 1986. Use of a prosthetic ventricle as a bridge to cardiac transplantation for postinfarction cardiogenic shock. *N Engl J Med* 314:626-8.
- Holmes DR Jr, Bates ER, Kleiman NS, et al. 1995. Contemporary reperfusion therapy for cardiogenic shock: the GUSTO-1 trial experience. *J Am Coll Cardiol* 3:668-74.
- Farrar DJ, Lawson JH, Litwak P, Cederwall G. 1990. Thoratec VAD system as a bridge to heart transplantation. *J Heart Transplant* 9:415-23.
- Kern MJ, Aguirre F, Bach R, Donohue T, Siegel R, Segal J. 1993. Augmentation of coronary blood flow by intra-aortic balloon pumping in patients after coronary angioplasty. *Circulation* 87:500-11.
- Körfer R, El-Banayasy A, Posival H, et al. 1995. Mechanical circulatory support: the Bad Oeynhausen experience. *Ann Thorac Surg* 59:56-63.
- Lee L, Erbel R, Brown TM, Laufer N, Meyer J, O'Neill WW. 1991. Multicenter registry of angioplasty therapy of cardiogenic shock: initial and long term survival. *J Am Coll Cardiol* 17:599-603.
- Moosvi AR, Khaja F, Villanueva L, Gheorghide M, Douthat L, Goldstein S. 1992. Early revascularization improves survival in cardiogenic shock complicating acute myocardial infarction. *J Am Coll Cardiol* 19:907-14.
- Moritz A, Wolner E. 1993. Circulatory support with shock due to acute myocardial infarction. *Ann Thorac Surg* 55:238-44.
- Mueller HS. 1994. Role of intra-aortic counterpulsation in cardiogenic shock and acute myocardial infarction. *Cardiology* 84:168-74.
- Noda H, Takano H, Taenaka Y, et al. 1989. Treatment of acute myocardial infarction with cardiogenic shock using left ventricular assist device. *Int J Artif Organs* 12:175-9.
- Page DL, Caulfield JB, Kastor JA, DeSanctis RW, Sanders CA. 1971. Myocardial changes associated with cardiogenic shock. *N Engl J Med* 285:133-7.
- Park JP, Nguyen DQ, Bank AJ, Ormaza S, Bolman RM 3rd. 2000. Left ventricular assist device bridge therapy for acute myocardial infarction. *Ann Thorac Surg* 69:1146-51.
- Raithel SC, Swartz MT, Braun PR, et al. 1989. Experience with an emergency resuscitation system. *ASAIO Trans* 35:475-7.
- Reedy JE, Swartz MT, Raithel SC, Szukalski EA, Pennington DG. 1990. Mechanical cardiopulmonary support for refractory cardiogenic shock. *Heart Lung* 19:514-23.
- Reichman RT, Jjoy CI, Dembitzky WP, et al. 1990. Improved patient survival after cardiac arrest using a cardiopulmonary support system. *Ann Thorac Surg* 49:101-5.
- Reiß N, Posival H, El-Banayasy A, Schröfel H, Minami K, Körfer R. 1995. Einsatz verschiedener mechanischer Kreislaufunterstützungssysteme in der Therapie des kardiogenen Schocks nach akutem Myokardinfarkt. *Z Kardiologie* 84(suppl 1):20.
- Vogt A, Neuhaus KL. 1999. Therapie des akuten Myokardinfarkts—Primäre PTCA oder Thrombolyse? *Herz* 24:363-8.
- Zeymer U, Reissig M, Neuhaus KL. 1993. Einsatz einer perkutan anschließbaren Herz-Lungen-Maschine unter Reanimationsbedingungen im kardiogenen Schock bei akutem Herzinfarkt. *Dtsch Med Wochenschr* 118:1755-8.
- Zumbro GL, Kitchens WR, Shearer G, Harville G, Bailey L, Galloway RF. 1987. Mechanical assistance for cardiogenic shock following cardiac surgery, myocardial infarction and cardiac transplantation. *Ann Thorac Surg* 44:11-3.