

Repair of Anomalous Origin of Right Pulmonary Artery from Ascending Aorta without Cardiopulmonary Bypass

Fotios A. Mitropoulos,¹ Meletios A. Kanakis,¹ Mark D. Plunkett,² Periklis A. Davlouros,³ Hillel Laks⁴

¹Department of Pediatric Cardiac Surgery and Congenital Heart Surgery, Onassis Cardiac Center, Athens, Greece; ²Kentucky Children's Hospital, UK Albert B. Chandler Hospital, Lexington, Kentucky, USA; ³Department of Cardiology, Patras University Hospital, Rion, Greece; ⁴Ronald Reagan UCLA Medical Center, Los Angeles, California, USA

ABSTRACT

Anomalous origin of a pulmonary artery from the ascending aorta (AORPA) is a rare congenital cardiac malformation that needs prompt surgical repair; otherwise it is associated with poor prognosis. We describe 3 cases of AORPA that successfully underwent complete surgical correction without extracorporeal circulation.

INTRODUCTION

Anomalous origin of a pulmonary artery from the ascending aorta (AORPA) is a rare congenital defect in which 1 of the pulmonary arteries originates from the ascending aorta in the presence of separate aortic and pulmonary valves and without interposition of ductal tissue [Kirklin 2003]. The natural history of this condition leads to severe pulmonary vascular disease [Fong 1989]. The standard repair uses cardiopulmonary bypass and/or cardioplegic arrest. A complete anatomical repair can be performed without the use of cardiopulmonary bypass by detaching the atypical branch pulmonary artery from its source and attaching it to the main pulmonary artery. We report 3 cases performed without the use of extracorporeal circulation.

CASE REPORTS

Case 1

A 4-month-old girl presented with respiratory syncytial virus pneumonia and failure to thrive. Anomalous origin of the right pulmonary artery with patent ductus arteriosus (PDA) was diagnosed by catheterization with the right pulmonary artery (RPA) arising from the ascending aorta. RPA banding and PDA ligation was performed through a median sternotomy. At 20 months complete repair was performed. The RPA was enlarged with a glutaraldehyde-treated autologous pericardial patch at the site of previous band, and a 10-mm

Gore-tex graft was used to reach the main pulmonary artery (MPA). The patient was discharged on the 5th postoperative day. At 36-month follow-up, echocardiogram revealed excellent cardiac function with normal pulmonary artery branch anatomy.

Case 2

A baby girl presented at birth with severe cyanosis. Extracorporeal membrane oxygenation (ECMO) was initiated due to neonatal respiratory distress syndrome. Anomalous origin of the RPA from the innominate artery, PDA, and atrial septal defect (ASD) were diagnosed by echocardiography. This child had multiple seizures and parenchymal brain hemorrhage preoperatively. After consultation with a neurologist, she underwent complete repair at 1.5 months without the use of systemic heparinization and extracorporeal circulation. The RPA was attached primarily to the MPA. Echocardiography on 9th postoperative day showed good ventricular function. The patient was discharged on the 43rd postoperative day after undergoing Nissen fundoplication for severe reflux. Cardiac function and pulmonary artery branch anatomy remained good up to a 32-month follow-up.

Case 3

A 27-day-old boy presented with tachypnea starting at 2 weeks of age. Anomalous origin of the RPA from the ascending aorta was diagnosed by echocardiography. Cardiac magnetic resonance imaging (MRI) also revealed a patent foramen ovale (PFO) and PDA. The patient was operated on at 5 weeks of age with direct implantation of the RPA to the MPA without complication. He was extubated on the 6th postoperative day and discharged on the 12th postoperative day. Clinical and echocardiographic follow-up at 58 months revealed excellent cardiac function without any branch pulmonary artery stenosis.

DISCUSSION

AORPA is 4 to 8 times more common than anomalous origin of the left pulmonary artery (AOLPA) from aorta [Dodo 1995]. Both conditions are often associated with other congenital anomalies including PDA, PFO, ventricular septal defect (VSD), tetralogy of Fallot, interrupted aortic arch, aortopulmonary window, and isthmus hypoplasia [Dodo 1995].

Received March 5, 2010; accepted May 19, 2010.

Correspondence: Fotios A. Mitropoulos MD, PhD, Monastiriou 8, Thracomacedones, Athens, Greece 13676; +30 210-2433431, +30 6947430145; fax: +30 210-2433431 (e-mail: fotiosmitropoulos@yahoo.com).

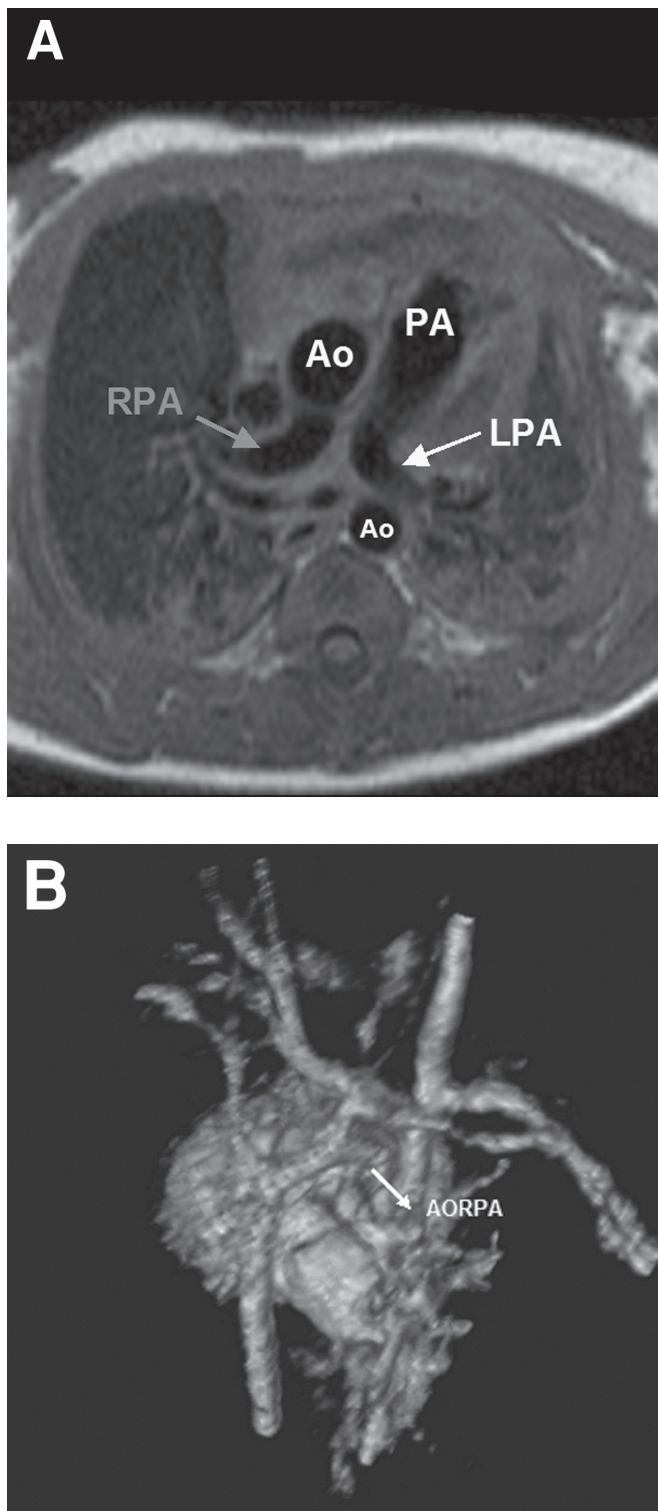


Figure 1. A, cardiac magnetic resonance imaging (MRI) of a 5-week-old boy with anomalous origin of right pulmonary artery (AORPA) prior to complete repair without bypass. B, 3D cardiac MRI reconstruction (right posterior view) of the same patient depicts the AORPA. Ao indicates aorta; PA, pulmonary artery; LPA, left pulmonary artery; RPA, right pulmonary artery.




Figure 2. Diagram of Surgical Technique. AORPA indicates anomalous origin of right pulmonary artery from ascending aorta; LPA, left pulmonary artery; MPA, main pulmonary artery; PDA, patent ductus arteriosus; RPA, right pulmonary artery.

AORPA or AOLPA from the aorta is the result of an embryologically distinct process. Malformations of the 5th and 6th aortic arches are implicated [Penkoske 1983]. 22q11 microdeletion has been found in some cases with AOLPA and tetralogy of Fallot [Saliba 1999].

Clinical presentation in early infancy occurs with respiratory distress, heart failure, and possible cyanosis. There are no typical findings in the physical examination. Diagnosis is usually established by 2-dimensional echocardiography, but imaging of the pulmonary artery branches may be difficult and cardiac catheterization may be needed when clinical suspicion exists. Cardiac MRI (Figure 1A) and magnetic resonance angiography with 3D reconstruction (Figure 1B) have been recently used for confirmation of suspected cases and better preoperative planning.

The pathophysiology resulting from this condition affects both lungs and leads to pulmonary hypertension and severe pulmonary vascular disease [Fong 1989]. The existence of other aforementioned lesions aggravates further the left to right shunt.

AORPA is a lethal condition. About 70% of surgically untreated patients are dead by 6 months of age, and 80% by 1 year [Kirklin 2003]. Early repair is the treatment of choice in order to avoid the development of pulmonary hypertension and right ventricular (RV) failure. Various techniques have been described in the surgical literature. The most popular technique is with the use of cardiopulmonary bypass and involves the attachment of the RPA to the MPA via mobilization posteriorly to the ascending aorta [Penkoske 1983]. Several alternative techniques have been described in cases where direct implantation is not feasible [van Son 1996; Prifti 2002]. In our experience, we have performed direct implantation in 2 patients, and 1 patient required a Gore-tex interposition graft. In the off-pump technique, after a median sternotomy, we proceed to heparinization (1 mg/kg) with the pump standby. Extensive branch pulmonary artery mobilization is required including the portion behind the aorta to avoid tension of the anastomosis. If the length is not sufficient, a Gore-tex interposition graft may be used (Figure 2). The disadvantage with the use of prosthetic material is the need for reoperation in the future, due to patient-graft mismatch. C-clamps are used on the ascending aorta at the base

of the pulmonary artery and another clamp is placed on the RPA after its bifurcation. Although this makes the surgical technique more difficult, it has the significant advantage of avoiding the use of cardiopulmonary bypass and the occasional ischemic injury from myocardial arrest.

Postoperative follow-up requires routine transthoracic echocardiography, and, when indicated, diagnostic or therapeutic catheterization can be performed. Nathan et al [Nathan 2007] in the largest published study with 16 patients who underwent surgical repair describes excellent early and late outcomes, with a hospital mortality of 6%. In the same study, during the follow-up period, 19% of patients needed catheter intervention, and 6% required reoperation [Nathan 2007]. In our experience, no need to convert the off-pump technique to on-pump was presented and we had no hospital mortality. In a follow-up period up to 58 months, all patients are in clinically excellent condition with no need for further intervention.

Repair of AORPA without bypass is a feasible and effective technique for complete correction of this congenital heart defect.

REFERENCES

- Dodo H, Alejos JC, Perloff JK, Laks H, Drinkwater DC, Williams RG. 1995. Anomalous origin of the left main pulmonary artery from the ascending aorta associated with DiGeorge syndrome. *Am J Cardiol* 75:1294-5.
- Fong LV, Anderson RH, Siewers RD, Trento A, Park SC. 1989. Anomalous origin of one pulmonary artery from the ascending aorta: a review of echocardiographic, catheter, and morphological features. *Br Heart J* 62:389-95.
- Kirklin JW, Barratt-Boyes BG. 2003. Origin of right or left pulmonary artery from ascending aorta. In: Kirklin JW, Barratt-Boyes BG, eds. *Cardiac Surgery*. 3rd ed. Philadelphia, Pa: Churchill Livingstone; 1231-40.
- Nathan M, Rimmer D, Piercey G, et al. 2007. Early repair of hemitruncus: excellent early and late outcomes. *J Thorac Cardiovasc Surg* 133:1329-35.
- Penkoske PA, Castañeda AR, Fyler DC, Van Praagh R. 1983. Origin of pulmonary artery branch from ascending aorta: primary surgical repair in infancy. *J Thorac Cardiovasc Surg* 85:537-45.
- Prifti E, Frati G, Crucean A, Vanini V. 2002. A modified technique for repair of the anomalous origin of the right pulmonary artery from the ascending aorta. *Eur J Cardiothorac Surg* 22:148-50.
- Saliba Z, Le Bidois J, Sidi D, Kachaner J, Bonnet D. 1999. Prenatal detection of a tetralogy of Fallot with origin of the left pulmonary artery from the ascending aorta in a familial 22q11 microdeletion. *Prenat Diagn* 19:260-2.
- van Son JA, Hanley FL. 1996. Use of autogenous aortic and main pulmonary artery flaps for repair of anomalous origin of the right pulmonary artery from the ascending aorta. *J Thorac Cardiovasc Surg* 111:675-6.