

## Ligation of a Fistula between the Left Main Coronary Artery and Both the Pulmonary Artery and the Right Ventricle

İ. Halil Algin,<sup>1</sup> Aytekin Yesilay,<sup>2</sup> N. Murat Akcar<sup>1</sup>

Clinics of <sup>1</sup>Cardiac Surgery and <sup>2</sup>Anesthesiology, OSM Ortadogu Hospital, SanlıUrfa, Turkey

### ABSTRACT

The frequency of coronary artery fistula among all coronary angiography patients is 0.1% to 0.2%; however, involvement of both the pulmonary artery and the right ventricle is a rare clinical entity. A 53-year-old man patient was admitted to our clinic with rarely occurring chest pain, palpitations, and dyspnea. A coronary angiogram showed a fistula between the left main coronary artery and both the pulmonary artery and the right ventricle. We performed a ligation of this fistula without cardiopulmonary bypass. Aorta and right ventricle sutures were made, and the proximal and distal portions of the fistula were obliterated with 5-0 Prolene sutures and previously prepared Teflon felt. The patient recovered and was discharged without any complications. The surgical indications for coronary artery fistulas are symptomatic disease, an aneurysmic coronary artery, signs of heart failure, and ischemia. The surgical options in such cases—depending on whether the fistula is complicated or not—are simple ligation or transarterial ligation under cardiopulmonary bypass.

### INTRODUCTION

The frequency of coronary artery fistula among all coronary angiography patients is 0.1% to 0.2%. Among these patients, the frequency of fistulization of the coronary artery with the pulmonary artery and the right ventricle is 10% to 25% [Athanasias 2002; Osawa 2009]. Patients may complain of chest pain, syncope, or signs of heart failure, but most patients are asymptomatic. The main factors for the appearance of symptoms are the radii of the coronary artery and the pulmonary artery, the pulmonary artery pressure, and other accompanying comorbid diseases (diabetes mellitus, hypertension, coronary artery disease). Our case report describes a patient who sometimes complained of chest pain.

Received June 9, 2011; accepted August 12, 2011.

Correspondence: İ. Halil Algin, Clinic of Cardiac Surgery, OSM Ortadogu Hospital, R. T. Erdogan Cadd. 63000, SanlıUrfa, Turkey; 04143144446; fax: 04143149836 (e-mail: [algin.ibrahim@gmail.com](mailto:algin.ibrahim@gmail.com)).

### CASE REPORT

We describe a 53-year-old man who was admitted to our clinic with rarely occurring chest pain, palpitations, and dyspnea. The physical examination revealed a soft 1-2/6 systolic

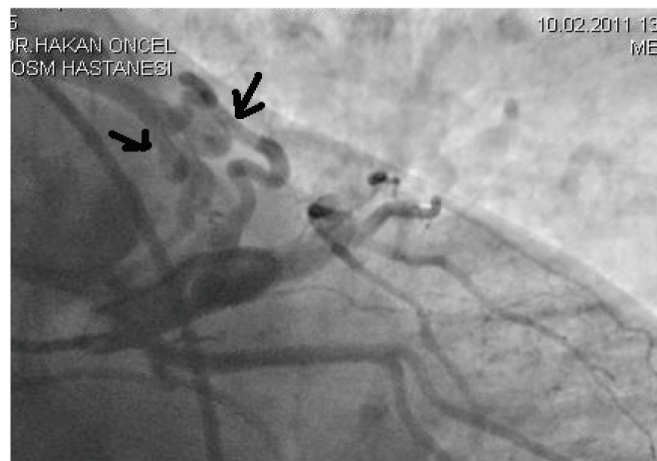
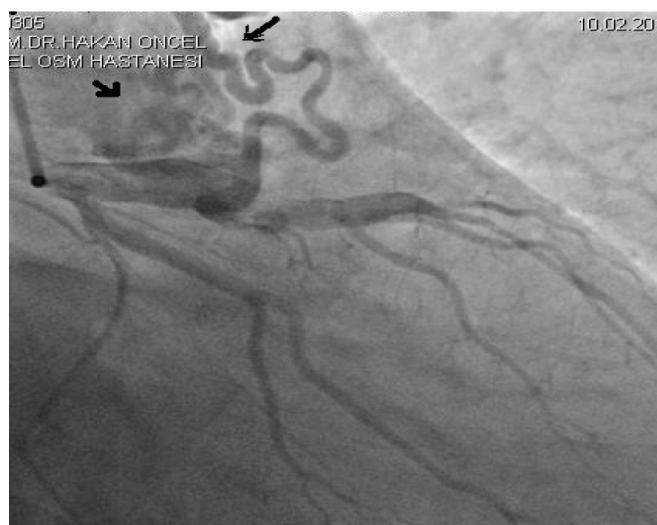


Figure 1. Angiographic appearance of the fistula (arrows in top and bottom images).

murmur in the left second intercostal space and minimal ST-T changes in the anterolateral leads of the electrocardiogram. Coronary angiography showed a fistula between the left main coronary artery and both the pulmonary artery and the right ventricle. In addition, an aneurysmic formation was apparent in the left main coronary artery (Figure 1). Before surgery, anesthesia was induced with fentanyl (15 µg/kg), midazolam (1.5 mg/kg), and rocuronium (0.6 mg/kg) and was maintained with 3% sevoflurane and 40% oxygen/60% air under 2 L/min of fresh gas flow. After a median sternotomy, the pericardium was opened and suspended. A soft thrill was palpated over the fistula (Figure 2). We decided to perform a ligation procedure without using cardiopulmonary bypass. After the aorta and right ventricle sutures were made, the proximal and distal portions of the fistula were obliterated by 5-0 Prolene sutures with previously prepared Teflon felt. No thrill was palpated after the ligation. The layers were anatomically closed with the end of bleeding control. In the postoperative period, the patient was followed to guard against arrhythmias. Finally, the patient was discharged with a β-blocker prescription (50 mg oral metoprolol once daily) without any complications.

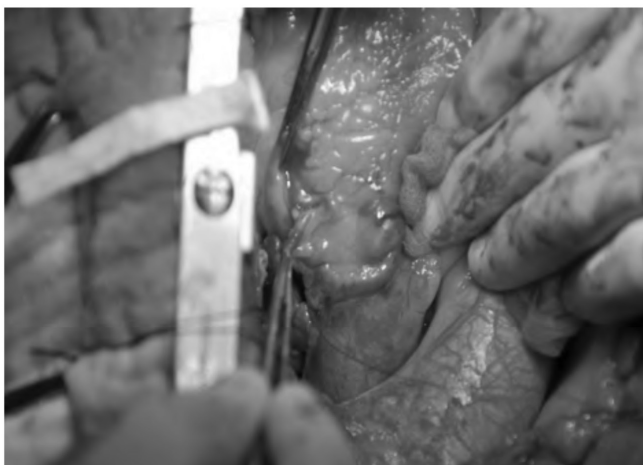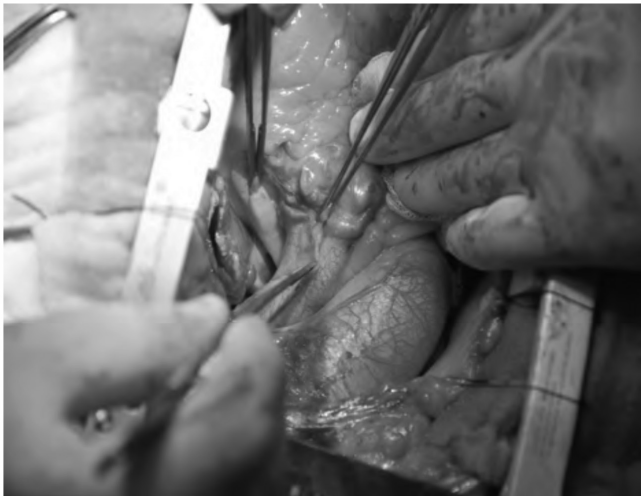


Figure 2. Perioperative appearance of the fistula (top, bottom).

## DISCUSSION

Coronary artery fistula is very rare among coronary artery abnormalities. Levin et al reported a frequency of 5% among 363 patients [Levin 1978]. Although some patients may show such symptoms as angina pectoris, dyspnea, and signs of heart failure, others may remain asymptomatic. Sometimes coronary artery fistula is detected incidentally in coronary angiograms performed for other indications. Okwuosa et al detected coronary artery fistulas during echocardiographic examinations and completed the diagnoses with cardiac magnetic resonance imaging and coronary angiography [Okwuosa 2006]. In our case, the patient was admitted with palpitations, dyspnea, and angina pectoris. The physical examination revealed a soft murmur in the left second intercostal space, and the diagnosis was confirmed with coronary angiography. The surgical indications for coronary artery fistulas are symptomatic disease, an aneurysmic coronary artery, signs of heart failure, and ischemia. Konno and Endo [1973] added social reasons to these indications. The surgical options—depending on whether the fistula is complicated or not—are simple ligation or transarterial ligation under cardiopulmonary bypass [Liberthson 1979]. Huang et al [2006] declared that they routinely explore the pulmonary artery under cardiopulmonary bypass.

## CONCLUSION

A fistula between the left main coronary artery and both the pulmonary artery and right ventricle was corrected by successfully performing a simple off-pump surgical ligation. The patient was discharged with full recovery without any complications.

## REFERENCES

- Athanasias DA, Van Ommen V, Bar F. 2002. Coronary artery-pulmonary artery fistula originating from the left anterior descending artery: a case report and literature review. *Hellenic J Cardiol* 43:78-81.
- Huang YK, Lei MH, Lu MS, Tseng CN, Chang JP, Chu JJ. 2006. Bilateral coronary-to-pulmonary artery fistulas. *Ann Thorac Surg* 82:1886-8.
- Konno S, Endo M. 1973. Congenital coronary artery diseases [in Japanese]. *Kokyu to Junkan* 21:379-409.
- Levin DC, Fellows KE, Abrams HL. 1978. Hemodynamically significant primary anomalies of the coronary arteries. Angiographic aspects. *Circulation* 58:25-34.
- Liberthson RR, Sagar K, Berkoben JP, Weintraub RM, Levine FH. 1979. Congenital coronary arteriovenous fistula. Report of 13 patients, review of the literature and delineation of management. *Circulation* 59:849-54.
- Okwuosa TM, Gundeck EL, Ward RP. 2006. Coronary to pulmonary artery fistula—diagnosis by transesophageal echocardiography. *Echocardiography* 23:62-4.
- Osawa H, Sakurada T, Sasaki J, Araki E. 2009. Successful surgical repair of a bilateral coronary-to-pulmonary artery fistula. *Ann Thorac Cardiovasc Surg* 15:50-2.