

## Successful Robotic-Assisted Division of Symptomatic Vascular Ring



Budhaditya Chakraborty, MCh,<sup>1</sup> Harold M. Burkhart, MD,<sup>1</sup> Carole A. Warnes, MD,<sup>2</sup>  
Rakesh Suri, MD, DPhil<sup>1</sup>

Divisions of <sup>1</sup>Cardiovascular Surgery and <sup>2</sup>Cardiovascular Diseases, Mayo Clinic and Foundation,  
Rochester, Minnesota, USA

### CASE REPORT

A 61-year-old woman presented with the primary complaints of chest heaviness and dysphagia over the past 10 years. Extensive work-up included a computerized tomographic angiography that revealed a right aortic arch with an aberrant left subclavian artery with a vascular ring completed by the fibrotic ligamentum arteriosum connecting the proximal aberrant left subclavian artery to the left pulmonary artery (Figure).

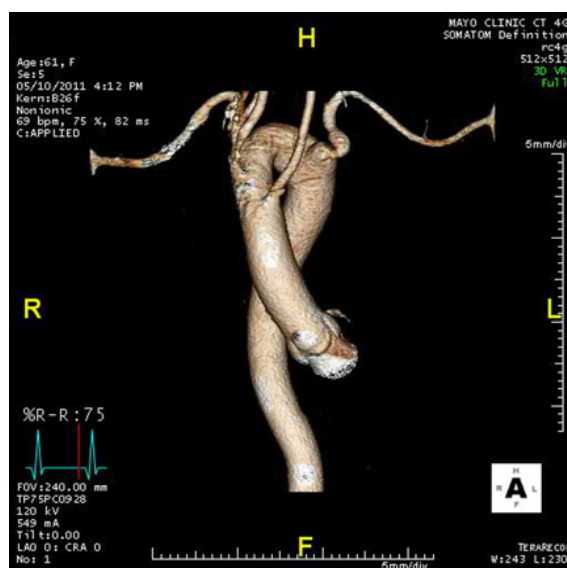
The patient was scheduled for robotic-assisted division of the vascular ring and was positioned in an exaggerated right lateral decubitus with single right lung ventilation. Three robotic instrument ports were placed through 1-cm incisions: the camera port was introduced in the 5th intercostal space in the mid-axillary line, the right arm port was introduced through the 3rd intercostal space at the anterior axillary line, and the left arm port was positioned through the 6th intercostal space at the posterior axillary line. The ligamentum arteriosum was dissected and successfully divided (Video).

The patient was extubated in the operating room and discharged after 3 days. At last follow-up, her symptoms had resolved.

### REVIEW OF LITERATURE

The evolution of robotic assist devices has furthered the utilization of endoscopic surgery on several fronts. The surgical division of vascular rings is one of them. There is limited experience with use of this modality for vascular rings. Del Nido et al have published their experience with about 6 patients with a mean age of  $8.3 \pm 4.7$  years [Mihaljevic 2003; Suematsu 2005].

We have extended this option for adult patients as well and to date have operated on 3 patients aged 54, 62, and 31 years. The pathologies have been varied, including right aortic arch with ligamentum arteriosum with mirror image branching pattern, right aortic arch with aberrant left subclavian and ligamentum



Computerized tomographic angiographic image of the right aortic arch with the aberrant subclavian artery as the fourth branch. Note the calcification and fibrosis at the site of attachment of the ligamentum on the left subclavian artery.

arteriosum, and double aortic arch with dominant right arch.

The computer enhanced 3-dimensional visual system and advanced mechanics of the motor arm and wrist motion facilitate easy exposure and dissection. We did not encounter any issues with bleeding, and all patients had uneventful recoveries. There was significantly less postoperative pain and better cosmesis, and the average hospital stay was only 3 days. We do, however, need meticulous patient selection and more experience before the option can be offered across the board for a wider spectrum of the patient population.

### REFERENCES

- Mihaljevic T, Cannon JW, del Nido PJ. 2003. Robotically assisted division of a vascular ring in children. *J Thorac Cardiovasc Surg* 125:1163-4.
- Suematsu Y, Mora BN, Mihaljevic T, del Nido PJ. 2005. Totally endoscopic robotic-assisted repair of patent ductus arteriosus and vascular ring in children. *Ann Thorac Surg* 80:2309-13.

Received March 5, 2012; received in revised form August 15, 2012; accepted October 12, 2012.

Correspondence: Harold M. Burkhart, MD, Division of Cardiovascular Surgery, Mayo Clinic College of Medicine, 200 First Street SW, Rochester, MN 55905; 507-255-7065; fax: 507-255-7378 (e-mail: burkhart.harold@mayo.edu).