

Aortic Perforation Caused by Friction of a Chest Tube after Coronary Artery Bypass Surgery

Chih-Chien Yen,¹ Ya-Sung Yang,² Kuang-Yi Liu¹

¹Division of Cardiovascular Surgery, Department of Surgery, Armed Forces Tao-Yuan General Hospital, Taoyuan; ²Department of Internal Medicine, Tri-Service General Hospital, National Defense Medical Center, Taipei, Taiwan



Dr. Yen

ABSTRACT

Aortic perforation caused by the friction of a chest tube is a rare but life-threatening complication of coronary artery bypass grafting (CABG). We report a case involving CABG for triple-vessel disease and unstable angina. Reexploration was necessary 24 hours after the operation because of the sudden onset of pronounced bleeding. Perforation of the ascending aorta caused by friction of the chest tube was found. Bleeding was controlled by means of a purse string suture with 4-0 Prolene. Use of pericardium membrane between the heart and the chest tube and the choice of smaller and more flexible Silastic chest tubes in high-risk patients can probably reduce the incidence of this complication.

INTRODUCTION

Aortic perforation caused by the friction of a chest tube is a rare but life-threatening complication of coronary artery bypass grafting (CABG). We report such a case, which was cured by reexploration, repair of the aorta, and placing the pericardium membrane between the heart and the chest tube to prevent further friction.

CASE REPORT

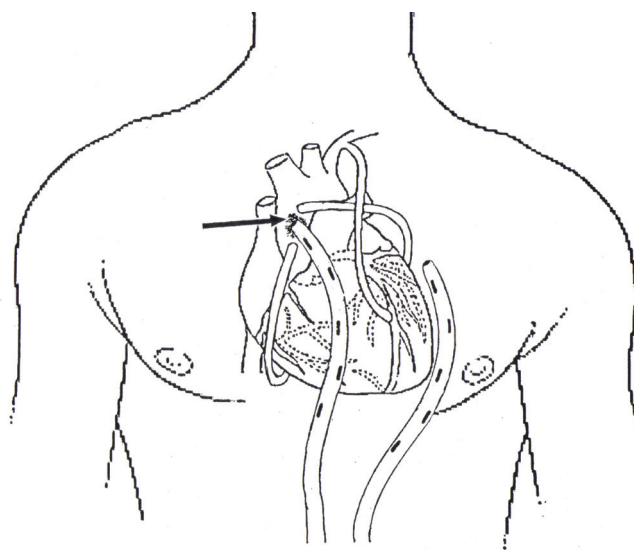
An 82-year-old man was referred for coronary revascularization because of worsening angina. He was categorized in New York Heart Association functional class III. A left ventriculography evaluation showed an ejection fraction of 56% with lateral, inferior, and posterior wall hypokinesia. Coronary angiography revealed triple-vessel disease: 80% stenosis of the proximal portion of the left anterior descending artery, 80% stenosis of the middle portion of the circumflex artery, and 70% stenosis of the distal portion of the right coronary artery. The patient underwent triple CABG with

a standard cardiopulmonary bypass and cardioplegic technique. Grafting of the left anterior descending artery was by means of a left internal mammary artery graft. Grafting of the circumflex and right coronary arteries used saphenous vein grafts.

Postoperatively, we placed 2 large-bore plastic chest tubes for draining blood from the mediastinum. In the first 24 hours, the drainage was not excessive (275 mL), but on the second day massive bleeding (410 mL in 1 hour) from the chest tubes occurred. The patient underwent operative reexploration, which revealed a perforation of the ascending aorta caused by rubbing of the chest tube (Figure). Bleeding was controlled by means of a purse string suture with 4-0 Prolene.

DISCUSSION

More than 640,000 patients undergo open heart surgery in the United States every year. The most frequently performed and successful procedure is CABG. Several complications can occur after CABG. The most common is bleeding,



Schema of the site of aortic perforation (arrow) caused by the friction of a chest tube.

Received October 19, 2009; accepted November 10, 2009.

Correspondence: Dr. Chih-Chien Yen, Division of Cardiovascular Surgery, Department of Surgery, Armed Forces Tao-Yuan General Hospital, No. 168, Jhongsing Rd, Longtan, Township, Taoyuan County 325, Taiwan; +886-3-4807795; fax: +886-3-4801621 (e-mail: chibchienyen@yahoo.com.tw).

which necessitates blood transfusions in approximately 30% of patients. Of these patients, 2% to 6% require reexploration to stop the bleeding [Unsworth-White 1995].

Sites of postoperative bleeding typically are anastomosis leakage of the bypass graft, poststernotomy bone marrow oozing, the chest wall where the internal mammary arteries are harvested, the cannulation site, and the chest tube incision site. As part of the CABG procedure, one or more large-bore plastic chest tubes are typically placed for drainage of blood from the mediastinum and pleura. These are usually removed uneventfully within 1 to 3 days. Infrequently, however, massive bleeding occurs (defined as blood loss of >200 mL/h for the first 4 hours or >1000 mL during the initial 24 hours after surgery). The necessary reexplorative surgery increases the hospital stay and the in-hospital mortality rate [Unsworth-White 1995; Moulton 1996]. An older age, a smaller body mass index, a longer cardiopulmonary bypass time, non-elective surgery, an increased number of distal anastomoses, and use of an internal mammary artery are risk factors for post-CABG bleeding [Karthik 2004]. Bjessmo et al [2007] showed that the diameter of the chest tube has no effect on the drainage of postoperative bleeding. Lancey et al [2001] suggested that smaller and more flexible Silastic chest tubes had the same drainage ability as traditional chest tubes. We believe that the use of the smaller and softer Silastic chest tubes may allow drainage as efficiently as larger-diameter tubes and produce less friction between the great vessels and chest tubes. In addition, placement of the pericardium membrane between the heart and the chest tube in patients at high

risk for post-CABG bleeding is suggested to prevent friction caused by the chest tube. Confirmation of the utility of these suggestions, however, requires prospective studies with large sample sizes.

In conclusion, aortic perforation caused by friction of a chest tube is a rare but life-threatening complication after CABG. Use of pericardium membrane between the heart and the chest tube and the choice of smaller and more flexible Silastic chest tubes in high-risk patients can probably reduce the incidence of this complication.

REFERENCES

- Bjessmo S, Hylander S, Vedin J, Mohlkert D, Ivert T. 2007. Comparison of three different chest drainages after coronary artery bypass surgery—a randomised trial in 150 patients. *Eur J Cardiothorac Surg* 31:372-5.
- Karthik S, Grayson AD, McCarron EE, Pullan DM, Desmond MJ. 2004. Reexploration for bleeding after coronary artery bypass surgery: risk factors, outcomes, and the effect of time delay. *Ann Thorac Surg* 78:527-34; discussion 534.
- Lancey RA, Gaca C, Vander Salm TJ. 2001. The use of smaller, more flexible chest drains following open heart surgery: an initial evaluation. *Chest* 119:19-24.
- Moulton MJ, Creswell LL, Mackey ME, Rosenbloom M. 1996. Reexploration for bleeding is a risk factor for adverse outcomes after cardiac operations. *J Thorac Cardiovasc Surg* 111:1037-46.
- Unsworth-White MJ, Herriot A, Valencia O, et al. 1995. Resternotomy for bleeding after cardiac operation: a marker for increased morbidity and mortality. *Ann Thorac Surg* 59:664-7.