

Complete Preservation of the Mitral Valve Apparatus during Mitral Valve Replacement for Rheumatic Mitral Regurgitation in Patients with an Enlarged Left Ventricular Chamber

Lin Chen, Baicheng Chen, Jia Hao, Xuefeng Wang, Ruiyan Ma, Wei Cheng, Chuan Qin, Yingbin Xiao

Department of Cardiovascular Surgery, Xinqiao Hospital, Third Military Medical University, Chongqing, P. R. China



Dr. Chen

ABSTRACT

Background and Aims: The merits of retaining the subvalvular apparatus during mitral valve replacement (MVR) for chronic mitral regurgitation have been demonstrated in clinical investigations. This study was to investigate the feasibility of total preservation of the leaflet and subvalvular apparatus at the native anatomic position during MVR in a rheumatic population with enlarged left ventricular chamber.

Material and Methods: The techniques of valvular apparatus preservation used during MVR with or without aortic valve replacement were investigated in 128 patients with an enlarged left ventricular chamber suffering from rheumatic mitral regurgitation between October 2003 and December 2007. Seventy patients had the anterior leaflet and subvalvular apparatus excised but the posterior leaflet and subvalvular apparatus preserved during the mitral valve replacement (P-MVR group), and 58 patients had the anterior and posterior mitral leaflets and the subvalvular apparatus completely preserved at the native anatomical position during the mitral valve replacement (C-MVR group). Echocardiography was performed preoperatively, at discharge, and after 3 months, 1 year, and 3 years to determine the left ventricular dimensions and function.

Results: There were 2 cases (3.4%) of early death in the C-MVR group, and there were 4 cases (5.7%) of early death in the P-MVR group. There were 3 cases of late death 1 year after surgery, of which 1 case in the C-MVR group was caused by congestive heart failure and the other 2 cases in the P-MVR group were due to sudden death. Both groups

exhibited significant improvement ($P < .05$) in left ventricular function instantly and late postoperatively. The reduction of the left ventricular end-diastolic diameter was more significant in the C-MVR group as compared to the P-MVR group ($P < .05$). A statistically significant increase in fractional shortening (FS) occurred in the C-MVR group compared to the P-MVR group.

Conclusion: This study shows that complete mitral leaflet preservation at the native anatomical position during MVR is feasible in rheumatic patients with an enlarged left ventricular chamber and confers significant short-term and long-term advantages by preserving left ventricular function and geometry. Therefore, it is a safe, simple, and effective surgical technique and should be individualized during clinical use.

INTRODUCTION

The merits of retaining the subvalvular apparatus during mitral valve replacement (MVR) for chronic mitral regurgitation have been demonstrated in numerous retrospective clinical investigations [David 1983; Sasaki 2003]. The effects of the preservation of the total mitral valve with the subvalvular apparatus during MVR on chronic mitral regurgitation in patients with an enlarged left ventricular chamber (ELVC), however, have been rarely reported. In this study, we describe our experience of the preservation of the mitral leaflet with the subvalvular apparatus at the native anatomical position during MVR in patients with an ELVC suffering from rheumatic mitral regurgitation.

MATERIALS AND METHODS

Patient Characteristics

Between October 2003 and December 2007, 4100 patients underwent MVR or double valve replacement (DVR) at our hospital. Among the 4100 patients, 128 patients with an ELVC undergoing MVR for severe rheumatic mitral regurgitation were selected for this prospective study. For these 128 patients, dyspnea on exertion was the predominant symptom; 126 patients (98.4%) were New York Heart Association (NYHA) functional class III or IV. Congestive cardiac failure was present in 107 patients (83.6%). Atrial fibrillation was present in 113 patients (88.3%). The left ventricular end

This paper has been presented at the 20th Annual Congress of Thoracic and Cardiovascular Surgery of Asia, and read on October 30, 2010, at Hall 2B(2F), Beijing International Convention Center, No. 8 Beichen Dong Road, Chaoyang District, Beijing, P. R. China 100101.

Received November 26, 2012; accepted May 20, 2013.

Correspondence: Dr. Lin Chen, Dr. Yingbin Xiao, Department of Cardiovascular Surgery, Xinqiao Hospital, Third Military Medical University, Deputy director office of Department of Cardiovascular Surgery, 7F, Second in-Patient Building, 183 Xinqiao St, Shapingba District, Chongqing 400037, P. R. China; 00-86-23-68774607; fax: 00-86-23-6874107 (e-mail: chenlin_xq@yahoo.com.cn, yingbinxiaovip@sina.cn).

Table 1. Demographic Details of the Study Groups*

Variable	C-MVR Group (n = 58)	P-MVR Group (n = 70)	P
Female population, n (%)	35 (60.3)	47 (67.1)	.293
Age, y (mean \pm SD)	40.8 \pm 15.3	41.7 \pm 16.1	.431
BSA, m ² (mean \pm SD)	1.44 \pm 0.11	1.46 \pm 0.15	.113
Body weight, kg (mean \pm SD)	54.0 \pm 7.3	56.0 \pm 9.9	.039
Course of disease, y (mean \pm SD)	8.41 \pm 2.20	9.01 \pm 3.67	.071
Combined lesion, n (%)			
TR	17 (29.3)	19 (27.1)	.578
AR	15 (25.9)	21 (30.0)	.334
Thrombus of left atrium	3 (5.1)	6 (8.6)	.745
GLA	17 (29.3)	18 (25.7)	.183
Atrial fibrillation	52 (89.7)	61 (87.1)	.317

*SD indicates standard deviation; BSA, body surface area, TR, tricuspid regurgitation; AR, aortic regurgitation; GLA, giant left atrium.

diastolic diameter (LVEDD) was 78.93 ± 9.47 mm (ranging from 72.5 to 113.0 mm). The demographic and clinical profiles of the 128 patients are shown in Table 1. Informed consent was obtained from all the patients. The protocol was approved by the Review Board of Xinqiao Hospital.

Surgical Techniques

A median sternotomy was made. Moderate hypothermic (26°C to 30°C) cardiopulmonary bypass (CPB) was established by ascending aortic and bicaval cannulation. An intermittent antegrade cold blood cardioplegia and topical hypothermia were used for myocardial preservation. During the DVR procedure, an intermittent antegrade/retrograde cold blood cardioplegia was given to protect the heart. A

left atrial vent was placed through the right superior pulmonary vein. In 92 patients, MVR was approached through a left atrial incision behind the interatrial groove. A transeptal approach was employed in 36 patients with associated tricuspid regurgitation.

The patients were divided into 2 groups, the C-MVR group (n = 58) and the P-MVR group (n = 70). In the C-MVR group, preservation of the mitral leaflet with the chordopapillary apparatus was performed after intraoperative visual assessment of the mitral valve. The anterior leaflet was imbricated into the mitral anterior annulus with their chordal attachment from the base to the free edge by plicating the anterior leaflet body using everting 2-0 Ethibond mattress sutures with a pledget, which would be used for the valve replacement. Sutures were placed through the mitral annulus first and then passed from the bottom to the tip of the anterior leaflet. In the next step, the same sutures were passed through the conjunction site between the leaflet and chordae to maintain appropriate tension by stretching the chordae. If the chordae were loose, the sutures would be sewn through the middle of the chordae, or to the conjunction between the chordae and the papillary, to maintain the appropriate tension of the chordae. To accommodate the larger size prosthesis, the anterior and posterior mitral commissures could be incised carefully, if necessary. Finally, the posterior annulus was sutured with interrupted everting 2-0 Ethibond mattress sutures with a pledget. If the posterior leaflet was excessively redundant or if the chordae tendinae were elongated, the leaflet was also imbricated into the mitral annulus. Subsequently, the sutures were passed through the appropriate point of the prosthetic valve (Figures 1 and 2). While securing the prosthetic valve on the annulus, the anterior valve sutures were tied first to assure that the anterior leaflet had been imbricated between the mechanical prosthesis and the annulus, and that the chordae maintained an appropriate chordal tension. The leaflets were reefed within the valve-sutures and compressed between the sewing ring and the native annulus when implanting the prosthesis.

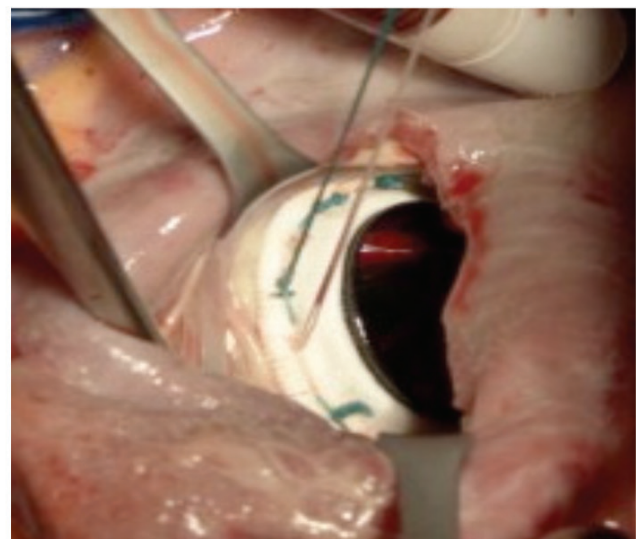
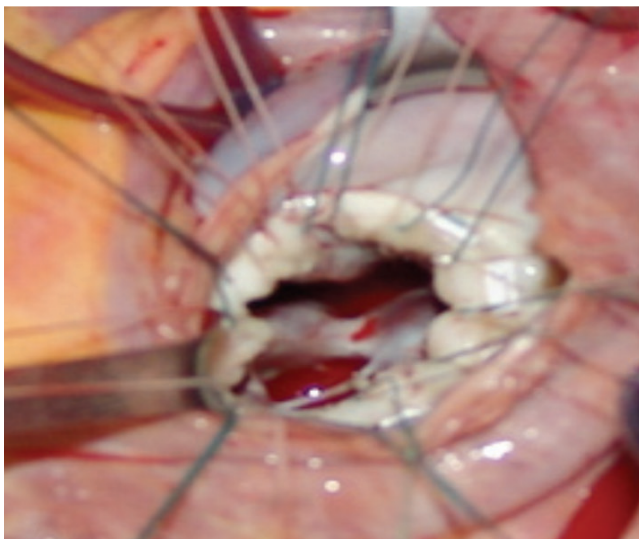


Figure 1. Sutures were placed through the mitral annulus first and then passed from the bottom to the tip of the anterior leaflet. The sutures were then tied and secured. The leaflets were reefed within the valve-sutures and compressed between the sewing ring and the native annulus when implanting the prosthesis.

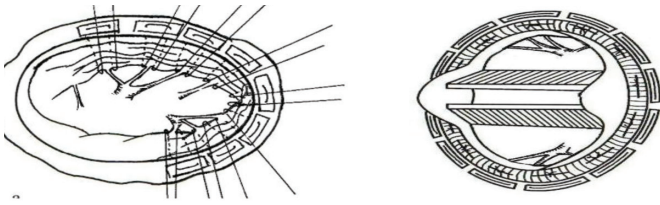


Figure 2. Sutures were placed through the mitral annulus first and then passed from the bottom to the tip of the anterior leaflet. In the next step, the same sutures were passed through the conjunction site between the leaflet and chordae to maintain appropriate tension by stretching the chordae.

the sewing ring and the native annulus when implanting the prosthesis. Meanwhile, all the chordae including the anterior paramedial chordae, or the anterior and posterior paramedial chordae tendinae, or the paracommissural chordae tendinae were preserved along their native direction. The chordal tension on the ventricle was thus maintained and the chordae were pulled away from the valve effluent. The St. Jude mechanical prosthesis (St. Jude Medical Inc., St. Paul, MN, USA) or the On-X mechanical prosthesis (On-X Life Technologies, Inc., Austin, TX, USA) with a lower profile were used in the C-MVR group. Disc movement was investigated after the implantation of the mechanical prosthetic valve. The concomitant procedures of the patients included tricuspid annuloplasty in 17 patients (29.3%), aortic valve replacement in 15 patients (20.7%), clearance of left atrial thrombus in 3 patients (5.1%), and plating of enlarged left atrium in 17 patients (29.3%).

In the P-MVR group, the anterior mitral leaflet and its attached chordae tendinae were completely excised, but the posterior mitral leaflet with chordopapillary apparatus was retained using the technique described in a previous study [David 1983]. The St. Jude (St. Jude Medical, Inc.), ATS (ATS Medical, Inc., Minneapolis, MN, USA), and CarboMedics (Sorin-CarboMedics, Inc., Austin, TX, USA) mechanical prostheses were used in the P-MVR group. The concomitant procedures included tricuspid annuloplasty in 19 patients (27.1%), aortic valve replacement in 21 patients (30.0%), clearance of left atrial thrombus in 6 patients (8.6%), and plating of enlarged left atrium in 18 patients (25.7%).

All the patients were weaned from the CBP without any difficulty. For economic reasons, intraoperative transesophageal echocardiogram was not performed. To assess the function of the newly placed mitral valve, the left atrium pressure was tested before weaning the patient from the CBP. The lead of the epicardium of a temporary pacemaker was placed on the right ventricle prophylactically for all patients. No surgical procedure was performed due to atrial fibrillation.

Postoperative Studies

A 3-year follow-up was mandatory for this study. The investigations included clinical examinations and echocardiography. The functional classification during follow-up was noted. The results were reported according to the prescribed criteria [Akins 2008].

Transthoracic 2-dimensional (2D) Doppler echocardiography with color flow were performed using a Sonos 5500 (Hewlett-Packard, Andover, MA, USA) with 2.7 or 3.5 MHz transducer. Prosthetic valve function was assessed by means of a 2D apical 4-chamber view and an M-mode parasternal long-axis view. The LVEDD, left ventricular ejection fraction (EF), and left ventricular fractional shortening (FS) were measured [Chowdhury 2005]. The mean values for each measurement were derived from 3 consecutive heartbeats in patients in sinus rhythm and from 5 heartbeats in patients in atrial fibrillation. The preoperative studies were performed within 7 days before surgery. Postoperatively, all survivors were followed echocardiographically at the time of discharge from hospital, and at 3 months, 1 year, and 3 years of follow-up.

Statistical Analysis

Data are shown as mean and standard deviation (SD). Data comparison between the 2 groups was performed using unpaired t-test. Longitudinal changes in the variables were compared between the two groups using 2-way ANOVA based on repeated measurements. The mortality rate was calculated for each patient based on the duration of follow-up. The valve-related events were reported as per the published standard criteria [Akins 2008]. All the statistical analyses were performed using SPSS 13.0 software (IBM, Chicago, IL, USA). A significance level of $P < .05$ was used for all comparisons.

RESULTS

A temporary pacemaker was used for all patients to prevent ventricular fibrillation in the initial 2 days after surgery. Mechanical ventilation support was provided for 24 to 96 hours. No patient received a tracheotomy. All patients received postoperative inotropic support. Warfarin was used for anticoagulation to maintain an international normalized ratio (INR) of 1.8 to 2.5 in the 24 hours postoperative. All patients were administered oral angiotensin converting enzyme (ACE) inhibitors after extubation (0.5 to 1.0 mg/kg every 8 hours) before weaning from inotropic agents. Digoxin, diuretics, and ACE inhibitors were weaned at varying time intervals.

No difference was noted in terms of sex, age, EF, body surface area, left ventricular end-diastolic volume, or preoperative NYHA classification between the 2 groups (Tables 1 and 3). There was no statistically significant difference in the mean left atrium pressure, aortic cross-clamp time, CPB time, postoperative ventilating time, and thoracic tube fluid between the C-MVR group and the P-MVR group (Table 2).

In the C-MVR group, there were 2 cases of low-output syndrome—caused early death (3.4%), 3 cases of malignant ventricular arrhythmia (6.0%), and 8 cases of low cardiac output syndrome (13.8%); in the P-MVR group, there were 4 cases of low-output syndrome—caused early death (5.7%), 7 cases of malignant ventricular arrhythmia (10.0%), 6 cases of multiple organ system failure (8.6%), and 16 cases of low cardiac output syndrome (22.9%).

There were 3 cases of late death 1 year after surgery, of

Table 2. Operative Data of the Study Groups*

Variable	C-MVR Group	P-MVR Group	P
Left atrium pressure, mm Hg (mean \pm SD)	6.5 \pm 3.2	7.1 \pm 1.9	.413
CPB time, min (mean \pm SD)	66.5 \pm 16.2	63.9 \pm 23.0	.079
Clamped aorta time, min (mean \pm SD)	52.5 \pm 14.2	51.6 \pm 17.5	.159
Mechanic time, h (mean \pm SD)	28.2 \pm 5.7	27.6 \pm 7.3	.298
Thoracic tube fluid, mL (mean \pm SD)	292.5 \pm 151.0	312.0 \pm 176.5	.041
Size of prosthetic valve, n (%)			
No. 29	3 (5.1)	6 (8.6)	.687
No. 27	55 (94.8)	64 (91.4)	.096

*SD indicates standard deviation; CPB, cardiopulmonary bypass.

which 1 case in the C-MVR group was caused by congestive heart failure and the other 2 cases in the P-MVR group were due to sudden death. In the P-MVR group, 2 patients suffered from anticoagulant hemorrhage at 6 months and 14 months of the follow-up, respectively, one of whom fully recovered while the other one recovered with residual weakness. In contrast, in the C-MVR group, no thrombosis or embolic complication was observed over the follow-up period.

By end of the follow-up, all survivors in the C-MVR group were NYHA functional class I or II, and 92.8% of the survivors in the P-MVR group were class I or II.

During the follow-up, we did not observe any obstruction of the left ventricular outflow tract or prosthesis-related complication in any patient, and the leaflets of the prostheses were freely mobile. The echocardiographic values of LVEDD, EF, and FS are shown in Table 3 and Figures 3, 4, and 5. In both groups, LVEDD decreased from the preoperative level at the time of discharge and during the late postoperative period. Similarly, in both groups, EF and FS significantly increased at first, which lasted for 3 years. Following that, the C-MVR group exhibited more significant reduction of LVEDD compared to the P-MVR group ($P < .05$). A statistically significant

increase in FS occurred in the C-MVR group compared to the P-MVR group. At the end of 3 months, EF was statistically significantly increased in the C-MVR group compared to the P-MVR group.

DISCUSSION

Preservation of the subvalvular apparatus during MVR, which has been proven to be superior compared to the standard MVR without retention of the subvalvular apparatus, is beneficial for the preservation of left ventricular function and the improvement of long-term survival [Sasaki 2003; Yousefnia 2007; Hosono 2008]. However, the importance of retaining the anterior subvalvular apparatus in addition to the posterior leaflet in patients with chronic mitral insufficiency accompanied by a left ventricular end-systolic dimension of greater than 50 mm remains controversial [Yun 2002].

The Characteristics of Rheumatic Mitral Regurgitation in Patients with an ELVC

Over time, left ventricular architectural disorganization takes place as the dilating left ventricle, changing from

Table 3. Characteristics of Heart Function Recovery of the Study Patients (mean \pm SD)*

Group	Preoperative	At Discharge	3 Months Later	1 Year Later	3 Years Later
Ejection fraction					
C-MVR	53.29 \pm 8.34	57.76 \pm 6.21	62.69 \pm 4.77	61.84 \pm 4.92	60.85 \pm 5.93
P-MVR	54.57 \pm 8.58	58.76 \pm 5.42	61.07 \pm 4.36	61.46 \pm 4.45	61.27 \pm 4.15
P	.395	.334	.047	.641	.621
Left ventricular fractional shortening					
C-MVR	29.89 \pm 4.66	32.41 \pm 3.67	34.34 \pm 3.24	34.74 \pm 3.26	34.37 \pm 3.35
P-MVR	29.66 \pm 4.28	30.81 \pm 2.36	32.34 \pm 2.52	32.50 \pm 2.35	32.66 \pm 2.25
P	.780	.004	.000	.000	.002
Left ventricular end-diastolic diameter					
C-MVR	79.38 \pm 9.55	55.16 \pm 7.28	52.34 \pm 6.32	53.51 \pm 5.66	54.57 \pm 5.90
P-MVR	78.89 \pm 8.99	57.90 \pm 7.33	58.01 \pm 7.71	58.47 \pm 7.73	59.03 \pm 7.36
P	.749	.037	.000	.000	.001

*SD indicates standard deviation.

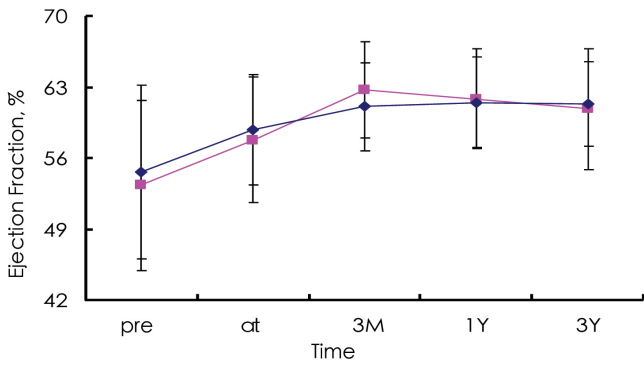


Figure 3. Changes in a left ventricular ejection fraction (EF) according to the type of surgery. Squares indicate C-MVR; diamonds, P-MVR; a, versus preoperative in P-MVR, $P < .05$; b, versus preoperative in C-MVR, $P < .05$; v, versus P-MVR, $P < .05$.

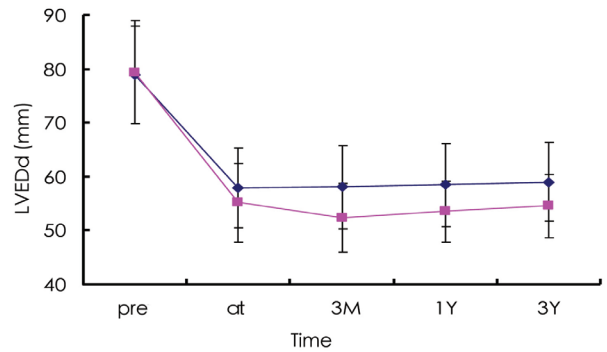


Figure 4. Changes in left ventricular end-diastolic diameter (LVEDD) according to the type of surgery. Squares indicate C-MVR, P-MVR; a, versus preoperative in P-MVR, $P < .05$; b, versus preoperative in C-MVR, $P < .05$; v, versus P-MVR, $P < .05$.

an elliptical to a spherical form, contributes further to the dysfunction [Jacob 1992]. In response to myocardial injury or alteration in loading conditions, the ventricle undergoes changes in geometry, volume, mass, and myocellular structure. The remodeling can be characterized by a progressively disproportionate increase in the ratio of the left ventricle chamber radius to the wall thickness caused by long-term severe regurgitation. An enlarged left ventricular chamber appears in the patients, and they suffer from typical pathological processes. The ejection fraction is one of the most important determinants of long-term survival after mitral valve surgery for mitral regurgitation. Patients with a moderately to severely reduced EF are at considerable risk [Straub 1997]. In our study, most patients suffered from symptoms of repeated congestive heart failure, which, however, did not develop to the end-stage of congestive heart failure. Compared to partial left ventriculectomy and mitral valve repair for end-stage congestive heart failure followed by ischemic cardiomyopathy [Batista 1997], replacement solely is still the procedure indicated in our study. Both groups exhibited good early and late outcomes during the postoperative follow-up, and the improvement in the C-MVR group was more significant compared to the P-MVR group.

Complete Bileaflet with Chordal-Papillary Preservation at the Anatomical Position for Mitral Regurgitation in Patients with an ELVC during MVR: Possibilities and Limitations

The results were not uniform because of the retrospective nature of the investigations, heterogeneous patient populations, and differences in the valvular pathology [Sasaki 2003]. Some studies showed that preservation of the subvalvular apparatus during MVR preserved the left ventricle function and essentially eliminated the dreaded complication of ventricular-annular separation [Yousefina 2007; Hosono 2008]. Some studies demonstrated the superiority of chordal-sparing MVR over conventional MVR, and no significant difference was noted between patients receiving posterior or bileaflet chordal preservation [Okamoto 2006; Alsoufi 2010]. As a result, surgeons have been somewhat reluctant to adopt

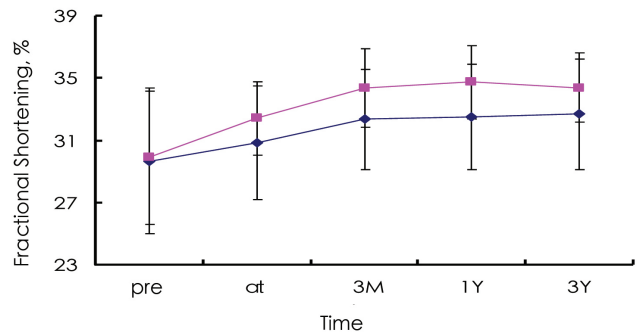


Figure 5. Changes in left ventricular fractional shortening (FS) according to the type of surgery. Squares indicate C-MVR, P-MVR; a, versus preoperative in P-MVR, $P < .05$; b, versus preoperative in C-MVR, $P < .05$; v, versus P-MVR, $P < .05$.

complete anterior and posterior chordal preservation and continue to retain only the posterior leaflet chordae tendinae. This is probably due to very real concerns about multiple factors, including technical complexity, operating time, potential interference with mechanical valve leaflet motion, the demand to undersize the mitral prosthesis, and the possibility of creating a left ventricular outflow tract obstruction [Okamoto 2006].

With increased understanding of the complex anatomical and physiological functions of the mitral valve apparatus, one clear concept that is applicable to MVR based on extensive clinical experience with mitral valve repair techniques is the importance of preserving annular, chordal, and muscle continuity to preserve the left ventricular function. We believe that this technique is very important for patients with an ELVC. First, we supposed that the native direction of the chordae with the papillary could prevent the change of shape from the globular to the elliptical. Second, it is a theoretical consideration that the native chordae could limit

the ventricular dilatation, which in turn may improve the heart function. Finally, after the replacement, the ventricular volume is reduced due to a direct decrease of the preload and an indirect stretching of the chordae by the papillary. In our study, compared to this technique, we preserved the entire mitral valve with the subvalvular apparatus at the native anatomical position, maintained the continuity of the annulus, valve, chordae and papillary muscle, but did not incise the mitral valve body or chordae. We incised the commissure to implant the appropriate prosthesis only when necessary. According to our experience, the technique to preserve the mitral leaflet with the subvalvular apparatus at the native anatomical position during the MVR for rheumatic mitral regurgitation in patients with an ELVC was safe and feasible. It was very important for patients with an ELVC.

Another argument against preservation of the anterior leaflet was that an undersized valve prosthesis could be implanted [Athanasios 2008; García-Fuster 2008]. However, compared to previous studies, the patients in our study predominantly suffered from mitral regurgitation with an ELVC. It is possible to perform the preservation of complete bileaflet with chordal-papillary at the native anatomical position for patients with mitral regurgitation with an ELVC during MVR. These patients had an ELVC with an enlarged annulus, and there was too big a place for the plication from the mitral valve apparatus to the annulus. In our study, we implanted 27 to 29 mm prostheses into all patients with total chordal preservation at the anatomic position, which was similar to the preservation of the posterior mitral valve, suggesting that the preservation of the anterior mitral leaflet did not preclude the implantation of an appropriate prosthesis. There was no left ventricular outflow tract obstruction observed in this study. Given the possibility of the postoperative reduction of the dilated left ventricular chamber, we maintained the tension of the chordae and papillary by suturing the junction between them to the annulus. However, there was the possibility that rheumatic pathologic changes might occur following the thickening and hardening of the chordae tendinae.

Complete Bileaflet with Chordal-Papillary Preservation at the Native Anatomical Position for Mitral Regurgitation with GCLV during MVR: Effects on Left Ventricular Volume and Functions

The left ventricular EF continued to increase over time in the P-MVR group ($P < .05$) and did not recover until 3 years later. In light of the obstruction of the left ventricular outflow tract and the undersized prosthesis, the patients who suffered from severe mitral stenosis and/or mitral valvular calcification were excluded from this study. One randomized study by Yun et al suggested similar results [Yun 2002]. They found that complete retention of the mitral subvalvular apparatus during MVR conferred a significant early advantage by reducing the left ventricular chamber size and the systolic afterload compared to partial chordal preservation. Furthermore, the performance of the left ventricular ejection continued to improve over time, probably because of the more favorable left ventricular remodeling.

The merits of retaining the subvalvular apparatus during the MVR for chronic mitral regurgitation on the left ventricular volume and function have been demonstrated by numerous retrospective clinical investigations [Yun 2002; Sasaki 2003; Yousefnia 2007; Hosono 2008].

Yet, little is known about the merits of complete mitral valve preservation during the MVR for rheumatic mitral regurgitation with ELVC (greater than 70 mm). Previous studies demonstrated a poor outcome in those undergoing MVR with such left ventricular decompensation or end-systolic diameters of greater than 50 mm, despite the chordal preservation [Yun 2002; Cingöz 2004]. Yun et al suggested that left ventricle volume and systolic performance deteriorated after 1 year [Yun 2002]. Only 1 of the 4 patients with a preoperative end-systolic diameter of greater than 50 mm (1 in the P-MVR group and 3 in the C-MVR group) showed reductions in end diastolic volume (EDV), end systolic volume (ESV), end-systolic stress (ESS), and left ventricular mass (LVM) and improvement in EF, FS, and ESS/ESV ratio after 1 year.

Compared to Yun et al, our study showed that this cohort performed better in both the early and late periods after the operation, providing further support to the importance of retaining the whole mitral subvalvular apparatus. The reason that our study showed such a result is unclear. It is likely that the reduction in the cavity volume by shortening the distance between the base of the papillary muscle and the annulus using the technique of stretching the chordae to the annulus can maintain the shape of the chamber by preserving the chordae in the native direction. One alternative reason could be that in our study, the valve etiology was rheumatic, whereas in other studies, most patients showed degeneration and ischemic etiology [Yun 2002; Cingöz 2004]. In addition, the patients in our study were very young compared to those in other studies. We think the most important thing was that almost all of our patients just suffered from a heavy overload of volume due to severe mitral regurgitation, with or without aortic regurgitation. Comparing our patients to those suffering from ischemic cardiomyopathy or degeneration, one possible concomitant lies in the cardiocyte necrosis and heavy fibrosis of the cardiac tissue. The dysfunction of the heart might be organic compared to the functional dysfunction of the heart in our patients. For most preserving mitral techniques, the mitral valve body was resected, the remaining mitral valve with the chordae was transplanted and reattached to the posterior annulus or correspondent annulus. In contrast, we preserved the complete mitral valve with the subvalvular apparatus at the native anatomical position but did not incise the mitral valve body or the chordae, and maintained the native continuity of the annulus, valve, chordae, and papillary muscle. We think our technique is very important for those patients with an ELVC as discussed above.

CONCLUSION

In summary, this study shows that our modification of total mitral leaflet and chordal preservation at the anatomical position is feasible for the majority of patients with an ELVC

undergoing MVR for rheumatic mitral regurgitation. A prosthesis of an appropriate size can be implanted despite bileaflet preservation. This technique provides superior results during both the early postoperational period and the long-term follow-up compared to partial chordal preservation with the native structure and geometry.

REFERENCES

- Akins CW, Miller DC, Turina MI, et al. 2008. Guidelines for reporting mortality and morbidity after cardiac valve interventions. *J Thorac Cardiovasc Surg* 135:732-8.
- Alsoufi B, Al-Shahid M, Manlhiot C, et al. 2010. Mitral valve replacement with the Quattro stentless pericardial bioprosthesis: mid-term clinical and echocardiographic follow up. *J Heart Valve Dis* 19:304-11.
- Athanasiou T, Chow A, Rao C, et al. 2008. Preservation of mitral valve apparatus: evidence synthesis and critical reappraisal of surgery techniques. *Eur J Cardiothorac Surg* 33:391-401.
- Batista RJ, Verde J, Nery P, et al. 1997. Partial left ventriculectomy to treat end-stage heart disease. *Ann Thorac Surg* 64:634-8.
- Chowdhury UK, Kumar AS, Airan B, et al. 2005. Mitral valve replacement with and without chordal preservation in a rheumatic population: serial echocardiographic assessment of left ventricular size and function. *Ann Thorac Surg* 79:1926-33.
- Cingöz F, Günay C, Kuralay E, et al. 2004. Both leaflet preservation during mitral valve replacement: modified anterior leaflet preservation technique. *J Card Surg* 19:528-34.
- David TE, Uden DE, Strauss HD. 1983. The importance of the mitral apparatus in left ventricular function after correction of mitral regurgitation. *Circulation* 68:II76-82.
- García-Fuster R, Estevez V, Gil O, Cánovas S, Martínez-Leon J. 2008. Mitral valve replacement in rheumatic patients: effects of chordal preservation. *Ann Thorac Surg* 86:472-81.
- Hosono M, Shibata T, Sasaki Y, et al. 2008. Left ventricular rupture after mitral valve replacement: risk factor analysis and outcome of resuscitation. *J Heart Valve Dis* 17:42-7.
- Jacob R, Dierberger B, Kissling G. 1992. Functional significance of the Frank-Starling mechanism under physiological and pathophysiological conditions. *Eur Heart J* 13:7-14.
- Okamoto K, Kiso I, Inoue Y, Matayoshi H, Takahashi R, Umezu Y. 2006. Left ventricular outflow obstruction after mitral valve replacement preserving native anterior leaflet. *Ann Thorac Surg* 82:735-7.
- Sasaki H, Ihashi K. 2003. Chordal-sparing mitral valve replacement: pitfalls and techniques to prevent complications. *Eur J Cardiothorac Surg* 24:650-2.
- Straub UJ, Huwer H, Kalweit G, Volkner I, Gams E. 1997. Improved regional left ventricular performance in mitral valve replacement with orthotopic refixation of the anterior mitral leaflet. *J Heart Valve Dis* 6:395-403.
- Yousefnia MA, Mandegar MH, Roshanali F, Alaeddini F, Amouzadeh F. 2007. Papillary muscle repositioning in mitral valve replacement in patients with left ventricular dysfunction. *Ann Thorac Surg* 83:958-63.
- Yun KL, Sintek CF, Miller DC, et al. 2002. Randomized trial comparing partial versus complete chordal-sparing mitral valve replacement: effects on left ventricular volume and function. *J Thorac Cardiovasc Surg* 123:707-14.