

Key-Lock Type Mini-Sternotomy: An Alternative Approach for Adult Cardiac Operations

Mert Dumantepe, Arif Tarhan, Azmi Ozler

Department for Cardiovascular Surgery, Memorial Atasehir Hospital, Istanbul, Turkey

ABSTRACT

An alternative technique for minimally invasive aortic valve replacement and atrial septal defect repair is described. After a 5-cm skin incision, a key-lock type sternotomy is made. Excellent exposure of the right atrium and aortic valve was achieved. The configuration of the mini-sternotomy (or the lock) limits the movement of the sternal surfaces (or the keys) on the lateral and craniocaudal directions.

INTRODUCTION

During the last 2 decades, the interest in minimally invasive techniques, either by avoiding cardiopulmonary bypass or by limiting the incision, has been increasing in all fields of cardiac surgery. Different limited sternal approaches have been described, including partial upper or lower J-, T-, S-, I-, or C-shaped sternotomies, for valve operations and the repair of common congenital heart defects Autschbach 1998; Ak 2007. Although the sternal cut is limited, vertical or horizontal sternal division would still exist to some extent and therefore would be responsible for postoperative sternal instability Autschbach 1998. Moreover, the friction of the sternal leafs on each other after forced respiration and mobilization may cause increased postoperative pain Walther 1999. To overcome these problems, we developed a key-lock sternotomy.

TECHNIQUE

After a 5-cm median skin incision (Figure 1A), the subcutaneous tissue and the intercostal muscles around the level of the right third to fifth intercostal spaces (ICS) are carefully dissected. Care is taken to avoid damage to the right internal mammary artery. The sternotomy is started from the right border in the third ICS. After a very short horizontal sternal cut, the striker is directed superiorly toward the midline. At the level of the second ICS and slightly on

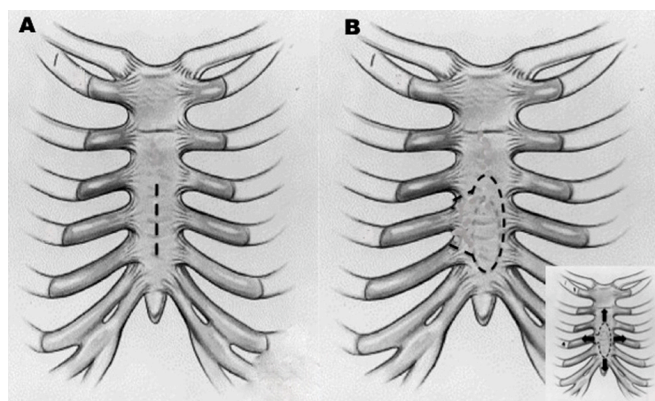


Figure 1. A, Median skin incision from the lower third to the upper fifth intercostal space. B, Key-lock mini-sternotomy. It starts from the right third to the fourth or fifth intercostal space. Its unique configuration limits the free movement of the sternal piece.

the left half of the sternum, the striker is directed inferiorly down to the level of the fourth or fifth ICS. At that level, the striker is directed upward toward the right border of the sternum, and the incision is completed (Figure 1B). For atrial septal defect repair, the mini-sternotomy starts from the third to the fourth ICS; for aortic valve replacement, starting from the third to the fifth ICS is preferred. After a vertical pericardiotomy, the intrapericardial structures, including the superior vena cava, the right atrium, the inferior vena cavae, and the ascending aorta, are exposed. The right common femoral artery and vein are exposed and cannulated. The superior vena cava is cannulated centrally. Bicaval taping is performed, and aortic cross-clamping is performed through the sternotomy. Cardioplegia is applied via the aortic root in all patients. This approach provides exposure of the aortic valve and the right atrium.

DISCUSSION

Although the issue is still debatable, minimally invasive approaches are claimed to be associated with reduced postoperative pain, shorter hospital stays, and improved convalescence in patients who undergo cardiac surgery. Moreover, the patient's satisfaction postoperatively and with respect to

Received July 30, 2012; accepted March 19, 2013.

Correspondence: Mert Dumantepe, Merit Life Göl Konakları Sitesi, A-5 Blok, Kat: 7 Daire: 20, Serifali/Umraniye 34660, Istanbul, Turkey; 90-216-5082702; cell: 90-532-3771872 (e-mail: mdumantepe@gmail.com).

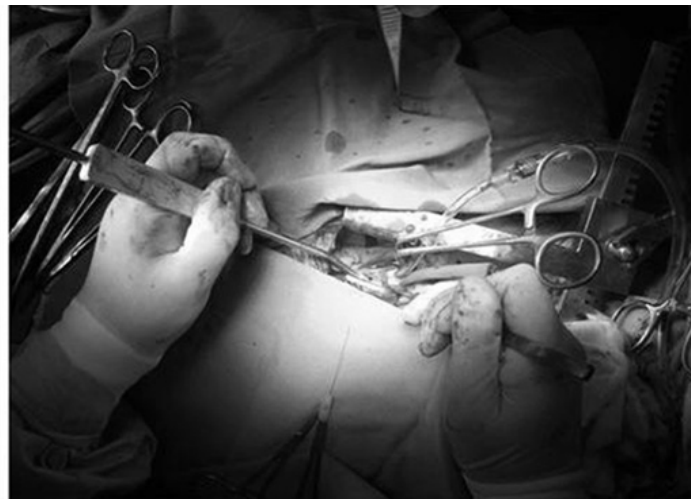
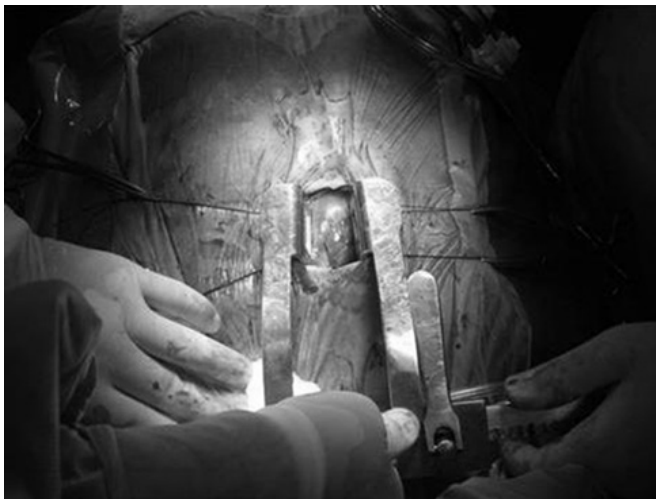
Figure 2. Operative view of the patient during aortic valve replacement.

the cosmetic outcome after minimally invasive procedures is higher than for a standard median sternotomy Bakir 2006. From February 2008 to the present, we successfully performed aortic valve replacement in 6 adult patients (a mechanical prosthesis in all patients) and atrial septal defect repair 10 adult patients (primary repair in 7 patients, a patch in 3) by using a 5-cm skin incision and a key-lock mini-sternotomy. The exposure was excellent in all cases (Figure 2), and conversion to a median sternotomy is easy when necessary. Early postoperative transesophageal echocardiography evaluations revealed a completely patent interatrial septum and a normally functioning aortic prosthesis in all cases. This approach was associated with less postoperative pain and a better cosmetic outcome. The cardiopulmonary bypass, cross-clamping, and operative times were comparable to those of a standard median sternotomy. None of the patients in these cases experienced a sternal or femoral wound-healing problem.

Apart from other minimally invasive sternal incisions, the most important unique feature of key-lock type mini-sternotomy is that it opens only a window on the sternum, rather than partial or complete splitting of the sternum. Therefore,

this procedure disrupts the sternal integrity to a minimal degree. Moreover, our approach limits the movement of the sternal surfaces in the lateral and craniocaudal directions, which might account for better sternal stability, less friction of the sternal surfaces, and thereby less postoperative pain. However, the potential risks of femoral cannulation should not be underestimated.

REFERENCES

- Ak K, Aybek T, Wimmer-Greinecker G, et al. 2007. Evolution of surgical techniques for atrial septal defect repair in adults: a 10-year single-institution experience. *J Thorac Cardiovasc Surg* 134:757-64.
- Autschbach R, Walther T, Falk V, Diegeler A, Metz S, Mohr FW. 1998. S-shaped in comparison to L-shaped partial sternotomy for less invasive aortic valve replacement. *Eur J Cardiothorac Surg* 14:S117-21.
- Bakir I, Casselman FP, Wellens F, et al. 2006. Minimally invasive versus standard approach aortic valve replacement: a study in 506 patients. *Ann Thorac Surg* 81:1599-604.
- Walther T, Falk V, Metz S, et al. 1999. Pain and quality of life after minimally invasive versus conventional cardiac surgery. *Ann Thorac Surg* 67:1643-7.