

Blood Cyst of the Anterior Leaflet of the Mitral Valve in an Asymptomatic Adult: Is Surgery an Objective?

Edward Ansari, MD, Payam Akhyari, MD, PhD, Artur Lichtenberg, MD, PhD

Department of Cardiovascular Surgery, Heinrich-Heine University Hospital, Düsseldorf, Germany

ABSTRACT

Blood cysts of the heart are rare benign tumors that usually involve the cardiac valves and are mainly found in fetuses and very early in life. However, no consensus on the surgical management of asymptomatic cases has been postulated. We believe surgical resection should be performed in patients with symptoms, tumor growth, and valvular dysfunction. We report a case of a blood cyst of the anterior leaflet of the mitral valve, which was incidentally discovered in a 55-year-old man.

INTRODUCTION

In adolescents and adults, blood cysts of the heart are very rare findings [Zimmerman 1983]. In the scientific literature, blood cysts have been most often reported (within the heart) on valvular structures or in the chambers of the heart [Arnold 1990; DeGross 1995].

Here we present a patient with a blood cyst attached to the anterior mitral leaflet (AML), which was discovered incidentally during routine echocardiographic evaluation and on a subsequent stress MRI performed for the evaluation of a left anterior descending (LAD) artery stenosis.

CASE REPORT

A 55-year-old man with a medical history of myocardial infarction after right coronary artery (RCA) occlusion with balloon angioplasty and stent implementation in 2001 presented for routine follow-up with no current symptoms (NYHA I). A transthoracic echocardiography (TTE) revealed normal ventricular size and function and normal mitral valve function; however, a round structure with hyperechogenic walls and a hypoechogenic content was observed. Subsequent transesophageal echocardiography (TEE) showed a 26 × 21 mm-sized structure attached to the AML and posteromedial chordae of the papillary muscle, accompanied by light mitral valve insufficiency without hemodynamic significance. A cardiac MRI displayed central contrast enhancement in the cystic structure. Due to the absence of symptoms and based

on the normal ventricular and valvular function, follow-up at 6 months was performed. Cardiac MRI demonstrated a slight increase in cyst size, suggesting a progressive process and left ventricular wall dyskinesia. Cardiac catheterization showed significant stenosis of the LAD artery, although at this time, the patient denied any cardiac symptoms. Thorough cardiac and neurological work-up as well as laboratory tests remained unremarkable. After reaching interdisciplinary consensus within the heart team, the patient was referred to surgery to address LAD stenosis and for excision of the cyst.

Operative access was achieved via median sternotomy. Upon exploration, a cystic mass of livid blue color with a translucent membrane presented as attached to the ventricular surface of the AML in A2 projection (Figures 1 and 2). The excised cystic formation measured 3.4 cm × 1.5 cm × 1 cm and was filled with blood and serosanguineous fluid. Mitral valve reconstruction with implantation of neochordae to the AML and stabilization of the annulus using a 30-mm Carpentier-Edwards Physio annuloplasty ring was performed. Furthermore, the left internal mammary artery was anastomosed to the LAD artery.

Upon histologic examination (hematoxylin and eosin, periodic acid-Schiff staining) the cystic wall demonstrated a pattern similar to cardiac valve architecture with endothelial lining cells on the outer layer and an underlying compact layer of lamina fibrosa and spongiosa.

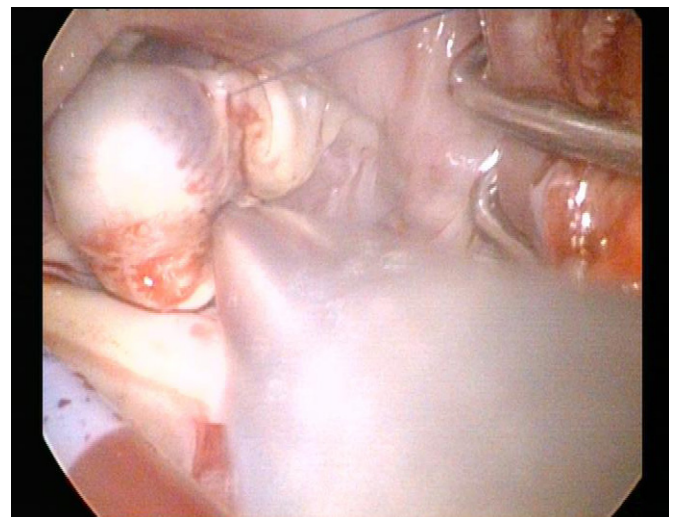


Figure 1. A cystic mass attached to the ventricular surface of the AML in A2 projection.

Received September 22, 2014; received in revised form May 26, 2015; accepted May 28, 2015.

Correspondence: Payam Akhyari, Department of Cardiovascular Surgery, Moorenstraße 5, 40225 Düsseldorf, Germany; +49 (0)211-81-18331; fax: +49 (0)211-81-18333 (e-mail: Payam.Akhyari@med.uni-duesseldorf.de).

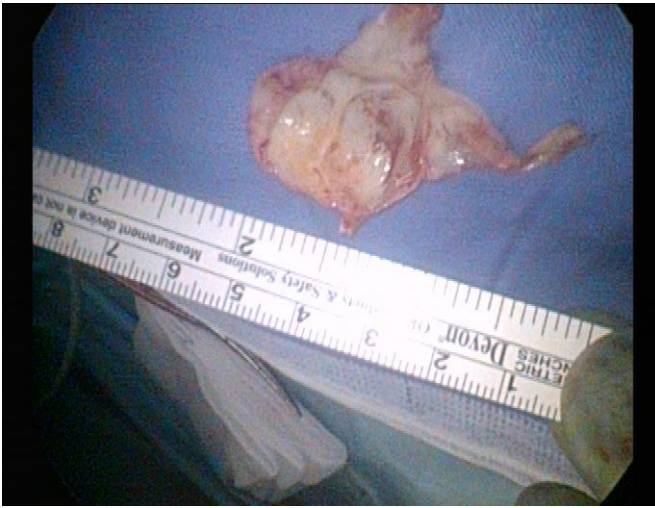

Figure 2. The dimension of the cystic mass measured 3.4 cm × 1.5 cm × 1 cm.

The patient was discharged from the hospital on postoperative day 8 after an uneventful postoperative course and maintained on anticoagulation for three months. Follow-up TTE at three months revealed no recurrence of any intracardiac mass and a competent mitral valve.

DISCUSSION

Valvular blood cysts have been reported in postmortem examinations of fetuses and infants, with a prevalence ranging from 25% to 100% [Zimmerman 1983]. In adolescents and adults, such cysts regress spontaneously and are small and mostly asymptomatic [Zimmerman 1983]. However, potential complications include left ventricular outflow tract (LVOT) obstruction, embolic stroke, or valvular dysfunction.

Clear understanding of the pathophysiological cause and the natural fate of intracardiac blood cysts is lacking [Xie 1992; Kuvin 2004; Kurtoğlu 2005]. It has been hypothesized that blood cysts are formed during valve development as a result of blood being pressed and trapped in crevices that are later sealed off. Alternatively, blood cysts may also be the result of hematoma formation in the subvalvular apparatus secondary to the occlusion of small vascular branches due to various pathologic conditions, such as inflammation, vagal

nerve induced constriction, anoxia, or hemorrhagic events. Finally, blood cysts may simply represent ectatic or dilated vascular structures in the valve leaflets or they might even represent angiomas.

Irrespective of the developmental path, decision finding on therapeutic steps remains challenging. Dencker et al [Dencker 2009] described a conservative approach in an asymptomatic patient with a minor cyst, recommending surgical resection only in case of symptoms or any cardiac dysfunction. Although our patient was asymptomatic and the cyst did not impair cardiac function, we opted for surgical resection in face of documented growth progression and with the aim of preventing possible complications, such as mitral valve dysfunction or LVOT obstruction. The latter complications were considered as likely to happen, considering the particular location of the cyst at the AML. The general indication for open heart surgery was further strengthened by significant LAD stenosis, providing AI recommendation for coronary artery bypass grafting in compliance with current guidelines.

In conclusion, surgical resection is deemed to be a safe course in patients with symptoms, tumor growth, and valvular dysfunction.

REFERENCES

- Arnold IR, Hubner PJ, Firmin RK. 1990. Blood filled cyst of the papillary muscle of the mitral valve producing severe left ventricular outflow tract obstruction. *Br Heart J* 63:132-3.
- DeGroff C, Silberbach M, Sahn DJ, Droukas P. 1995. Giant blood cyst of the aortic valve. *J Am Soc Echocardiogr* 8:543-5.
- Dencker M, Jexmark T, Hansen F, Tydén P, Roijer A, Lühns C. 2009. Bileaflet blood cysts on the mitral valve in an adult. *J Am Soc Echocardiogr* 22:1085.e5-8.
- Kurtoğlu N, Yildirim T, Uzunlar B, Cevik C, Incedere O, Dindar I. 2005. A rare case: blood cyst of the mitral valve. *Anadolu Kardiyol Derg* 5:346.
- Kuvin J, Saha P, Rastegar H, Salomon RN, Pandian N, Denofrio D. 2004. Blood cyst of the mitral valve apparatus in a woman with a history of orthotopic liver transplantation. *J Am Soc Echocardiogr* 17:480-2.
- Xie SW, Lu OL, Picard MH. 1992. Blood cyst of the mitral valve: detection by transthoracic and transesophageal echocardiography. *J Am Soc Echocardiogr* 5:547-50.
- Zimmerman KG, Paplanus SH, Dong S, Nagle RB. 1983. Congenital blood cysts of the heart valves. *Hum Pathol* 14:699-703.