

## How to Handle Remote Access Perfusion for Endoscopic Cardiac Surgery

Thomas Schachner, Nikolaos Bonaros, Gudrun Feuchtner, Ludwig Müller, Günther Laufer, Johannes Bonatti

Department of Cardiac Surgery and Radiology, Innsbruck Medical University, Innsbruck, Austria

### ABSTRACT

**Introduction:** Remote access is a prerequisite for endoscopic cardiac surgery on the arrested heart. Despite careful patient selection, technical problems and complications occur with the use of this sophisticated technique, and we aim to describe these problems and suggest solutions.

**Patients and methods:** From 2001 to 2004 remote access cardiopulmonary bypass (CPB) was installed in 70 patients, aged 55 (16-70) years. The operations performed were AHTECAB in 44, ASD repair via minithoracotomy in 10, totally endoscopic ASD repair in 11, and minimally invasive mitral valve operation in 5 cases. CPB time was 134 (72-342) minutes and aortic endoocclusion time was 70 (35-223) minutes.

**Results:** In 3 cases the guide wire had to be detected in the aortic root fluoroscopically because it could not be detected in the aortic root on TEE. Initial balloon migration requiring repositioning occurred in 30 cases. After achieving a stable balloon position and incision of the atrium/coronary artery balloon migration occurred in 2 cases, which could be overcome by a quick repositioning maneuver. In 1 patient no stable position of the balloon could be achieved and conversion to median sternotomy was necessary.

Balloon rupture occurred in 2 cases. In one case, rupture of the balloon occurred before the endoscopic LIMA-to-LAD anastomosis was started. The cannula could be successfully replaced and the TECAB procedure finished without complications. In the second case, the balloon ruptured after finishing the LIMA-to-LAD anastomosis and no replacement of the cannula was necessary.

Inadequate CPB flow was found in 1 case, and sufficient flows were achieved by an additional 15 F arterial cannula which was placed in the contralateral groin.

We had no major surgical complication related to the use of the remote access perfusion device, such as aortic dissection, leg ischemia reperfusion injury, or neurological injury

*Presented at the 2nd Integrated Coronary Revascularization (ICR) Workshop for Interventional Cardiologists and Cardiac Surgeons, Innsbruck, Austria, February 24-25, 2005.*

*Address correspondence and reprint requests to: Thomas Schachner, MD, Department of Cardiac Surgery, Medical University Innsbruck, Anichstrasse 35, 6020 Innsbruck, Austria; 43 512 504 80820; fax: 43 512 504 22528 (e-mail: Thomas.Schachner@uibk.ac.at).*

and no hospital death. Wound infection of the groin occurred in 1 patient, which resolved after surgical revision. Ten patients suffered temporarily from lymphatic secretion of the groin.

**Conclusion:** Remote access is technically challenging, but most difficulties can be overcome if regular application by a dedicated team is guaranteed. Remote access perfusion can be performed with an acceptable risk if exclusion criteria are carefully observed.

### INTRODUCTION

Remote (femoral) access is a prerequisite for endoscopic cardiac surgery on the arrested heart. The HEARTPORT™ (Heartport Inc., CA) and the ESTECH™ (ESTECH Inc., CA) devices are the most commonly used balloon carrying arterial perfusion catheters which enable endoocclusion of the ascending aorta and application of cardioplegic solution. The spectrum of endoscopic cardiac surgery covers CABG, mitral valve repair/replacement, and ASD repair. The thoracic access is gained either by a right-sided minithoracotomy or in a totally endoscopic fashion using robotic technology [Bonaros 2004, Bonatti 2004, Reichensperner 1998, Schroeyers 2001]. Careful patient selection and diagnosis of contraindications for the use of remote access perfusion catheters (e.g., ascending aortic dilatation, severe aortic atherosclerosis, and significant aortic valve regurgitation) are important issues. However, technical problems and complications occur with the use of this sophisticated technique, and it is the aim of our study to describe these problems and suggest their possible solution.

### PATIENTS AND METHODS

From 2001 to 2004, remote access cardiopulmonary bypass (CPB) was installed in 70 patients. The ESTECH™ RAP cannula was used in 60 patients and the HEARTPORT™ device was used in 10 patients. Median age of this patient cohort was 55 (16-70) years and 36 out of 70 (51%) patients were male. The operations performed were AHTECAB in 44, ASD repair via minithoracotomy in 10, totally endoscopic ASD repair in 11, and minimally invasive mitral valve operation in 5 cases. AHTECAB and totally endoscopic ASD repair were carried out with the Da Vinci™ telemanipulator system (Intuitive Inc., Sunnyvale, CA).

Median CPB time was 134 (72-342) minutes and aortic endoocclusion time was 70 (35-223) minutes.

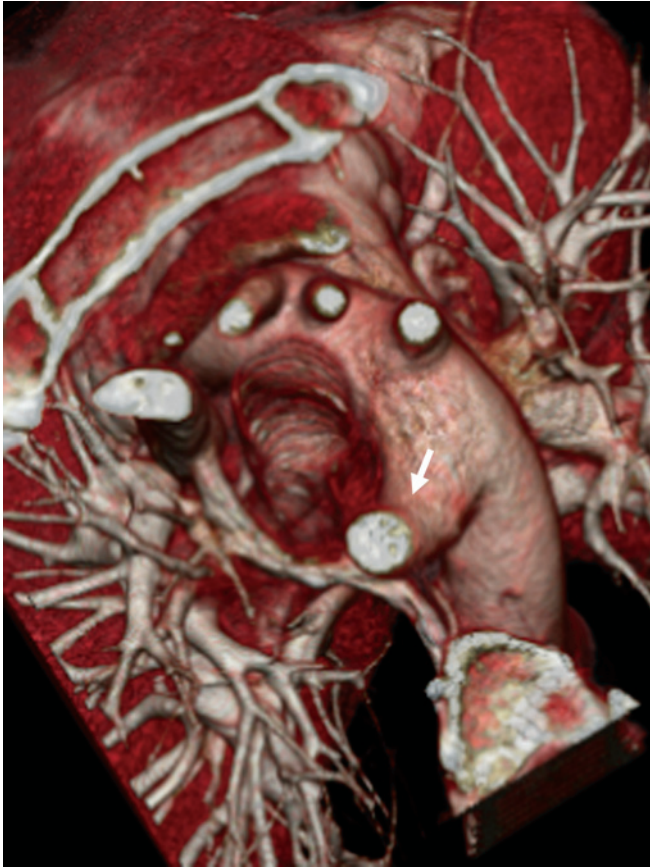

Figure 1. 3D reconstruction of a preoperative multislice CT scan showing an aberrant right subclavian artery coming as first branch of the descending thoracic aorta (i.e., arteria lusoria, marked by a white arrow).

### **Surgical Technique**

We have previously described the surgical technique in detail [Schachner 2004].

In brief, the patient was monitored intraoperatively by bilateral radial artery pressure lines and transesophageal echocardiography (TEE).

The femoral vessels were exposed 1 cm below the inguinal ligament. After systemic heparinization a 23, 25 or 27 F venous cannula (Biomedicus™, Medtronic Inc.) was inserted into the femoral vein using the Seldinger technique under TEE control.

A 5 or 6 F arterial access sheath (Arrow Inc., Reading, PA) which was later on connected to the arterial perfusion was placed into the proximal superficial femoral artery for distal perfusion of the leg.

The proximal and distal part of the femoral artery were clamped with 120° vascular clamps. After performing a 1 cm longitudinal incision, the cannula was advanced into the ascending aorta under TEE control (guide wire technique). The tip of the cannula was placed approximately 1 cm distally to the aortic valve. CPB was started. After sufficient CPB flows were achieved, the aortic occlusion balloon was insufflated and cardiac arrest was induced by a single shot of diluted adenosine and maintained with cold St. Thomas cardioplegic solution. The proper catheter balloon position was continuously moni-

tored by TEE and bilateral radial artery pressure curves. Vacuum-assisted venous drainage was used in all cases.

After stopping the CPB and decannulation, the femoral artery was reconstructed with a Gore tex™ patch or preferentially with a pericardial patch.

### **Statistics**

Continuous variables are given as median (minimum–maximum), categorical variables are shown as absolute values and percentages.

## **RESULTS**

### **Technical Challenges**

In 4 out of 70 (5.7%) patients, the exposed femoral artery seemed to be too narrow for the cannula. Local application of nitroglycerine or predilatation with the obturator of the venous cannula facilitated arterial cannulation in all 4 patients.

The guide wire could not be detected in the aortic root in 3 out of 70 (4.3%) cases. In 1 patient the aortic root could only be insufficiently visualized in TEE. In 2 patients the guide wire escaped into a supraaortic branch. In 1 of these 2 patients an arteria lusoria was present (Figure 1). In all 3 cases the guidewire could be successfully localized by fluoroscopy using a mobile C-arm.

Balloon migration requiring repositioning at the beginning of aortic occlusion occurred in 30 out of 70 (43%) cases. With the ESTECH(tm) device, initial balloon migration occurred in 22 out of 60 (37%) cases. After achieving a stable balloon position and incision of the atrium/coronary artery balloon migration occurred in 2 cases. A quick repositioning maneuver could be performed and the operation continued uneventfully. In 1 patient no stable position of the balloon could be achieved and conversion to median sternotomy was necessary.

We noted a drop in the balloon pressure in most of our patients. In 16 patients we quantified the balloon pressure drop, which was 58 (0-100) mm Hg.

Balloon rupture occurred in 2 out of 70 (2.9%) cases. In one case, rupture of the balloon occurred before the endoscopic LIMA-to-LAD anastomosis was started. The cannula could be successfully replaced and the TECAB procedure finished without complications. In the second case, the balloon ruptured after finishing the LIMA-to-LAD anastomosis and no replacement of the cannula was necessary.

Inadequate CPB flow was found in 1 patient with thin femoral vessels, where only a 17 F RAP system was applicable. We introduced a 15 F arterial cannula contralaterally and connected it with the 17 F cannula to achieve sufficient CPB flows (Figure 2).

### **Surgical Complications**

We had no major surgical complication related to the use of the remote access perfusion device, such as aortic dissection, leg ischemia reperfusion injury, or neurological injury and no hospital death in our series (Table).

Wound infection of the groin occurred in 1 (1.4%) patient, which resolved after surgical revision. 10 (14.3%) patients suffered temporarily from lymphatic secretion of the

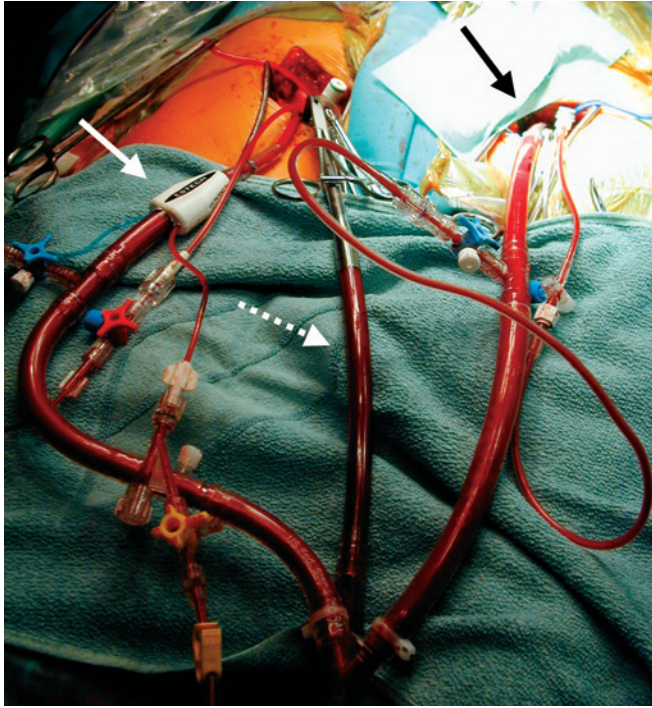


Figure 2. Additional 15 F arterial cannula (black arrow) connected with remote access perfusion cannula (white arrow) to achieve sufficient CPB flow. The venous return cannula is marked by a broken white arrow.

groin. In none of the 10 patients surgical treatment of the groin was necessary.

**DISCUSSION**

Remote access perfusion is a very sophisticated technique and technical challenges are encountered quite frequently (in about 50% of the cases). With practice and frequent application, however, the majority of these problems can be solved.

In less than 5% of our patients, the location of the

guidewire was impossible with TEE alone. In all of these patients location was performed successfully with fluoroscopy. We recommend to have a mobile C-arm in standby to save time if fluoroscopy is required.

In almost two thirds of our patients, we could achieve a stable balloon position initially. In one third of the patients repositioning maneuvers were necessary. Thus, it seems advantageous that the same surgical team uses remote access perfusion to gain experience and develop a “feeling” for the balloon catheter. Dogan et al described balloon migration in 3 out of 20 patients and balloon rupture in 1 out of 20 undergoing mitral valve surgery using the Heartport(tm) device. This group chose the placement of a transthoracic aortic clamp, which is a good alternative in cases undergoing minithoracotomy [Dogan 2005]. Concerning balloon rupture, which occurred in two of our cases, mechanical stress to the balloon by repetitive inflations as well as aortic wall quality may have played a role [Schachner 2004].

Inadequate CPB flow can be a limiting problem for cardiac operations using remote access perfusion. Casselman et al. found inadequate CPB flows in 3 out of 306 cases of remote access mitral valve surgery, and this group had to convert to median sternotomy in these 3 patients [Casselmann 2003]. In 1 case of insufficient pump flow in our series we could successfully install bifemoral CPB and finish the procedure endoscopically. However, if a problem with remote access perfusion cannot be solved easily we have a low threshold to convert the patients to sternotomy for installation of standard CPB.

Complications of remote access perfusion have to be kept in mind. The most important complication is aortic dissection which is described in the range between .3% and .7% in the largest series (more than 150 patients) [Grossi 1999, Casselman 2003]. Important steps to prevent aortic dissections are the use of very soft catheter tips of the new generation devices and the avoidance of completely retrograde perfusion with the ESTECH device. Most of all we think that the ESTECH cannula provides some protection against retrograde aortic dissection as the arterial blood stream enters the descending thoracic aorta through multiple sideholes. In

**Major Complications of Remote Access Perfusion with Balloon Carrying Catheters\***

Author/Year	n	Procedures	Aortic Dissection	Leg Ischemia	Stroke
Glower 1998	21 H	MVR	0 (0%)	1 (4.8%)	
Reichenspurner 1998	59 H	CABG	1 (1.6%)		
Grossi 1999	302	CABG	1 (.3%)		5 (1.7%)
Grossi 2001	100	MVR	0 (0%)		
Van Nooten 2001	63 E	CABG/MVR	0 (0%)	0 (0%)	0 (0%)
Schroeyers 2001	121 H	MVR	2 (2.6%)		
Dogan 2002	20 H	CABG	1 (5%)		0 (0%)
Dogan 2002	45 HE	CABG	0 (0%)	1 (2.2%)	1 (2.2%)
Casselmann 2003	306	MVR	2 (.7%)		1 (.3%)
Casselmann 2003	187	MVR	1 (.5%)		
Argenziano 2003	17 E	ASD	0 (0%)	1 (5.9%)	0 (0%)
Reichenspurner 2005	60 H	MVR	0 (0%)		0 (0%)
Schachner current series	70 HE	CABG/ASD/MVR	0 (0%)	0 (0%)	0 (0%)

\*E indicates ESTECH device; H, Heartport device.

addition preoperative evaluation of the aorta and the iliac arteries by CT angiography was carried out in all our patients. Patients with severe atherosclerosis or other pathology such as aneurysmal disease were rigorously excluded from remote access perfusion.

Leg ischemia reperfusion injury has been described in single cases in literature [Glower 1998, Dogan 2002, Argenziano 2003]. We found no case of this serious complication in our series, but we preventively perform distal femoral perfusion in all our patients.

## CONCLUSION

Remote access CPB is necessary for endoscopic and limited access cardiac surgery on the arrested heart. The method is technically challenging, but most difficulties can be overcome if regular application by a dedicated team is guaranteed. Remote access perfusion can be performed with an acceptable risk if exclusion criteria are carefully observed.

## REFERENCES

- Argenziano M, Oz MC, Kohmoto T, et al. 2003. Totally endoscopic atrial septal defect repair with robotic assistance. *Circulation* 108(II):191-4.
- Bonaros N, Schachner T, Oehlinger A, et al. 2004. Experience on the way to totally endoscopic atrial septal defect repair. *Heart Surg Forum* 7(5):E440-5.
- Bonatti J, Schachner T, Bernecker O, et al. 2004. Robotic totally endoscopic coronary artery bypass: Program development and learning curve issues. *J Thorac Cardiovasc Surg* 127:504-10.
- Casselmann FP, Van Slycke S, Wellens F, et al. 2003. Mitral valve surgery can now routinely be performed endoscopically. *Circulation* 108(II):48-54.
- Dogan S, Aybek T, Andressen E, et al. 2002. Totally endoscopic coronary artery bypass grafting on cardiopulmonary bypass with robotically enhanced telemanipulation: Report of forty-five cases. *J Thorac Cardiovasc Surg* 123:1125-31.
- Dogan S, Graubitz K, Aybek T, et al. 2005. How safe is the port-access technique in minimally invasive coronary artery bypass grafting? *Ann Thorac Surg* 74:1537-43.
- Glower DD, Landolfo KP, Clements F, et al. 1998. Mitral valve operation via Port Access versus median sternotomy. *Eur J Cardiothorac Surg* 14 (Suppl 1):S143-7.
- Grossi EA, Groh MA, Lefrak EA, et al. 1999. Results of a prospective multicenter study on port – access coronary bypass grafting. *Ann Thorac Surg* 68:1475-7.
- Grossi EA, LaPietra A, Ribakove GH, et al. 2001. Minimally invasive versus sternotomy approaches for mitral reconstruction: comparison of intermediate-term results. *J Thorac Cardiovasc Surg* 121(4):708-13.
- Reichenspurner H, Boehm DH, Welz A, et al. 1998. Minimally invasive coronary artery bypass grafting: Port-access approach versus off-pump techniques. *Ann Thorac Surg* 66:1036-40.
- Reichenspurner H, Detter C, Deuse T, Boehm DH, Treede H, Reichart B. 2005. Video and robotic-assisted minimally invasive mitral valve surgery: A comparison of the port-access and transthoracic clamp techniques. *Ann Thorac Surg* 79:485-91.
- Schachner T, Bonaros N, Laufer G, Bonatti J. 2004. The ESTECH remote access perfusion cannula in minimally invasive cardiac surgery. *Heart Surg Forum* 7:503-6.
- Schroeyers P, Wellens F, De Geest R, et al. 2001. Minimally invasive video-assisted mitral valve repair: Short and mid-term results. *J Heart Valve Dis* 10:579-83.
- Van Nooten GJ. 2001. Multicenter experience with the remote access perfusion (RAP) catheter. *Ann Thorac Surg* 72:S1065-8.