

HOW I DO IT

Traction of Ascending Aorta with Starfish Heart Positioner During Proximal Saphenous Vein Graft Anastomosis Using the PAS-Port System in Off-Pump Coronary Artery Bypass Grafting

Satoru Nishida, MD,¹ Yujiro Kikuchi, MD,¹ Go Watanabe, MD,^{1,2} Yoshiko Shintani, MD,¹ Shigeki Ito, MD,¹ Shigeki Tabata, MD,¹ Kenji Kawachi, MD¹

¹Division of Cardiac Surgery, Tokyo Medical University, Tokyo, Japan; ²Department of General and Cardiothoracic Surgery, Kanazawa University Graduate School of Medical Science, Ishikawa, Japan

ABSTRACT

The PAS-Port system allows for the rapid deployment of a clampless proximal anastomosis between a saphenous vein graft and the aorta. We have developed a simple technique of establishing traction of the ascending aorta with the Starfish heart positioner during proximal saphenous vein anastomosis using the PAS-Port system in off-pump coronary artery bypass grafting.

INTRODUCTION

Off-pump coronary artery bypass grafting (CABG) is a safe alternative to conventional CABG using cardiopulmonary bypass. However, side clamping of the ascending aorta is recognized as a possible cause of the increased incidence of cerebral vascular accident during myocardial revascularization. To avoid side clamping of the aorta, we introduced the PAS-Port system (Cardica, Redwood City, CA, USA) as part of a less invasive surgery that we have developed since the 1990s [Watanabe 1999]. The PAS-Port system allows rapid deployment of a clampless proximal anastomosis between the greater saphenous vein (GSV) graft and the ascending aorta [Gummert 2006]. However, care must be taken to achieve accurate deployment of the PAS-Port system. The disadvantages of semiautomatic anastomotic devices are the 90° take-off angle of the GSV graft from the aorta and graft kinking. It is very important to place the anastomosis on the anterior aspect of the aortic wall when grafting the right territory and to place the anastomosis as far to the left lateral position as possible when grafting the left territory using anastomotic devices. In this report, we describe a simple method of achieving traction and exposure of the ascending aorta using the Starfish heart positioner (Medtronic, Minneapolis, MN, USA) during proximal GSV anastomosis with the PAS-Port system during off-pump CABG.

Received March 17, 2007; accepted April 24, 2007.

Correspondence: Division of Cardiac Surgery, Tokyo Medical University, 6-7-1 Nishi-shinjuku, Shinjuku-ku, Tokyo 160-0023, Japan; 81-3-3342-6111 ext 2104; fax: 81-3-3349-2950 (e-mail: snishida@k6.dion.ne.jp).

TECHNIQUE

Between September 2005 and December 2006, 51 patients underwent off-pump CABG using at least one proximal GSV graft anastomosis with the PAS-Port system at our institution. First, the GSV was harvested with the conventional open technique or less invasive harvesting technique with the SaphLITE retractor (Genzyme Biosurgery, Cambridge, MA, USA) [Greenfield 2001]. Simultaneously, the left internal thoracic artery was harvested in a pedicled fashion. Epiaortic echography was then performed to assess the aortic wall and detect an atherosclerosis-free portion before deployment of the PAS-Port system. The Starfish heart positioner was used to establish traction of the aorta and exposure of the anastomotic site. The Starfish heart positioner was attached to the ascending aorta, and the aorta was retracted laterally and superiorly. After the adventitia or connective tissue of the anastomotic site was removed, proximal anastomosis of the GSV was performed using the PAS-Port system. The aorta was retracted to the upper left using the Starfish heart positioner, and the graft directed toward the right coronary artery was proximally connected on the anterior aspect of the ascending aorta and reclined on the right atrial appendage (Figure 1). Similarly, the aorta was retracted to the upper right, and the graft directed toward the left circumflex branch was connected on the left lateral aspect of the ascending aorta and reclined on the main pulmonary artery (Figure 2). Finally, all distal anastomoses were performed in a routine fashion. Postoperative angiography demonstrated wide patency of the grafts without kinking.

DISCUSSION

The potential key advantages of using a proximal anastomotic device are to avoid manipulating the aorta and reduce procedural time. However, several critical factors must be assured, including the site of proximal anastomosis, a 90° take-off angle of the GSV graft from the ascending aorta, and the absence of graft kinking. Special attention should be paid to the correct deployment of the PAS-Port system.

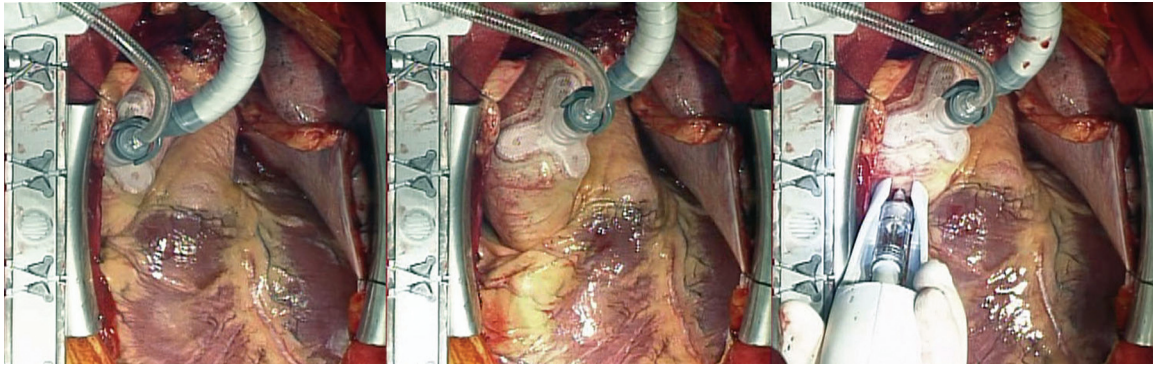


Figure 1. The Starfish heart positioner was attached to the ascending aorta (left), and the aorta was retracted to the upper left (middle). The graft directed toward the right coronary artery was proximally connected on the anterior aspect of the aorta using the PAS-Port system (right).

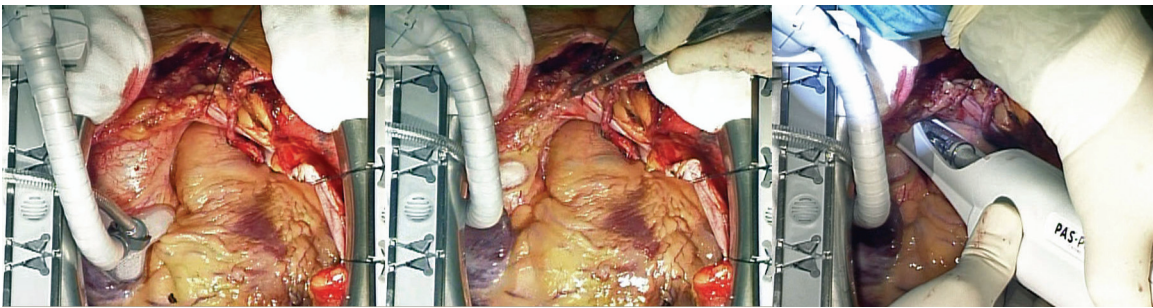


Figure 2. The Starfish heart positioner was attached to the ascending aorta (left), and the aorta was retracted to the upper right (middle). The graft directed toward the left circumflex branch was connected on the left lateral aspect of the aorta using the PAS-Port system (right).

The Starfish heart positioner is a useful instrument for the exposure of the back wall of the heart during the distal anastomosis [Grundeman 2004]. We previously reported the technique of immobilizing the ascending aorta with the Starfish heart positioner during hand-sewn proximal anastomosis [Yasuda 2006]. We modified this immobilization technique to develop the traction technique described in this report. To avoid kinking of the graft, the optimal anastomotic site is positioned on the anterior aspect of the ascending aorta adjacent to the right atrial appendage when grafting the territory of the right coronary artery, or the left lateral aspect adjacent to the main pulmonary artery when grafting the territory of the left circumflex branch. Traction of the ascending aorta using the Starfish heart positioner facilitates exposure of the anterior or lateral aspect of the aorta, and furthermore provides a motionless surgical field in the aorta. The proximal anastomosis can then be performed more safely and accurately.

Although traction obtained with tape encircled around the ascending aorta is an alternative approach to exposing the anastomotic site, it is not quicker or less invasive than the traction technique with the Starfish heart positioner that is always available during off-pump CABG. We consider that this technique of establishing traction of the ascending

aorta using the Starfish heart positioner during proximal GSV anastomosis with the PAS-Port system makes off-pump CABG less invasive and contributes to superior patency of the grafts.

REFERENCES

- Calafiore AM, Bar-El Y, Vitolla G, et al. 2001. Early clinical experience with a new sutureless anastomotic device for proximal anastomosis of the saphenous vein to the aorta. *J Thorac Cardiovasc Surg* 121:854-8.
- Greenfield GT, Whitworth WA, Tavares LL, et al. 2001. Minimally invasive vein harvest and wound healing using the SaphLITE Retractor System. *Ann Thorac Surg* 72:S1046-9.
- Grundeman PF, Verlaan CW, van Boven WJ, et al. 2004. Ninety-degree anterior cardiac displacement in off-pump coronary artery bypass grafting: the Starfish cardiac positioner preserves stroke volume and arterial pressure. *Ann Thorac Surg* 78:679-84; discussion 684-5.
- Gummert JF, Demertzis S, Matschke K, et al. 2006. Six-month angiographic follow-up of the PAS-Port II clinical trial. *Ann Thorac Surg* 81:90-6.
- Watanabe G, Takahashi M, Misaki T, et al. 1999. Beating-heart endoscopic coronary artery surgery. *Lancet* 354:2131-2.
- Yasuda T, Watanabe G, Tomita S, et al. 2006. Immobilization of ascending aorta with Starfish positioner in off-pump CABG. *Heart Surg Forum* 9:E488-9.