

Severe Isolated Tricuspid Insufficiency due to Tricuspid Papillary Muscle Rupture after a Fall From a Horse: Treatment with Port Access Minimally Invasive Cardiac Surgery

Kürsad Öz, MD,¹ Yousef Mayeran, MD,¹ Frank Van Praet, MD,¹ Jose Codens, MD,² Hugo Vanerman, MD¹

Departments of ¹Thoracic and Cardiovascular Surgery and ²Anesthesiology, O.L.V Hospital, Aalst, Belgium

ABSTRACT

We report on the successful treatment of tricuspid valve insufficiency due to blunt chest injury using port-access minimally invasive cardiac surgery. The optimal surgical treatment of traumatic valvular insufficiency is discussed, including a brief review of the relevant literature.

INTRODUCTION

Minimally invasive cardiac surgery using port access has been used successfully for both mitral and aortic valve repair; it is feasible, safe and has esthetic cosmetic results [Kypson 2002]. Using this technique blood loss is minimized and postoperative recovery time is faster, with a shorter hospital length of stay. Post traumatic tricuspid insufficiency following blunt chest trauma is a rare clinical entity, and reports of tricuspid valve repair using the port-access approach are also rare. Here we report a port-access minimally invasive tricuspid valve surgery (mini TVS) for severe traumatic tricuspid insufficiency after a fall from a horse 6 months previously. Tricuspid valvuloplasty, cleft repair and ring annuloplasty were successfully performed in the patient to restore valvular competence.

CASE PRESENTATION

A 52 year old male was referred to our hospital with increasing occurrence of palpitations, dyspnea on exertion, and fatigue for six months following a fall from a horse. Physical examination revealed hepatomegaly, distention of the jugular veins, peripheral edema and a grade 3-4/6 systolic murmur on the left lateral sternal border. The cardiothoracic index was enlarged on telecardiography. A two-dimensional

transthoracic echocardiogram showed dilatation of the right atrium and severe tricuspid regurgitation, with flail posterior leaflet due to papillary muscle rupture. Other valves were normal. Coronary angiography revealed normal coronary arteries. A mini TVS was planned. After intubation with a dual lumen endotracheal tube, a 3 cm right anterolateral thoracotomy was performed over the fourth intercostal space. The right femoral artery, femoral vein and right internal jugular vein were cannulated and cardiopulmonary bypass with moderate systemic hypothermia was initiated. Under echocardiographic guidance, an Edwards EndoClamp aortic catheter was advanced over a guide wire through the femoral artery cannula into the ascending aorta. Intermittent antegrade cold cardioplegia was infused every thirty minutes for myocardial protection. A right atriotomy was performed. The tricuspid valve annulus was found to be dilated, with a valvular cleft between the anterior and posterior leaflets and rupture of the posterior papillary muscle. A modified papillary muscle repair procedure was used to reimplant the tip of the ruptured papillary muscle (height and/or length adjusted) into a corresponding papillary muscle using a pericardium pledget-reinforced polytetrafluoroethylene suture. A ring annuloplasty (28 mm Carpentier-Edwards Physio Annuloplasty Ring), and a cleft repair were also performed (Figure). Successful repair was confirmed intraoperatively with TEE and the postoperative course was uneventful. The patient was discharged on postoperative day 6.

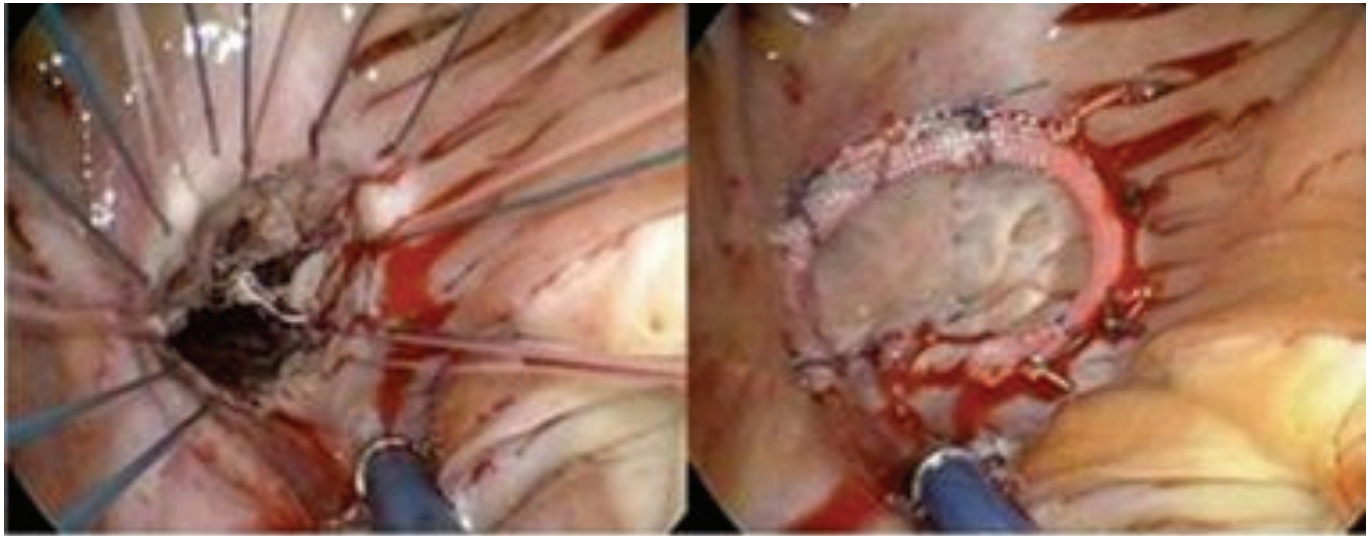
DISCUSSION

Traumatic tricuspid insufficiency is extremely rare. Papillary muscle or valve injury after blunt cardiac trauma may cause regurgitation which tends to worsen with time [Ismailov 2005]. The rate of degeneration of the valvular function appears to depend on its location [Kypson 2002]. Regurgitation of the mitral or aortic valves tends to cause symptoms immediately or within the first week after the injury, while injury to the pulmonary or tricuspid valves may be easily tolerated for a long period of time, although in some cases urgent intervention is required [Dąbrowski 2011].

The right ventricle is located behind the sternum; therefore, it is vulnerable to anteroposterior compression injuries. Valve repair should be considered in these

Received January 3, 2014; accepted April 10, 2014.

Correspondence: Kürsad Öz, MD, Mehmet Akif Ersoy Gogus ve Kalp Damar Cerrahisi Hastanesi, Istasyon M. Turgut Ozal Bulvarı, Küçükçekmece, Istanbul, Turkey, 34303; Tel:+902126922000, Fax:+902124719494 (e-mail: drkursadoz@gmail.com).



Postoperative view of papillary muscle repair procedure to reimplant the tip of the ruptured papillary muscle and tricuspid ring annuloplasty

cases as the first option to protect right ventricular function. Port-access minimally invasive mini thoracotomy is currently routinely used in cardiac surgery to avoid potential complications from median sternotomy. Reports of tricuspid valve operations using the port-access approach are rare even though the technique has been shown to be feasible and safe, with minimal blood loss, faster recovery time and superior cosmetic results [Kasahara 2010]. We chose mini tricuspid valve surgery in this case due to both our surgical experience with the technique and patient preference.

CONCLUSION

Physicians should be aware of the possibility of cardiac valve lesions following chest trauma.

In these cases port-access minimally invasive cardiac surgery should be offered to patients as an alternative and safe technique that minimizes blood loss and patient trauma and has the potential for superior cosmetic results.

REFERENCES

- Dąbrowski W, Nestorowicz A, Wośko J, et al. 2011. Tricuspid valve rupture after blunt chest trauma. *Anaesthesiol Intens Ther* 43:239-43.
- Ismailov RM, Weiss HB, Ness RB, et al. 2005. Blunt cardiac injury associated with cardiac valve insufficiency: trauma links to chronic disease? *Injury* 36:1022-8.
- Kasahara H, Kudo M, Kawajiri H, et al. 2010. Repair of traumatic tricuspid insufficiency via minimally invasive port access. *Gen Thorac Cardiovasc Surg* 58:194-6.
- Kypson AP, Glower DD. 2002. Minimally Invasive Tricuspid Operation Using Port Access. *Ann Thorac Surg* 74:43-5.