

## Single-Stage Repair of Aneurysm of the Ascending Aorta Associated with Aortic Coarctation

Saina Attaran, MD, MRCS, Jeremy Felderhoff, MRCS, Mark A. Westwood, MD, MRCP, Wael I. Awad, MD, FRCS (C/Th)

The London Chest Hospital, Barts and the London NHS Trust, London, UK

### ABSTRACT

A 38-year-old man with a history of uncontrolled hypertension was investigated for atypical chest pains and found to have an aneurysm of the ascending aorta and a coexisting coarctation of the aorta. The timing and sequence of surgical repair of these 2 pathologies are controversial. We report an elective single-stage operation in which the ascending aorta was replaced and an extracardiac bypass from the ascending to the descending aorta was performed with excellent results.

### INTRODUCTION

A 38-year-old man with a history of uncontrolled hypertension was investigated for atypical chest pains. On examination, he had a high blood pressure in the upper limbs and absent pulses in his lower limbs. A chest radiograph revealed a widened mediastinum and notching of the ribs. A computed tomography scan and magnetic resonance imaging demonstrated a 5.6-cm aneurysm of the ascending aorta and a tight coarctation measuring 8 mm distal to the origin of the left subclavian artery. The arch and the descending aorta were of normal caliber (Figure 1).

We elected to repair the aneurysm of the ascending aorta and bypass the coarctation of the aorta extra-anatomically in a single-stage procedure. The operation was performed via a median sternotomy. The large aneurysm of the ascending aorta extended to the arch. After systemic heparinization, cardiopulmonary bypass was established by cannulating the right subclavian artery, the left femoral artery, and the right atrium.

The patient's temperature was kept at 35°C for the first part of the operation. The apex of the beating heart was elevated with a Starfish stabilizer (Medtronic, Minneapolis, MN, USA) to expose the posterior pericardium, which was opened longitudinally for access to the descending aorta.

After application of a side-biting clamp, an 18-mm Gelweave tube graft (Vascutek, Inchinnan, UK) was

anastomosed to the descending aorta. The tube graft was then brought out from behind the inferior vena cava to lie alongside the right atrium.

The patient's body temperature was then reduced to 32°C, and the ascending aorta was clamped at the level of the arch. The heart was arrested with cold antegrade blood cardioplegia. The aorta was opened. The aortic valve was trileaflet, and the root was normal. The ascending aorta was then replaced with a 28-mm Vascutek tube graft in the supracoronary position.

The proximal end of the tube graft anastomosed to the descending aorta was then sutured to the right side of the ascending aorta graft (Figure 2).

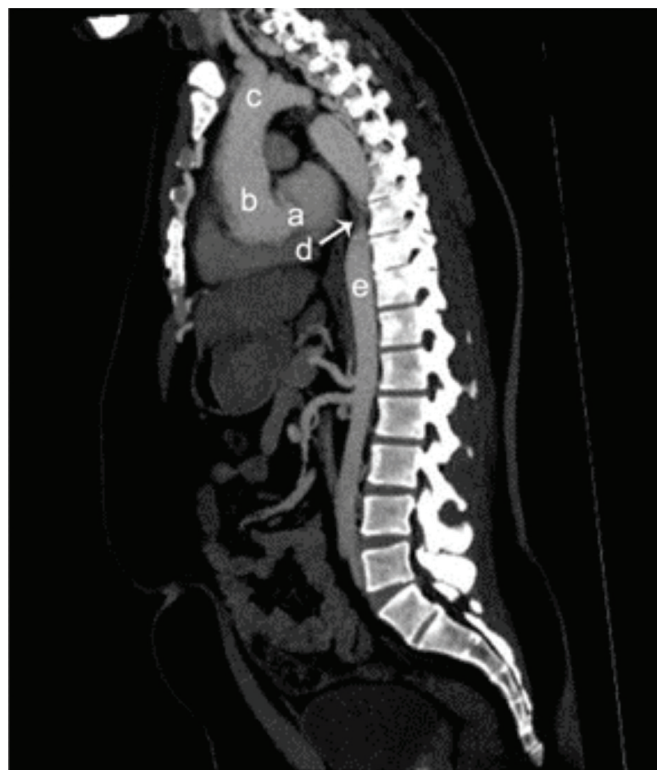


Figure 1. Preoperative sagittal magnetic resonance image of the descending thoracic aorta demonstrating the coarctation (arrow). The sinotubular junction (a), ascending aorta (b), aortic arch (c), coarctation (d), and descending aorta (e) are indicated.

Received December 6, 2009; accepted February 2, 2010.

Correspondence: Saina Attaran, Cardiothoracic Department, London Chest Hospital, Bonner Rd, London E2 9JX, UK; +44-7973435452 (e-mail: [saina.attaran@kcl.ac.uk](mailto:saina.attaran@kcl.ac.uk)).

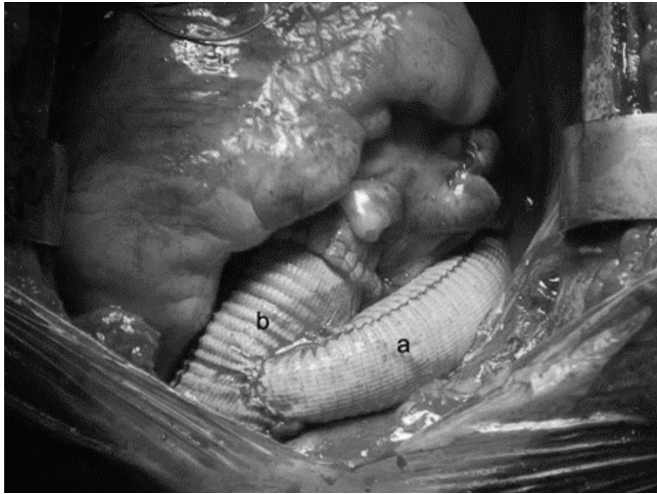


Figure 2. The proximal end of the tube graft (a) anastomosed to the descending aorta is sutured to the side of the tube graft (b) in the replaced ascending aorta.

The patient's postoperative course was uncomplicated. The patient was discharged without complications. At follow-up, he had no chest pain, and his antihypertensive medications were greatly reduced.

#### COMMENT

Coarctation of the aorta has commonly (59%-92%) been associated with other abnormalities of the aorta, such as aneurysm and dissection [Attenhofer Jost 2002]. There are different strategies to repair these 2 associated conditions. Lawson et al first described a 2-stage procedure to correct the coarctation prior to the dissected aorta to decrease the proximal hypertension and to minimize the progression of the dissection [Lawson 1979]. This strategy therefore leaves the patient at risk of rupture of the ascending aorta. The other 2-stage approach is to repair the dissection first and leave the surgery on the coarctation to the second stage [Hovaguimian 1990; Tesler 1996]. This strategy minimizes the risk of rupture but increases the risk of such complications as heart failure. A 2-stage repair requires 2 incisions and hospitalizations.

Successful single-stage repair of dissection of the ascending aorta and coarctation of the aorta was first described by Svensson et al [Svensson 1994; Bonvini 2002]. They used an extra-anatomic bypass using a tube graft to connect the ascending aortic graft with the abdominal aorta, because

suturing the graft to the descending aorta at the posterior pericardial space can be difficult. This approach leaves the patient with an extensive scar with the added complications of a laparotomy [Buket 2001; Cranfield 2008]. Therefore, a single-stage repair would be preferable.

To our knowledge, an elective single-stage repair of an ascending aortic aneurysm and coarctation in an adult patient has not been reported previously.

In our case, we cannulated the subclavian and femoral arteries to allow satisfactory perfusion of the whole body and to minimize the risk of spinal cord injury. In our case, the whole procedure was performed via a median sternotomy without the need for an extended laparotomy or a clamshell incision.

We believe that in patients with coarctation of the aorta, a careful screening of the ascending aorta should be performed and that a combined procedure be conducted to correct the coarctation and any associated pathologies. This approach minimizes postoperative complications and the hospital stay without significantly affecting the operative outcome.

#### REFERENCES

- Attenhofer Jost CH, Schaff HV, Connolly HM, et al. 2002. Spectrum of reoperations after repair of aortic coarctation: importance of an individualized approach because of coexistent cardiovascular disease. *Mayo Clin Proc* 77:646-53.
- Bonvini R, Wyttenbach R, Ghisla R, Gargiulo G, Gallino A. 2002. Images in cardiovascular medicine. Type A aortic dissection in a patient with congenital coarctation of the aorta: emergency surgical repair with an extra-anatomic bypass. *Circulation* 106:e74-5.
- Buket S, Yağdı T, Cikirikçioğlu M, Alayunt EA. 2001. Single-stage transpericardial repair of acute aortic dissection associated with recoarctation. *J Thorac Cardiovasc Surg* 121:987-9.
- Cranfield KR, Brackenburg ET, Fraser SCA. 2008. One-stage repair of an aortic dissection and aortic coarctation. *Interact Cardiovasc Thorac Surg* 7:170-2.
- Hovaguimian H, Aru GM, Floten HS. 1990. Acute type I aortic dissection with coarctation of the aorta: discussion of management and the report of a successful brain perfusion across an aortic coarctation. *J Thorac Cardiovasc Surg* 100:152-3.
- Lawson RA, Fenn A. 1979. Dissection of an aneurysmal ascending aorta in association with coarctation of the aorta. *Thorax* 34:606-11.
- Svensson LG. 1994. Management of acute aortic dissection associated with coarctation by a single operation. *Ann Thorac Surg* 58:241-3.
- Tesler UF, Tomasco B. 1996. Repair of acute dissection of the ascending aorta associated with aortic coarctation. *Tex Heart Inst J* 23:170-3.