

## Transcutaneous Axillary Artery Cannulation

Nezihi Kucukarslan, MD, Mehmet Yilmaz, MD, Mutasım Sungun, MD,  
Ahmet Turan Yilmaz, MD

Department of Cardiovascular Surgery, GATA Haydarpaşa Military Training Hospital, Istanbul, Turkey

### ABSTRACT

The axillary artery may be an alternative cannulation site for patients with diffused atherosclerosis, aortic dissection, and aneurysm. There are different techniques for axillary artery cannulation that can be performed easily with a transcutaneous approach. Small incision necessity, less dissection, and good wound healing are other advantages of this technique.

### INTRODUCTION

In many circumstances, the ascending aorta may be inappropriate for a cardiopulmonary bypass procedure, such as in the case of severe aortic atherosclerosis, ascending aortic aneurysm and dissection. The femoral artery is the most chosen arterial cannulation site in these situations [Sabik 1995]. Sometimes, diffused atherosclerosis does not make it possible. On the other hand, aortic dissection may involve femoral arteries. Due to false lumen perfusion, visceral malperfusion can occur [Strauch 2004]. Wound infections and delay in wound healing have been observed to be much more with femoral cannulation [Bichell 1997]. Therefore, axillary artery cannulation may be employed use for arterial inflow, if the ascending aorta and femoral artery are found to be inconvenient.

We present our experience with axillary artery cannulation.

### TECHNIQUE

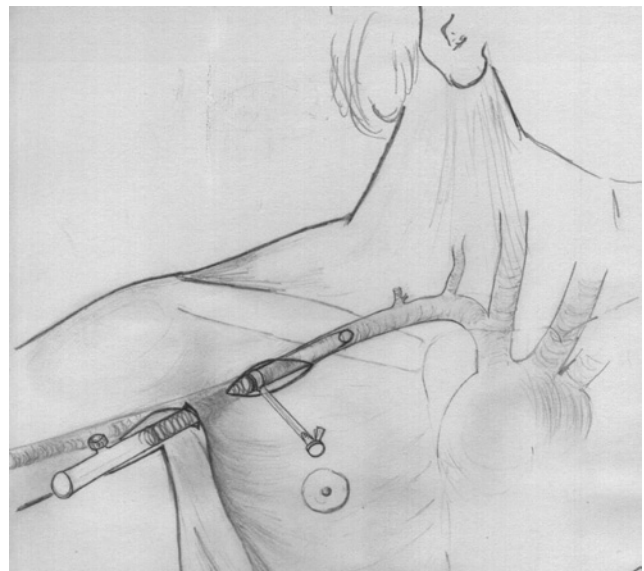
Arterial pressure monitorization is made by using the left radial artery line. The axillary artery is prepared before sternotomy. A skin incision is made below the medial third of the right clavicle, ~4 cm in length. The pectoralis major is split through the fibers. The pectoralis minor is retracted laterally to allow exposure to the axillary artery, vein, and brachial plexus cords. The axillary artery is mobilized in a gentle manner to avoid neighborhood structures. Silastic tapes are used for traction of the artery. A second small skin incision is made

below the lateral border of the first one. A guided arterial cannula is advanced through the subcutaneous tissue, from between the pectoralis major and minor fibers. By this technique, the true entrance angle is reached. After heparin administration the axillary artery is occluded and transverse arteriotomy is performed, the cannula is then advanced 2 cm into the artery (Figure). The proximal snare is tightened. The cannula is fixed by a skin stitch at the end of the second incision. After removal of the cannula, the insertion site of the cannula is used for drainage of the wound with a hemovac drain.

### COMMENT

Sabik et al in 1995 demonstrated that axillary artery cannulation is an effective and safe procedure for cardiopulmonary bypass in patients with extensive aortic and peripheral vascular disease. The risk of atheroemboli due to retrograde flow and perfusion of the false lumen have been prevented with this technique.

Risk factors increasing the frequency of axillary artery damage include large cannula size, small artery diameter, and traumatic insertion. The cannula size must be suitable for the body surface area to achieve adequate flow. Different techniques may be used to cannulate the axillary artery: direct cannulation with straight or right-angled flexible cannula,



Axillary Artery Cannulation Technique.

Received December 30, 2004; accepted February 3, 2005.

Address correspondence and reprint requests to: Nezihi Kucukarslan, MD, GATA Haydarpaşa Eğitim Hastanesi, Kardiyovasküler Cerrahi Servisi, Selimiye Mab, Tibbiye Cad, 34670 Kadıköy, Istanbul, Turkey; 00-90-(216) 542-2675; fax: 00-90-(216) 348-7880 (e-mail: [nkucukarslan@gata.edu.tr](mailto:nkucukarslan@gata.edu.tr)).

and cannulation of the axillary artery with a side graft [Baribeau 1998, Strauch 2004].

The axillary artery is localized deeply in this region. Direct cannulation of the axillary artery may be hazardous. During the cannulation, the angle of entrance of the cannula into the artery is important. The position of the tip of the cannula and the pressure to which the arterial wall is exposed, determines the insertion angle. During the maneuver, the tip of the cannula may destroy the arterial wall; intimal tear or complete rupture of the artery can occur. In achieving an appropriate entrance angle of the cannula with this technique, procedure-related complications are decreased. The other advantages of this technique lie in its being carried out with a small incision and less dissection, as well as subsequent good heading of the wound.

## REFERENCES

- Baribeau YR, Westbrook BM, Charlesworth DC, Maloney CT. 1998. Arterial inflow via an axillary artery graft for the severely atheromatous aorta. *Ann Thorac Surg* 66(1):33-7.
- Bichell DP, Balaguer JM, Aranki SF, et al. 1997. Axilloaxillary cardiopulmonary bypass: a practical alternative to femorofemoral bypass. *Ann Thorac Surg* 64(3):702-5.
- Sabik JF, Lytle BW, McCarthy PM, Cosgrove DM. 1995. Axillary artery: an alternative site of arterial cannulation for patients with extensive aortic and peripheral vascular disease. *Thorac Cardiovasc Surg* 109(5):885-90.
- Strauch JT, Spielvogel D, Lauten A, et al. 2004. Axillary artery cannulation: routine use in ascending aorta and aortic arch replacement. *Ann Thorac Surg* 78(1):103-8.