

High-Volume Hemofiltration as Adjuvant Therapy for Refractory Shock after Pericardiocentesis

Romuald Lango,¹ Maciej M. Kowalik,¹ Piotr Siondalski,² Jan Rogowski,²
Alicja Dabrowska-Kugacka³

Departments of ¹Cardiac Anesthesiology, ²Cardiac and Vascular Surgery, and ³Second Department of Cardiology, Medical University of Gdansk, Gdansk, Poland



Dr. Lango

ABSTRACT

Background: Pericardiocentesis for the treatment of chronic cardiac tamponade can occasionally result in acute pulmonary edema or biventricular failure. A sudden increase in heart filling pressures and right-to-left ventricular-output mismatch have been proposed underlying mechanisms.

Case Report: We report the case of 16-year-old patient who underwent pericardiocentesis for chronic cardiac tamponade 6 weeks after undergoing a Bentall procedure. The patient developed circulatory shock 6 hours after pericardiocentesis. High-volume hemofiltration was used as a rescue therapy after treatment with positive inotropic drugs proved ineffective. An improvement in circulatory function observed after commencement of the hemofiltration treatment was followed by hemodynamic deterioration when the hemofiltration procedure was ceased.

Discussion: The mechanism of the observed hemodynamic improvement is unclear. Hemodynamic recovery related in time to high-volume hemofiltration treatment indicates the possible removal of inflammatory mediators. Visceral vasoconstriction resulting from cardiac tamponade and subsequent improvement in gut perfusion after pericardiocentesis that led to washout of inflammatory mediators might have contributed to the development of acute heart failure. Cytokine removal by high-volume hemofiltration and the procedure's relationship to hemodynamic improvement have previously been demonstrated in clinical and experimental studies of septic shock.

Conclusions: We conclude that high-volume hemofiltration can be helpful as an adjuvant treatment for refractory shock after pericardiocentesis for chronic cardiac tamponade. The mechanism of the observed hemodynamic improvement remains to be investigated.

INTRODUCTION

In patients with chronic cardiac tamponade, sudden reduction of the intrapericardial volume after pericardiocentesis occasionally results in pulmonary edema or biventricular failure [Ligero 2006].

An abrupt increase in the preload of both ventricles causing an acute increase in the transmural pressure has been proposed as a mechanism leading to the development of acute heart failure [Wolfe 1993]. A thin-walled right ventricle is more compliant; therefore, it should compensate for a sudden preload increase, in contrast to the left ventricle. The difference in end-diastolic pressure can lead to a shift of the interventricular septum and a mismatch of the right and left ventricular outputs, which occurs in the setting of an increased left ventricular afterload caused by an increased catecholamine level [Downey 1991]. A decrease in coronary perfusion, which can cause transient global left ventricular hypokinesia and regional wall motion abnormalities, and an imbalance between sympathetic and parasympathetic stimulation were also listed among possible factors contributing to acute heart failure after pericardiocentesis [Wolfe 1993].

Given that none of the theories presented in the literature elucidate comprehensively the mechanism of acute heart failure after pericardiocentesis, a role may be played by other factors, which, together with previously described mechanisms, could contribute to a compound pathophysiology of this complication.

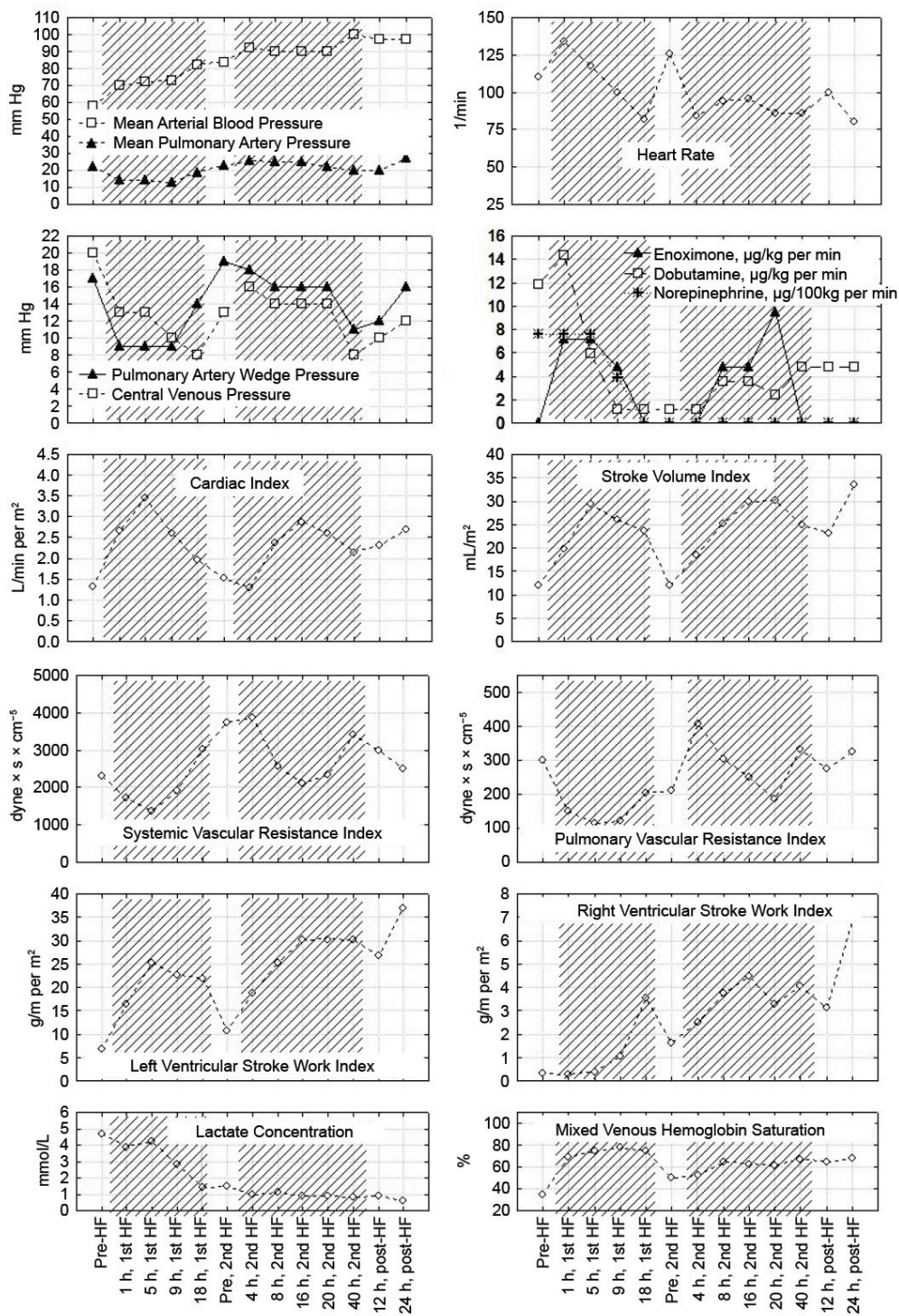
Circulatory support with inotropes and vasopressors, the administration of diuretics, and mechanical ventilation, which have proved effective in most patients [Shenoy 1984; Bernal 2007], do not ensure a patient's recovery, and fatal cases have been reported after conventional treatment [Karamichalis 2009].

CASE REPORT

A 16-year-old boy with Marfan syndrome was presented to the department of cardiac surgery with symptoms of cardiac tamponade 6 weeks after undergoing a Bentall procedure. A transthoracic echocardiography examination demonstrated 4.5-cm layer of pericardial fluid that caused right ventricular compression, whereas left ventricular contractility

Received February 19, 2011; accepted March 28, 2011.

Correspondence: Romuald Lango, Department of Cardiac Anesthesiology, Medical University of Gdansk, Debinki 7, 80-516, Gdansk, Poland (e-mail: rlango@gumed.edu.pl).



Parameters of hemodynamic function, mixed venous hemoglobin saturation, lactate concentration, and doses of inotropic drugs during treatment of acute heart failure. The times of the first hemofiltration (1st HF) and second hemofiltration (2nd HF) procedures are represented by the diagonally hatched areas.

was good. Before induction of anesthesia for pericardiocentesis, the patient presented with atrial fibrillation. His heart rate and arterial blood pressure were 125 beats/min and 120/60 mm Hg, respectively, without inotropic and

vasopressor treatment. A pericardial drainage procedure evacuated 1800 mL of hemolyzed blood, and an additional 660 mL was drained the following day. After pericardiocentesis, the atrial fibrillation converted spontaneously to a sinus

rhythm. The patient was extubated 1 hour after pericardiocentesis in an apparently stable hemodynamic condition.

The patient's circulatory function began to deteriorate 5 hours after the procedure, when his arterial blood pressure decreased to 50/30 mm Hg. The patient was set on mechanical ventilation, which produced good pulmonary gas exchange, with a ratio of the P_{aO_2} to the fraction of inspired O_2 of 357 mm Hg. To recover an adequate blood pressure, we infused dobutamine and norepinephrine into the patient. A transthoracic echocardiography evaluation demonstrated no pericardial effusion. Both ventricles were dilated, however, and the left ventricular ejection fraction decreased to 15%. The central venous pressure was 17 mm Hg.

Measurement of the thermodilution cardiac output demonstrated the function of both ventricles to be severely depressed. Parameters of hemodynamic function, the mixed venous hemoglobin oxygen saturation, the lactate concentration, and the doses of inotropic drugs used during the patient's treatment in the intensive care unit are presented in the Figure.

In response to the poor hemodynamic parameters upon first calculating the cardiac output, we increased the dobutamine and norepinephrine dosages and started an enoximone infusion. When the patient's condition did not improve (a response confirmed by a lactate concentration of 5.9 mmol/L, a cardiac index of 1.4 L/min per m^2 , and a mixed venous oxygen saturation of 35%), we commenced high-volume hemofiltration with a polyethersulfone filter (cutoff, 30,000 Da) at 23 hours after pericardiocentesis. The flow rate of the substitution fluid was set at 54 mL/kg per hour in the first 7 hours and was decreased to 36 mL/kg per hour in the subsequent 11 hours. The volume balance of hemofiltration was set to -40 mL/hour for the initial 5 hours and was changed to -10 mL/hour thereafter. After 4 hours of hemofiltration, the patient's urine output decreased to <20 mL/hour, but it recovered by 7 hours to >3 mL/kg per hour in response to furosemide administration. A remarkable hemodynamic improvement was observed, which allowed the patient to be almost completely weaned from catecholamine treatment before 18 hours of hemofiltration, when it was finished because of hemofilter clotting. The patient was extubated 26 hours after the end of the first hemofiltration procedure; however, the patient's hemodynamic parameters deteriorated the next day. Hemofiltration was reinstated 30 hours after the end of the first hemofiltration procedure, and this second procedure coincided in time to a further recovery in the patient's hemodynamic performance. The second hemofiltration procedure was ceased after 40 hours. The patient was discharged from the intensive care department in good clinical condition on day 12.

DISCUSSION

The most interesting observation was that the acute biventricular failure, which was refractory to standard treatment with dobutamine, norepinephrine, and enoximone, began to improve after commencement of high-volume hemofiltration therapy. The function of both ventricles regressed when

hemofiltration was withheld, indicating that the high-volume hemofiltration treatment was contributing to the observed hemodynamic recovery. The improvement in heart function and an increase in systemic vascular resistance (which allowed reduction of the norepinephrine dosage) that occurred during the first hemofiltration procedure suggest an important role of either circulating cytokines or other humoral factors that could be removed by hemofiltration.

Because the patient's shock in this case proved refractory to conventional treatment and because his hemodynamic status was deteriorating toward irreversibility, we decided to use high-volume hemofiltration as a rescue therapy. Investigators have previously recommended that extracorporeal blood-purification techniques be considered as a supplementary treatment for patients with refractory septic shock [Bellomo 2005; Cornejo 2006]. Hemodynamic improvement during high-volume hemofiltration has also been reported for patients with refractory nonseptic shock [Lango 2009].

In addition to previously proposed mechanisms of acute heart failure following pericardiocentesis, myocardial depression caused by circulating inflammatory mediators may also be a contributor. The splanchnic circulation could represent a possible source of inflammatory mediators after pericardiocentesis. Decreased cardiac output in a patient with tamponade leads to an increase in sympathetic stimulation and angiotensin release. Both factors are known to cause gut hypoperfusion, which can lead to cytokine release, thereby exerting potent negative inotropic effects. In turn, the sudden recovery of adequate ventricular filling after pericardiocentesis can restore adequate cardiac output and improve the perfusion of the previously hypoperfused gut [Magnotti 1998]. Therefore, gut hypoperfusion followed by restoration of adequate perfusion may represent an important factor leading to acute heart failure. Although cytokine concentrations were not measured in this patient, the concept of high levels of circulating cytokines is supported by the observation of a normal systemic vascular resistance despite high-dose norepinephrine treatment before the commencement of hemofiltration. The patient's hemodynamic profile indicates that his circulatory status began to improve after the beginning of high-volume hemofiltration. The effective removal of inflammatory mediators during hemofiltration and its relationship to hemodynamic improvement were previously demonstrated in a study of experimental and clinical sepsis [Bellomo 2005].

We conclude that high-volume hemofiltration may be helpful as an adjuvant therapy for refractory shock in patients with chronic tamponade treated with pericardiocentesis, if other treatment methods do not result in a rapid recovery of adequate cardiovascular function. The mechanism of the hemodynamic recovery we observed remains to be investigated.

REFERENCES

- Bellomo R, Honore P, Matson J, Ronco C, Winchester J. 2005. Extracorporeal blood treatment (EBT) methods in SIRS/sepsis. *Int J Artif Organs* 28:450-8.
- Bernal JM, Pradhan J, Li T, Tchokonte R, Afonso L. 2007. Acute pulmonary edema following pericardiocentesis for cardiac tamponade. *Can*

J Cardiol 23:1155-6.

Cornejo R, Downey P, Castro R, et al. 2006. High-volume hemofiltration as salvage therapy in severe hyperdynamic septic shock. *Intensive Care Med* 32:713-22.

Downey RJ, Bessler M, Weissman C. 1991. Acute pulmonary edema following pericardiocentesis for chronic cardiac tamponade secondary to trauma. *Crit Care Med* 19:1323-5.

Karamichalis JM, Gursky A, Valaulikar G, Pate JW, Weiman DS. 2009. Acute pulmonary edema after pericardial drainage for cardiac tamponade. *Ann Thorac Surg* 88:675-7.

Lango R, Kowalik MM, Klajbor K, Pawlaczyk R, Musiał-wi tkiewicz V, Rogowski J. 2009. High-volume hemofiltration as rescue therapy for

refractory shock after inadvertent rapid aprotinin administration. *J Cardiothorac Vasc Anesth* 23:526-8.

Ligero C, Leta R, Bayes-Genis A. 2006. Transient biventricular dysfunction following pericardiocentesis. *Eur J Heart Fail* 8:102-4.

Magnotti LJ, Upperman JS, Xu DZ, Lu Q, Deith EA. 1998. Gut-derived mesenteric lymph but not portal blood increases endothelial cell permeability and promotes lung injury after hemorrhagic shock. *Ann Surg* 228:518-27.

Shenoy MM, Dhar S, Gittin R, Sinha AK, Sabado M. 1984. Pulmonary edema following pericardiectomy for cardiac tamponade. *Chest* 86:647-8.

Wolfe MW, Edelman ER. 1993. Transient systolic dysfunction after relief of cardiac tamponade. *Ann Intern Med* 119:42-4.