

## A Nodular Melanoma Mimicking a Blue Nevus: A Case Report

Giovanni Marco D'Agostino<sup>1</sup>, Tommaso Bianchelli<sup>1</sup>, Giulia Veronesi<sup>1</sup>,  
Valentina Di Gregorio<sup>1</sup>, Donatella Brancorsini<sup>2</sup>

1 Dermatology Unit, Istituto Nazionale di Riposo e Cura per Anziani, INRCA-IRCCS Hospital, Ancona, Italy

2 Institute of Pathological Anatomy and Histopathology, Polytechnic University of the Marche Region, Ancona, Italy

**Citation:** D'Agostino GM, Bianchelli T, Veronesi G, Di Gregorio V, Brancorsini D. A Nodular Melanoma Mimicking a Blue Nevus a Case Report. *Dermatol Pract Concept*. 2024;14(2):e2024116. DOI: <https://doi.org/10.5826/dpc.1402a116>

**Accepted:** December 10, 2023; **Published:** April 2024

**Copyright:** ©2024 D'Agostino et al. This is an open-access article distributed under the terms of the Creative Commons Attribution-NonCommercial License (BY-NC-4.0), <https://creativecommons.org/licenses/by-nc/4.0/>, which permits unrestricted noncommercial use, distribution, and reproduction in any medium, provided the original authors and source are credited.

**Funding:** None.

**Competing Interests:** None.

**Authorship:** All authors have contributed significantly to this publication. G.M. D'Agostino and T. Bianchelli equally contributed to the manuscript.

**Corresponding Author:** D'Agostino Giovanni Marco, MD, Dermatological Unit, INRCA Ancona, Via della Montagnola 81, 60127, Ancona, Italy. Email: [giovannimarcodagostino@gmail.com](mailto:giovannimarcodagostino@gmail.com)

### Case Presentation

A 77-year-old female presented to our clinic for a routine consultation.

The examination showed at the right temporal region of the scalp a nodular lesion reported as having been present for many years and clinically described as a blue nevus but recently enlarged in volume. The lesion was excised, dermoscopy showed aspects compatible with a blue nevus (Figure 1).

The diagnosis was nodular melanoma with Breslow of 4 mm. Both sentinel lymph node and total body computed tomography (TBCT) were negative, and the patient is in six-month clinical and instrumental follow-up.

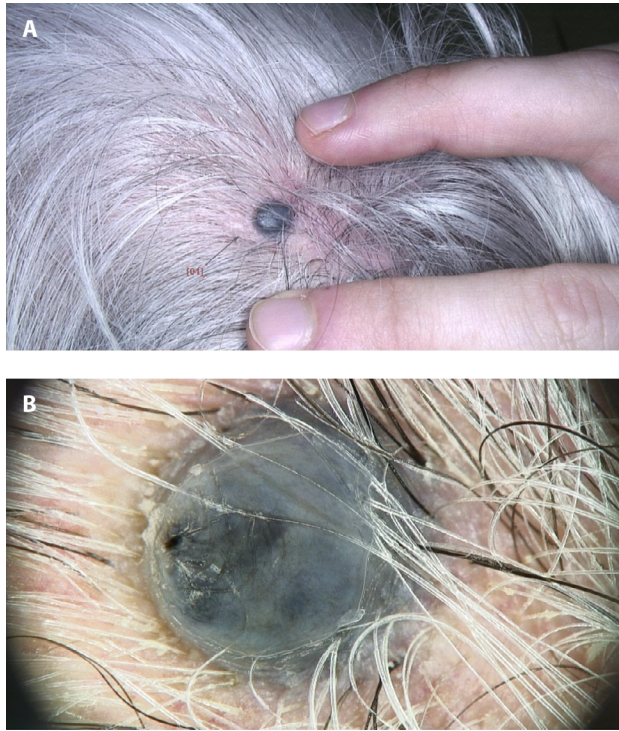
### Teaching Point

Blue nevus is a benign melanocytic lesion that rarely undergoes malignant changes.

Melanoma rarely originates on blue nevi, and many of the reported cases are cellular blue nevi with lymph nodes containing nevi cells.

There is no consensus about which prognostic indicators predictive of outcome in conventional malignant melanoma are applicable to blue nevus-like melanoma/blue nevus-associated melanoma, and the biological behavior of these lesions is not always predictable.

It is critical to focus on the story of rapid size increase even of lesions with reassuring clinical and dermoscopic aspects.



**Figure 1.** A) Clinical and B) dermoscopic image of the lesion.

## References

1. Longo C, Scope A, Lallas A, Zalaudek I, Moscarella E, Gardini S, Argenziano G, Pellacani G. Blue lesions. *Dermatol Clin.* 2013 Oct;31(4):637-47,ix. doi: 10.1016/j.det.2013.07.001. Epub 2013 Aug 23. PMID: 24075551.
2. Borgenvik TL, Karlsvik TM, Ray S, Fawzy M, James N. Blue nevus-like and blue nevus-associated melanoma: a comprehensive review of the literature. *ANZ J Surg.* 2017 May;87(5): 345-349. doi: 10.1111/ans.13946. Epub 2017 Mar 20. PMID: 28318130.