
Case Report

A Difficult Case to Diagnose: Machado-Joseph Disease/Spinocerebellar Ataxia Type III

Muhammad Sohail Ajmal Ghoauri, Nauman Ismat Butt, Dur-e-Sabeh, Muhammad Bilal Rasheed,
Muhammad Umair Javed, Fahmina Ashfaq

Summary

Machado-Joseph Disease, also known as Spinocerebellar Ataxia Type III, was initially described in patients of Azorean heritage as a neurodegenerative disease but is now known to occur globally. The main clinical involvement is cerebellar and brainstem dysfunction causing progressive ataxia and usually disease onset is in young-adult to mid-adult years. A 20-year old female presented with a 3-year history of gradual onset, progressively worsening gait abnormality and tremor of the right hand. On examination, she had gargoyle-like facial features and pes cavus. On neurologic examination, she had dystonic tremor of right hand, cerebellar ataxia, dysdiadokokinesia, abnormal heel-shin coordination, hyperreflexia with down going plantar reflex bilaterally. Her MRI scan brain revealed communicating hydrocephalus with cerebellar atrophy. She was diagnosed with Machado-Joseph Disease/Spinocerebellar Ataxia type III.

Keywords: Machado-Joseph Disease, Spinocerebellar Ataxia Type III, Neurodegeneration, Ataxia.

INTRODUCTION

Machado-Joseph Disease, also known as Spinocerebellar Ataxia Type III, was initially described in patients of Azorean heritage as a neurodegenerative disease but is now known to occur globally.¹ This ataxia is a progressive disease and there is wide variance of clinical manifestations in affected individuals even within a family. The cause of this clinical heterogeneity is an unstable Cytosine-Adenine-Guanine (CAG) trinucleotide repeat which is the basis of this disease.² This CAG trinucleotide repeat encodes an expanded tract of the amino acid glutamine in the disease protein named Ataxin-III leading to protein misfolding.³ The main clinical involvement is cerebellar and brainstem dysfunction causing progressive ataxia

and usually disease onset is in young adult to mid adult years.⁴ However, ataxia may not occur in isolation and there may be involvement of pyramidal and extrapyramidal tracts, oculomotor system, lower motor neurons and peripheral nerves leading to nystagmus, impaired eye movements, speech and vestibular difficulties.⁴ In advanced stages, the patient may become disabled and wheelchair bound. Higher mental functions generally remain intact and dementia is rarely seen.

CASE PRESENTATION

We report the case of a 20-year-old previously healthy female who presented at Bahawal Victoria Hospital, Bahawalpur, Pak with a 3-year history of gradual onset, progressively worsening gait abnormality and tremor of the right hand. On examination, she had gargoyle-like facial features and pes cavus. On neurologic examination, she had dystonic tremor of right hand, cerebellar ataxia, dysdiadokokinesia, abnormal heel shin coordination, hyperreflexia with down going plantar reflex bilaterally. All sensory sensations were intact bilaterally. There was no deficit in higher mental functions or cranial nerves. Precordial, respiratory and the abdominal examinations were unremarkable. Due to the tremor of right hand, she had learnt to use left arm predominantly and was able to do her routine and household activities without assistance. She was unmarried and did not use illicit drugs. There was no family history of neurologic disorders.

Dr. Muhammad Sohail Ajmal Ghoauri,¹ MBBS
Post-graduate Resident

Dr. Nauman Ismat Butt,² MBBS, FCPS
Assistant Professor

Dr. Dur-e-Sabeh,³ MBBS
Post-graduate Resident

Dr. Muhammad Bilal Rasheed,⁴ MBBS
House Physician

Dr. Muhammad Umair Javed,⁵ MBBS
Post-graduate Resident

Dr. Fahmina Ashfaq,⁶ MBBS, MRCP, FCPS
Consultant Physician

^{1,3,4} Bahawal Victoria Hospital, Quaid-e-Azam Medical College, BHV, Pak

^{2,4} Azra Naheed Medical College, LHR, Pak

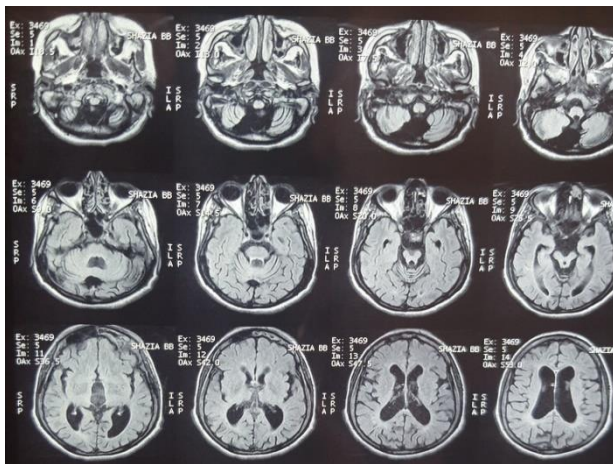
⁶ Allama Iqbal Medical College, LHR, Pak

Correspondence

Dr. Nauman Ismat Butt
nauman_ib@yahoo.com

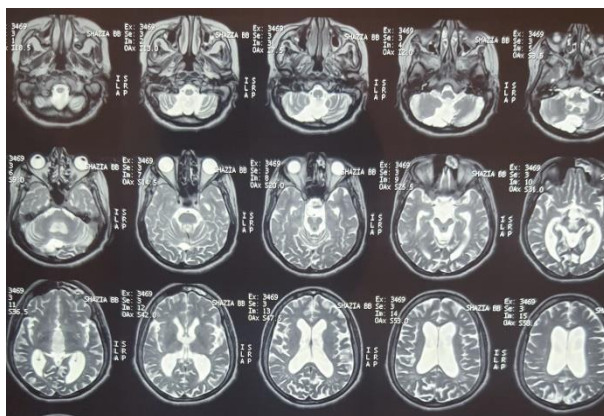
On investigation, her initial work up comprising CBC, LFTs, RFTs, TSH, urine analysis and Serum B12 levels. Serologies for HBV, HCV, HIV and Syphilis were negative. Her MRI scan brain revealed communicating hydrocephalus with cerebellar atrophy as shown in Figures 1 & 2.

Figure 1: MRI Scan Brain with FLAIR



Her echocardiography and abdominopelvic ultrasound were within normal parameters. Based on her clinical findings and MRI scan she was diagnosed with Machado-Joseph Disease/ Spinocerebellar Ataxia type III. Genetic testing for spinocerebellar ataxia could not be done due to financial constraints.

Figure 2: MRI Scan Brain T2-weighted images



DISCUSSION

Ataxia represents impairment of balance and coordination affecting gait, posture and speech usually resulting from diseases of cerebellum (cerebellar ataxia) or sensory pathways (sensory ataxia).⁵ It may be caused by alcohol, antiepileptic drugs, cerebellar stroke, paraneoplastic syndromes, multiple sclerosis, infectious such as HIV or

cerebellar abscess and rarely genetic neurodegenerative disorders.⁵ Features of neurodegeneration in Spinocerebellar Ataxia Type III are variable and widespread involving cerebellum, basal ganglia and various brainstem nuclei.⁶ Neuronal loss and brain atrophy may be seen in cerebellar peduncles, cerebellar dentate nucleus, spinocerebellar tracts, vestibular nuclei, anterior horn cells and posterior column along with globus pallidus, thalamic and subthalamic nuclei, substantia nigra, red nucleus, medial longitudinal fasciculus, pontine nuclei and cranial nerve nuclei.^{5,6} Machado-Joseph disease usually does not affect cerebral cortex, olivary nuclei and corticospinal tracts.⁶ Machado-Joseph Disease is progressive and there is currently no definitive cure.⁷ Trials are underway to see role of Riluzole and troriluzole in management of Spinocerebellar Ataxia type III.⁸ It is important to provide symptomatic therapy depending on the patients' presentation and clinical features through physiotherapy, speech therapy and occupational rehabilitation.

CONCLUSION

Machado Joseph Disease/ Spinocerebellar Ataxia Type III is a rare neurodegenerative disease that presents as progressive ataxia and the mainstay of treatment is symptomatic therapy currently.

Conflict of Interest: None.

Consent: Detailed informed consent was taken from the patient

Funding source: None.

REFERENCES

1. Paulson H. Machado-Joseph disease/spinocerebellar ataxia type 3. *Handb Clin Neurol.* 2012;103: 4374-4379. doi:10.1016/B978-0-444-51892-7.00027-9.
2. Raj K, Akundi RS. Mutant Ataxin-3-Containing Aggregates (MATAGGs) in Spinocerebellar Ataxia Type 3: Dynamics of the Disorder. *Mol Neurobiol.* 2021;58(7):3095-3118. doi:10.1007/s12035-021-02314-z.
3. Bichelmeier U, Schmidt T, Hübener J, Boy J, Rüttiger L, Häbig K, et al. Nuclear localization of ataxin-3 is required for the manifestation of symptoms in SCA3: in vivo evidence. *J Neurosci.* 2007;27(28):7418-7428. doi:10.1523/JNEUROSCI.4540-06.2007.
4. Boy J, Schmidt T, Wolburg H, Mack A, Nuber S, Böttcher M, et al. Reversibility of symptoms in a conditional mouse model of spinocerebellar ataxia type 3. *Hum Mol Genet.* 2009;18(22):4282-4295. doi: 10.1093/hmg/ddp381.
5. Dulski J, Al-Shaikh RH, Sulek A, Kasprzak J, Stawek J, Wszolek ZK. Spinocerebellar ataxia type 3 (Machado-Joseph disease). *Pol Arch Intern Med.* 2022;132(10):16322. doi: 10.20452/pamw.16322.

6. Matos CA, De Almeida LP, Nóbrega C. Machado-Joseph disease /spinocerebellar ataxia type 3: lessons from disease pathogenesis and clues into therapy. *J Neurochem.* 2019;148 (1):8-28. doi:10.1111/jnc.14541.
7. Koeppen AH. The Neuropathology of Spinocerebellar Ataxia Type 3/Machado-Joseph Disease. *Adv Exp Med Biol.*2018;1049:233-241. doi: 10.1007/978-3-319-71779-1_11.
8. Klockgether T, Mariotti C, Paulson HL. Spinocerebellar ataxia. *Nat Rev Dis Primers.* 2019;5(1):24. doi: 10.1038/s41572-019-0074-3.

Author's Contribution

**Dr. Muhammad Sohail Ajmal
Ghoauri,
Dr. Dur-e-Sabeh &
Dr. Muhammad Umair Javed**

Found the case at Bahawal Victoria Hospital, Bahawalpur, compile all data concerning case and manuscript writing. Revised and approved the articles.

**Dr. Nauman Ismat Butt, Dr.
Dr. Muhammad Bilal Rasheed
& Dr. Fahmina Ashfaq**

Concept, reviewed the content provided and then write up of manuscript, Revising manuscript critically for important intellectual content and approved it

All authors are responsible for the integrity & accuracy of the case report.

**Data availability statement:* All the data is provided in this manuscript

Date of Submission: 18-06-2023
Revised date: 01-11-2023
Accepted date: 04-12-2023